

# The Medial Knee with a Focus on the Pes Anserinus



Brian Curtis, M.D.

# Goals and Objectives

- Medial knee anatomy and pathology
  - Three layer concept developed by Warren and Marshall
  - Pes anserinus tendons
  - Bursae (pes anserinus, semimembranosus, MCL) and other cystic lesions
  - Medial knee trauma of valgus stabilizers
  - Medial hamstring autografts in ACL reconstruction
  - Nerves (saphenous nerve and its branches)



# Pes anserinus and medial knee anatomy

- 3 Layers:

- 1: Crural fascia envelops sartorius

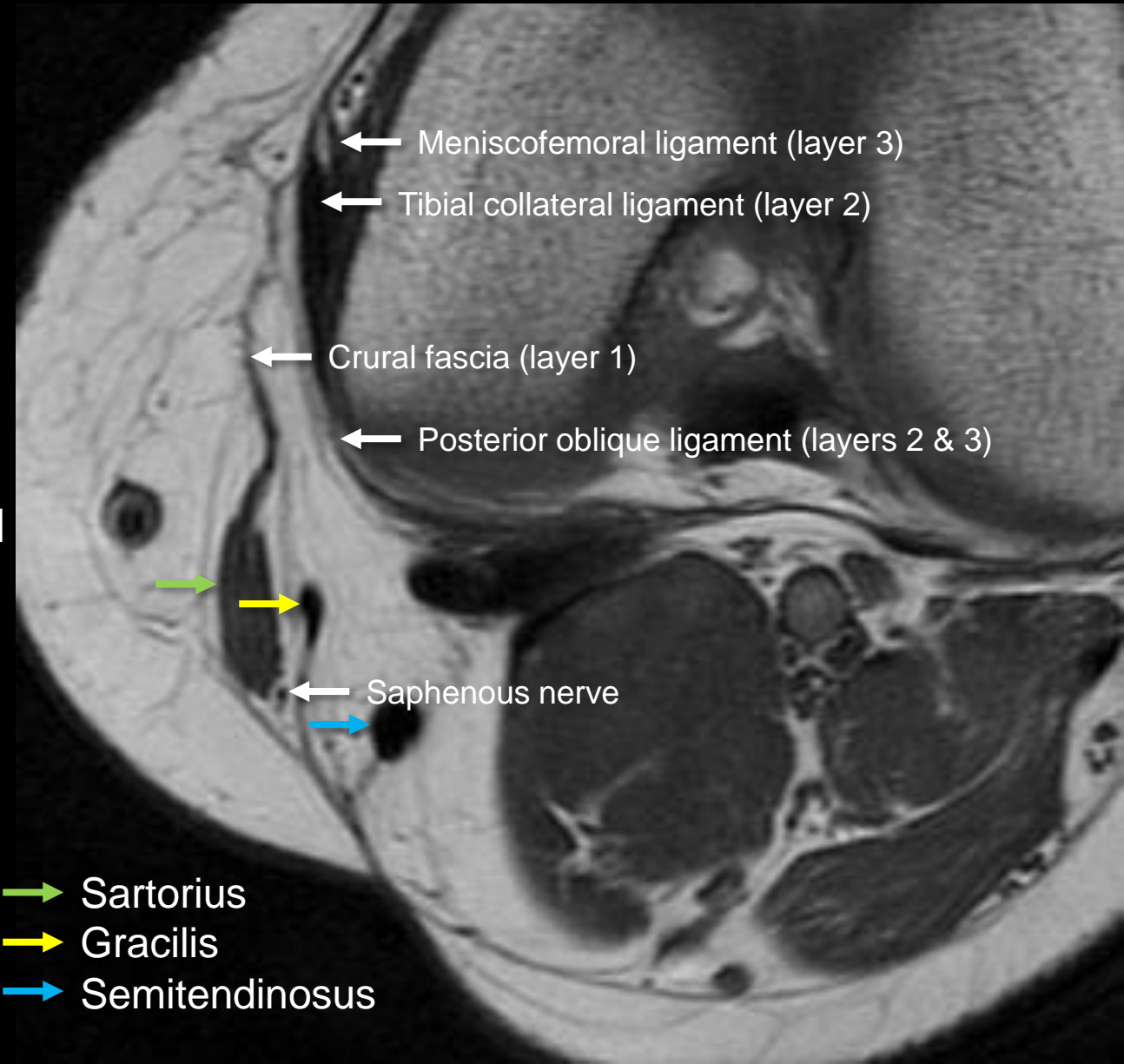
- Blends with layer 2 to form medial patellar retinaculum

- 2: Tibial collateral ligament

- Gracilis and semitendinosus are located between layers 1 and 2, and the pes anserinus bursa is interposed between the pes anserinus and tibial collateral ligament

- 3: Joint capsule, meniscotibial and meniscofemoral ligaments

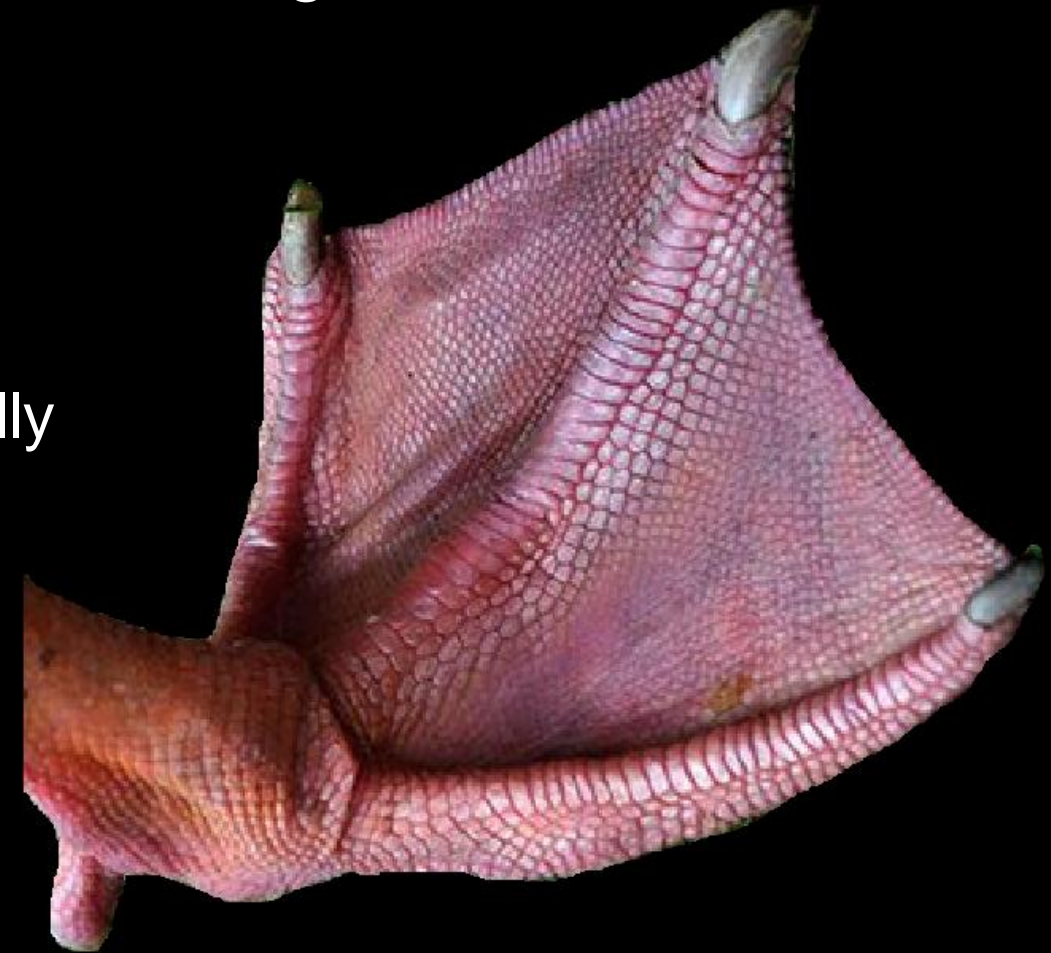- Blends with layer 2 to form the posterior oblique ligament



- Sartorius
- Gracilis
- Semitendinosus

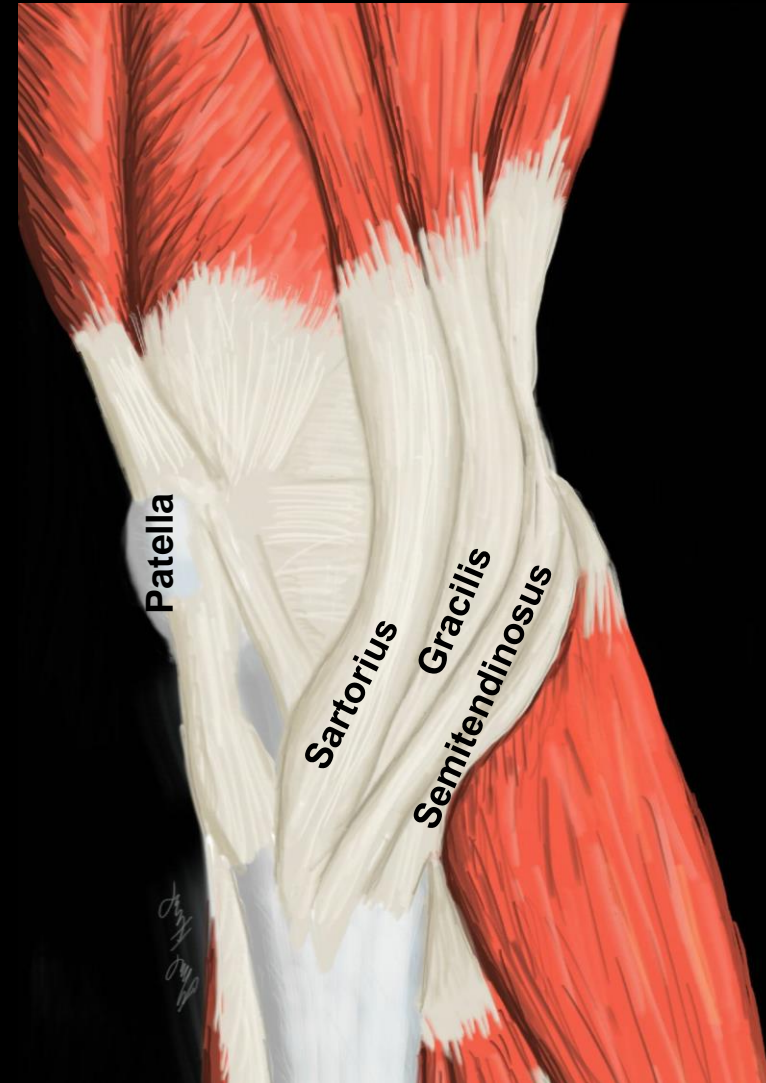
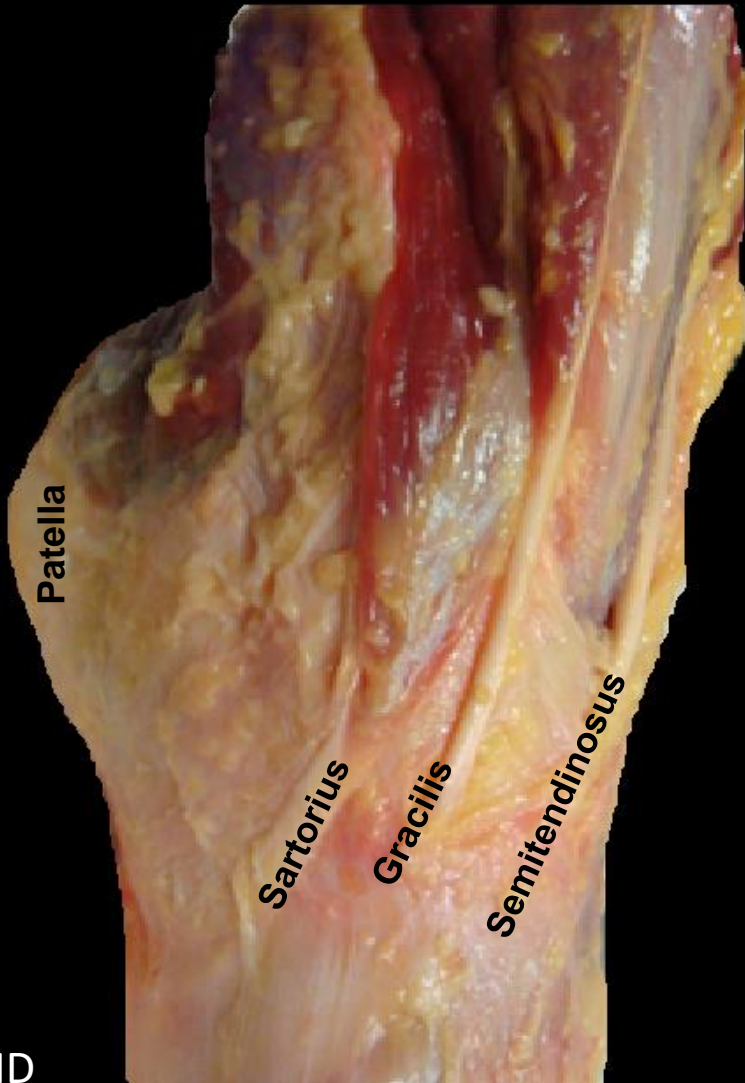
# Pes anserinus: Anatomy

- Latin for “goose foot”
- Combined tendinous insertion of the sartorius, gracilis, and semitendinosus.
- Attaches to the proximal medial tibia
  - 42 mm +/- 7 mm below tibial plateau
  - Distal and medial to tibial tuberosity
  - On MRI, pes insertion may be only partially included or be at the edge of the FOV



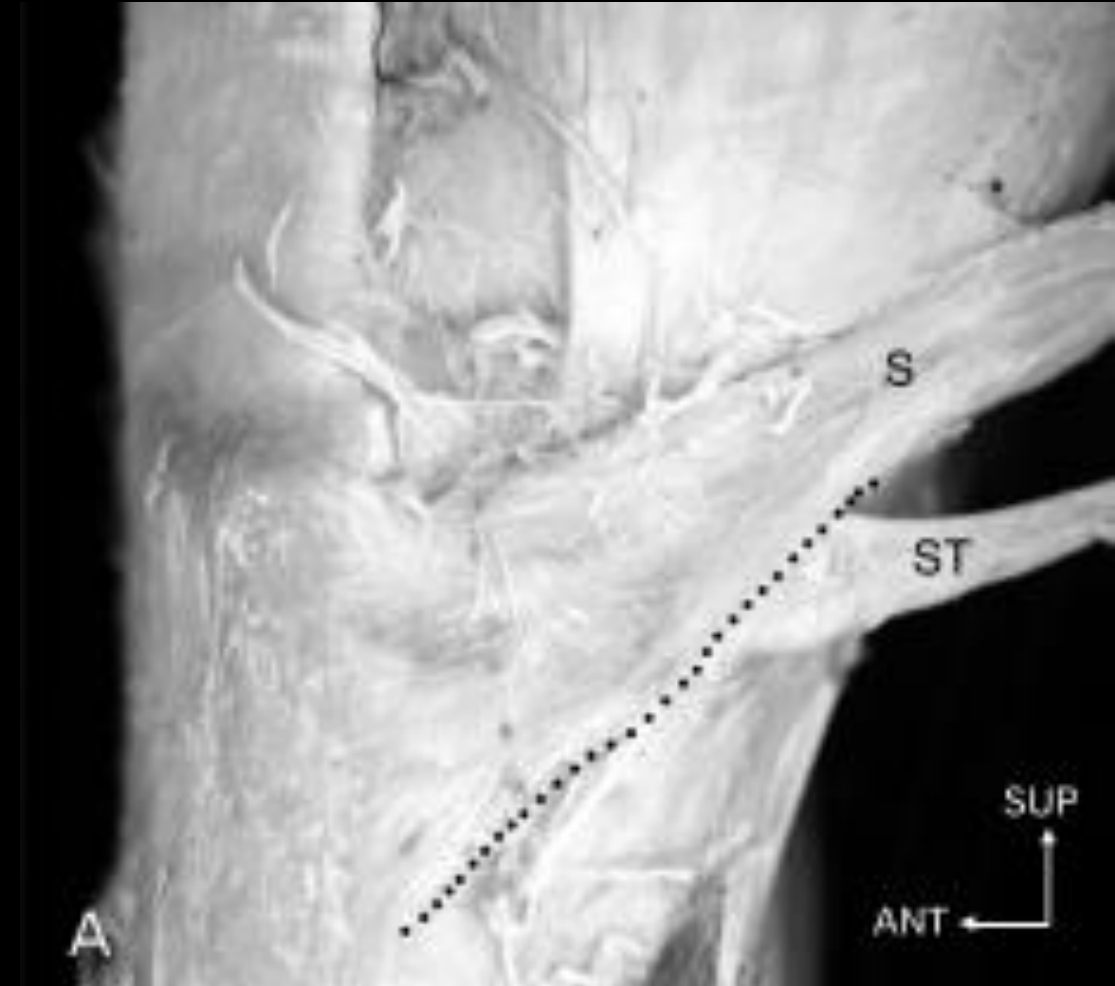# Pes anserinus: Anatomy

- Latin for “goose foot” and consists of the sartorius, gracilis, and semitendinosus tendons (from anterior to posterior).



# Pes anserinus: Anatomy

- Ivey M. *Orthopedics* 1993
  - 102 knees: 48% had 1 of 7 variations
  - Semitendinosus and gracilis fuse ~32 mm before the tibial attachment
  - Sartorius adheres to semitendinosus/gracilis near the tibial attachment



# Pes anserinus: Anatomy

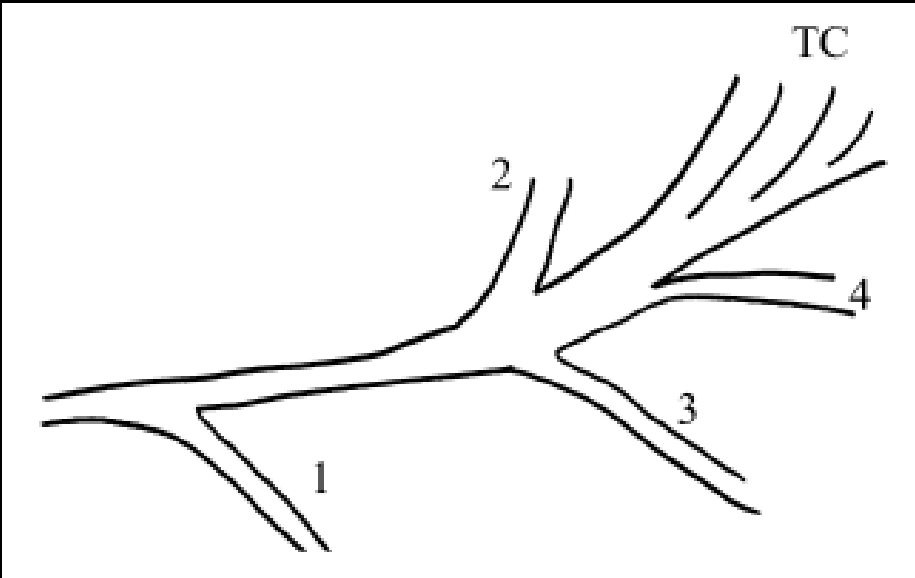
- Candal-Couto JJ. *The Knee* 2003
  - Described variations in 10 dissected knees

## Gracilis bands

1. Crural fascia
2. Sartorius
3. Gastrocnemius fascia
4. Semitendinosus

Anterior

P  
r  
o  
x  
i  
m  
a  
l

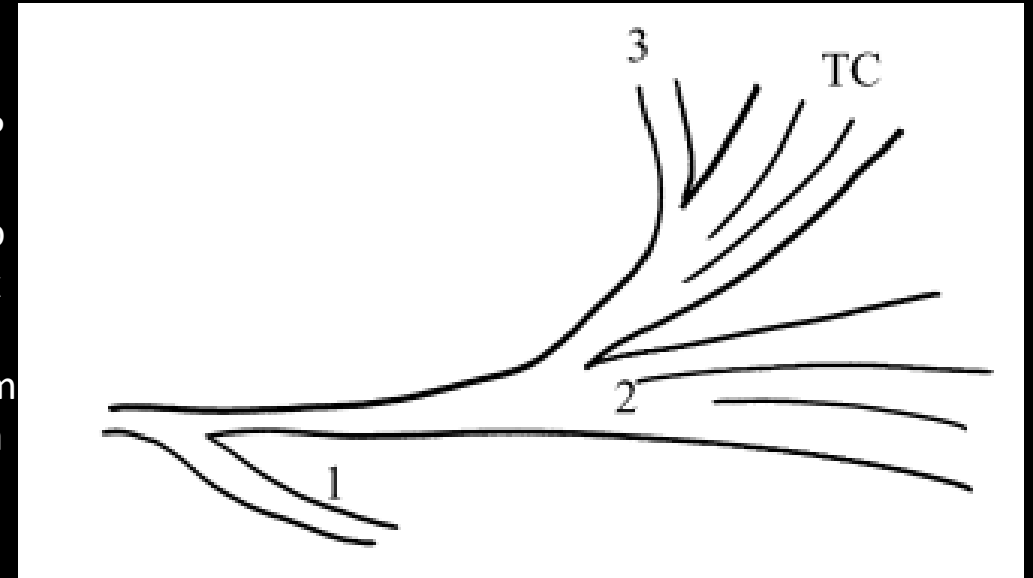


## Semitendinosus bands

1. Popliteal fascia
2. Gastrocnemius fascia
3. Gracilis

Anterior

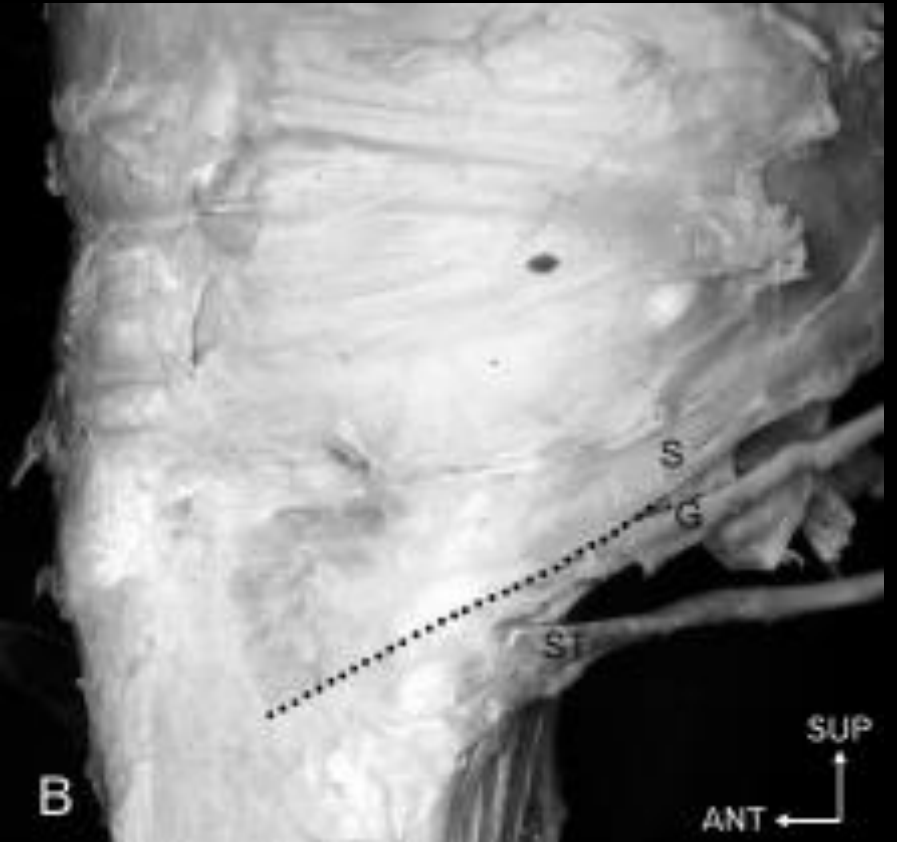
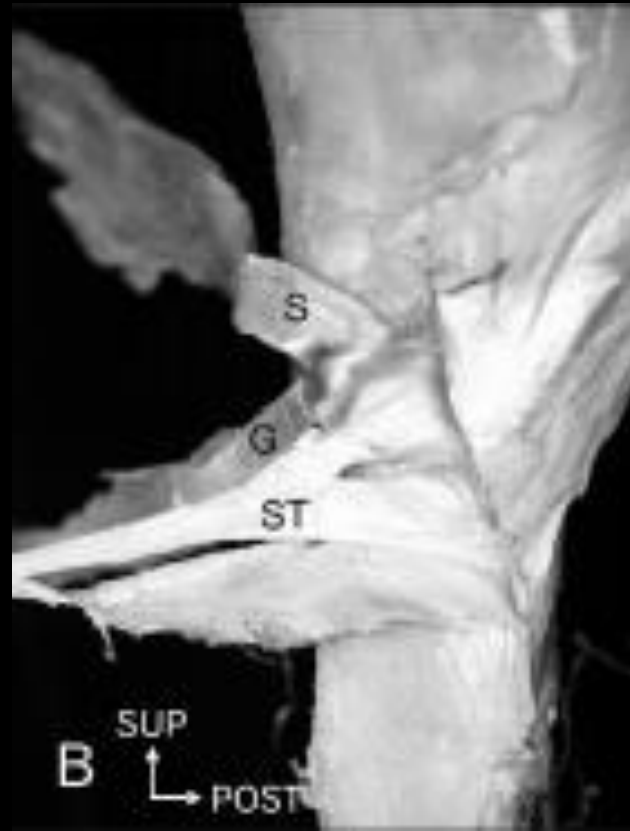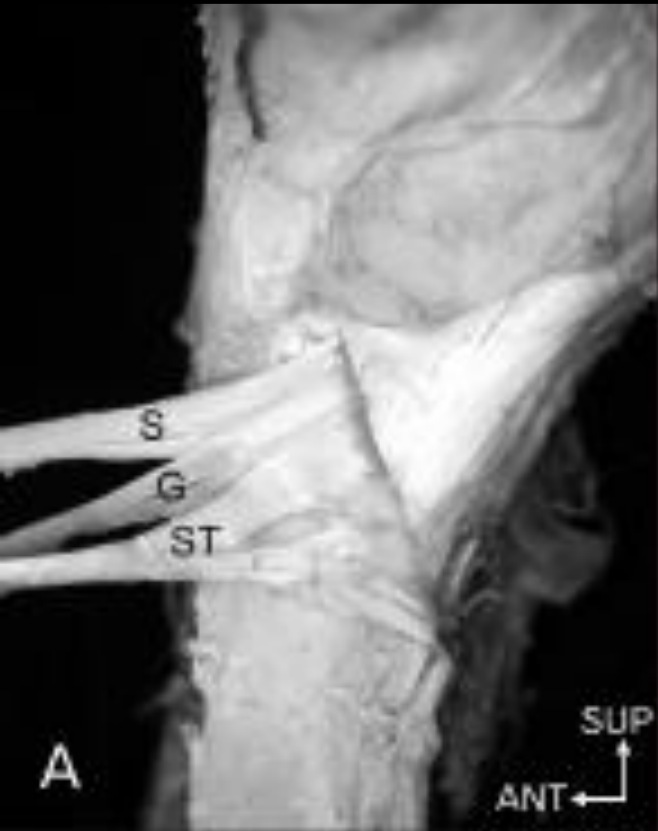P  
r  
o  
x  
i  
m  
a  
l

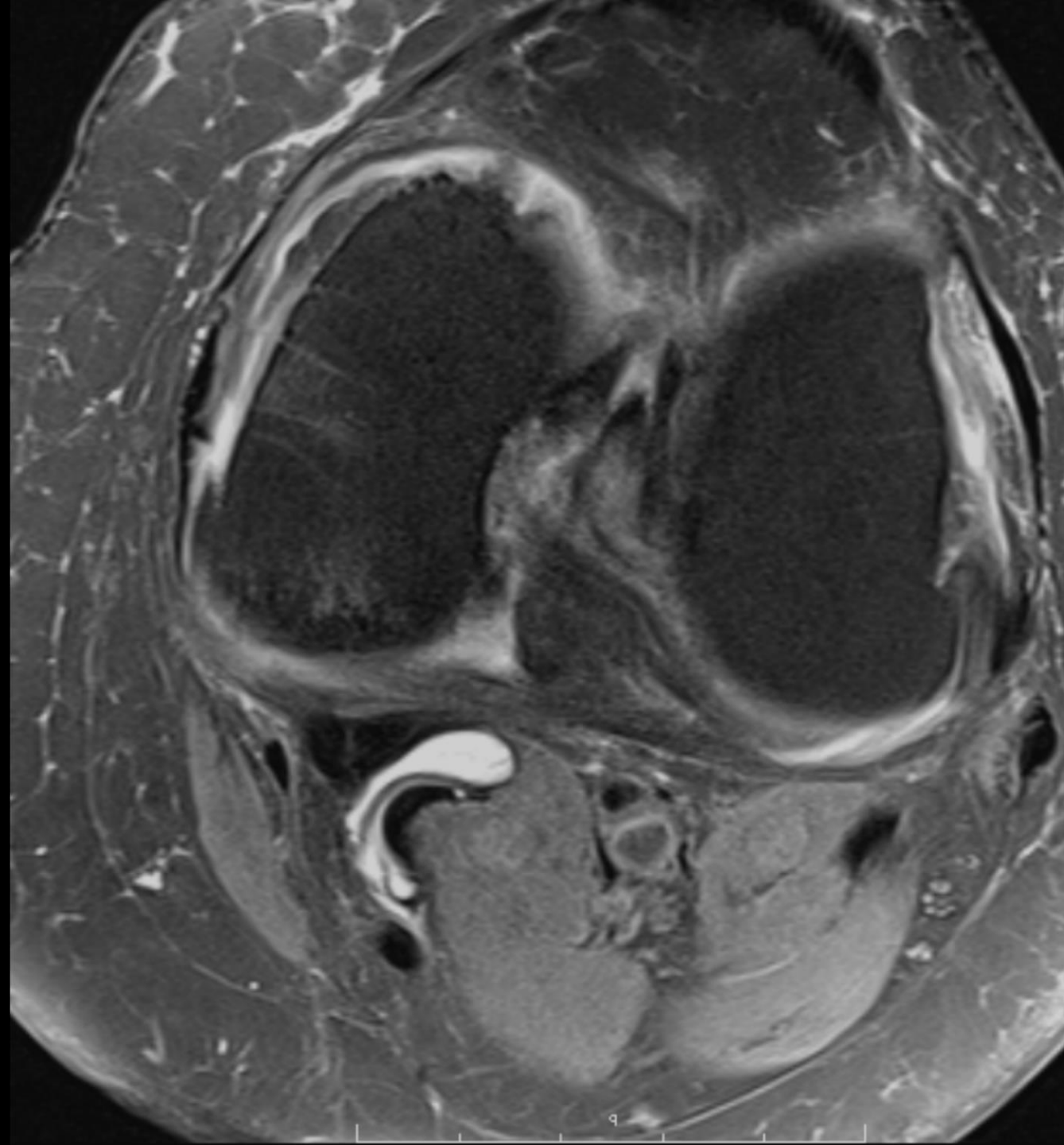


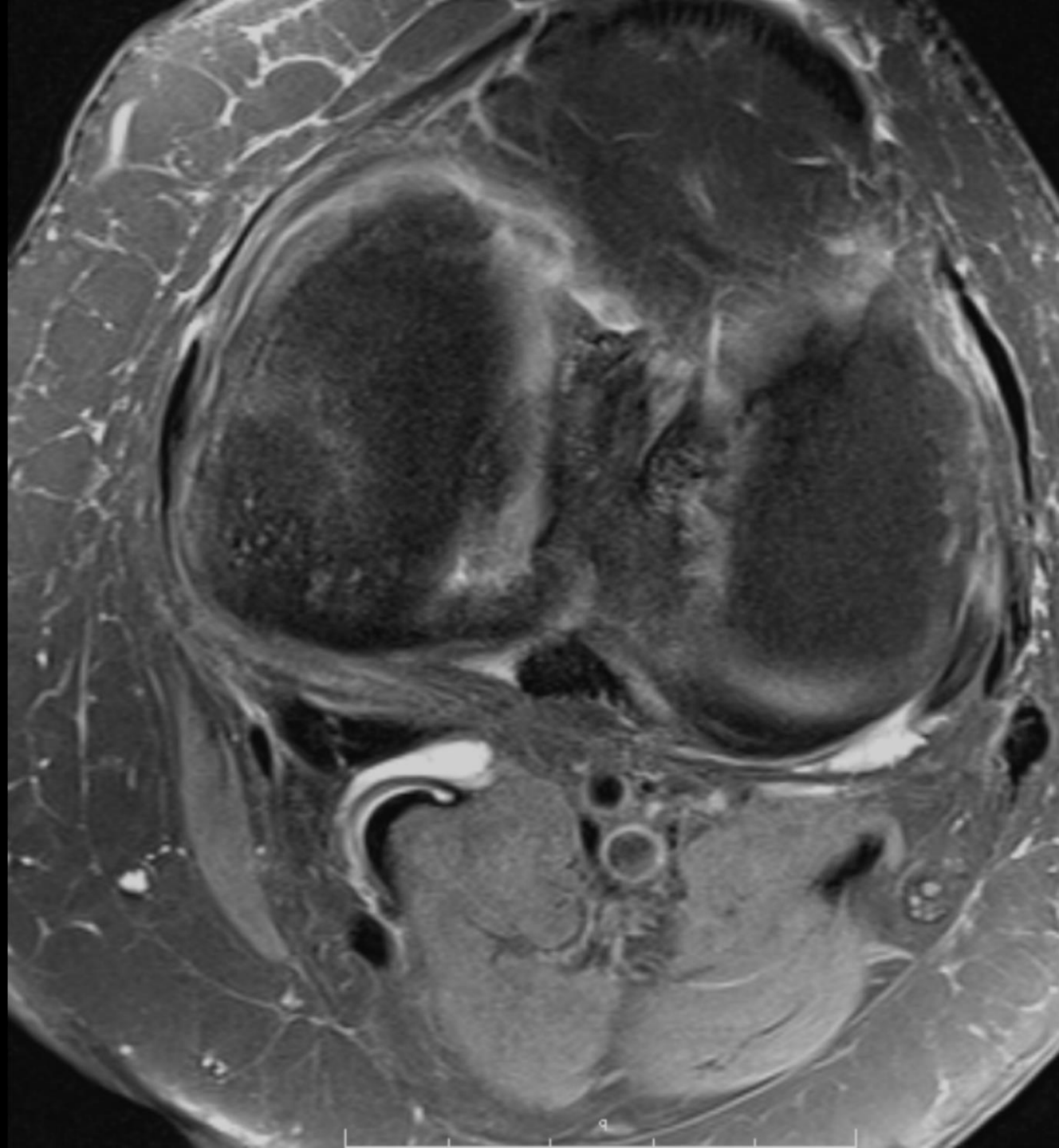
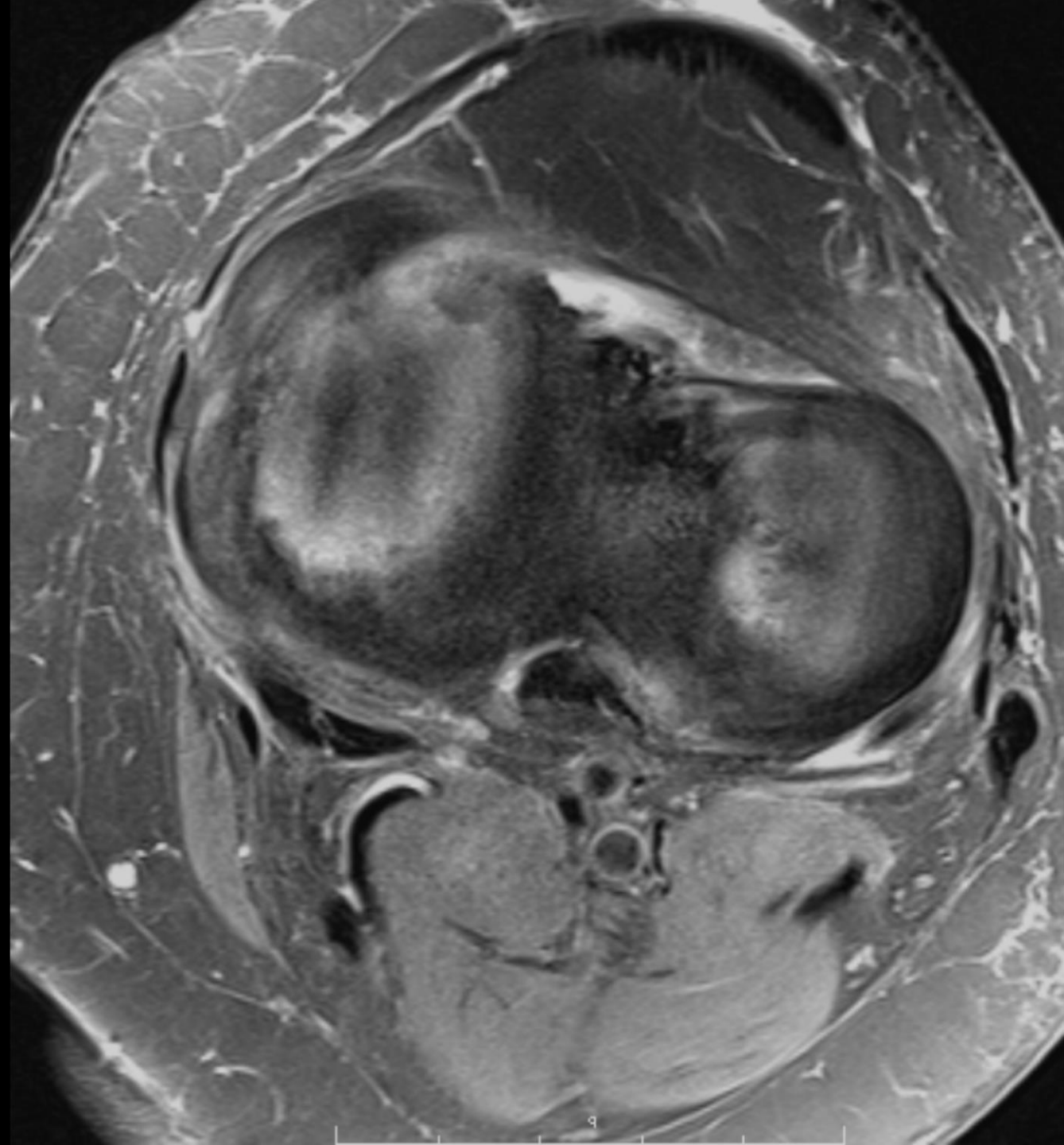# Pes anserinus: Anatomy

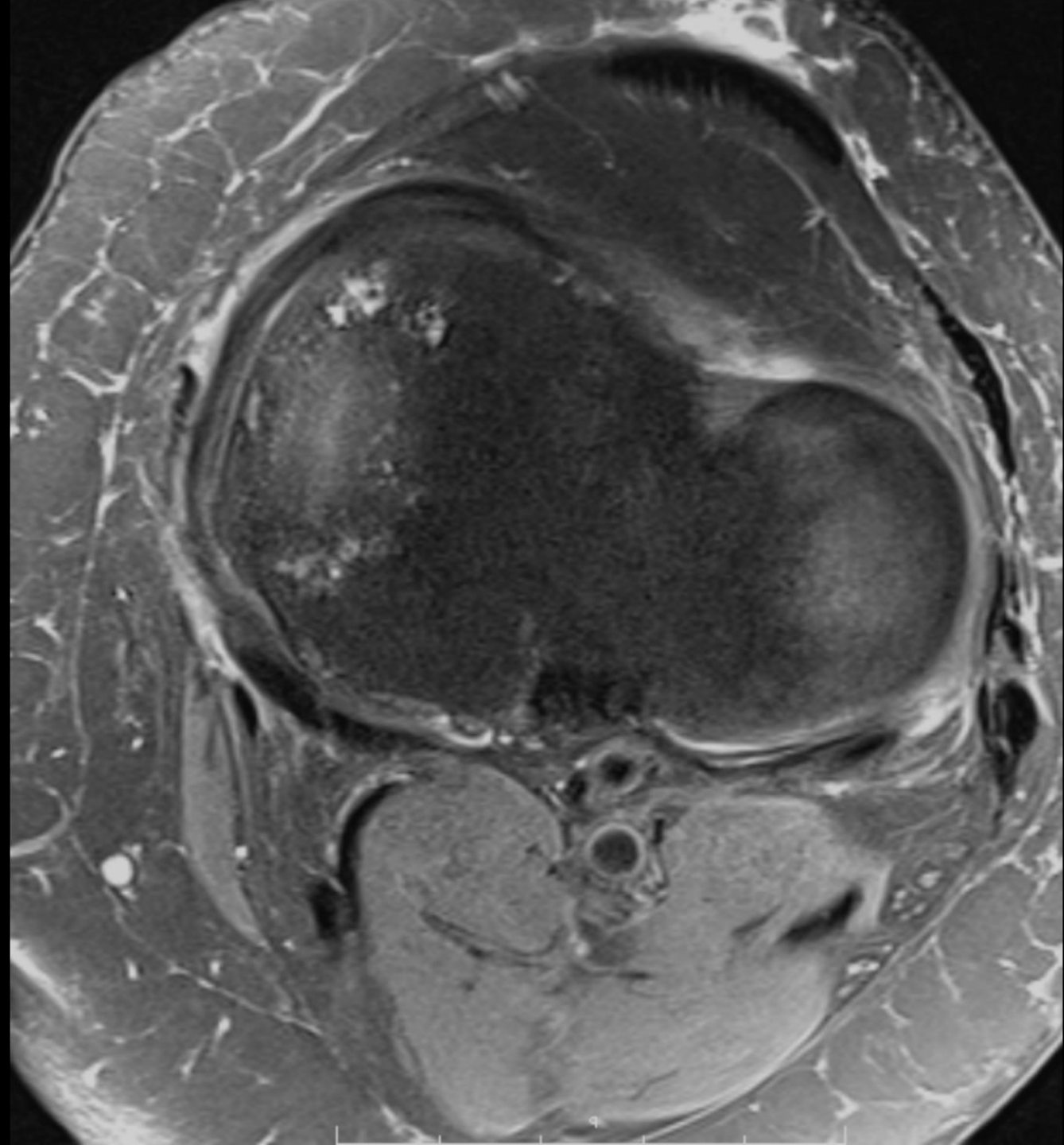- Semitendinosus variations
  - Can have one, two or three separate tendinous insertions
  - May insert separately
  - Several studies show constant band to gastrocnemius fascia

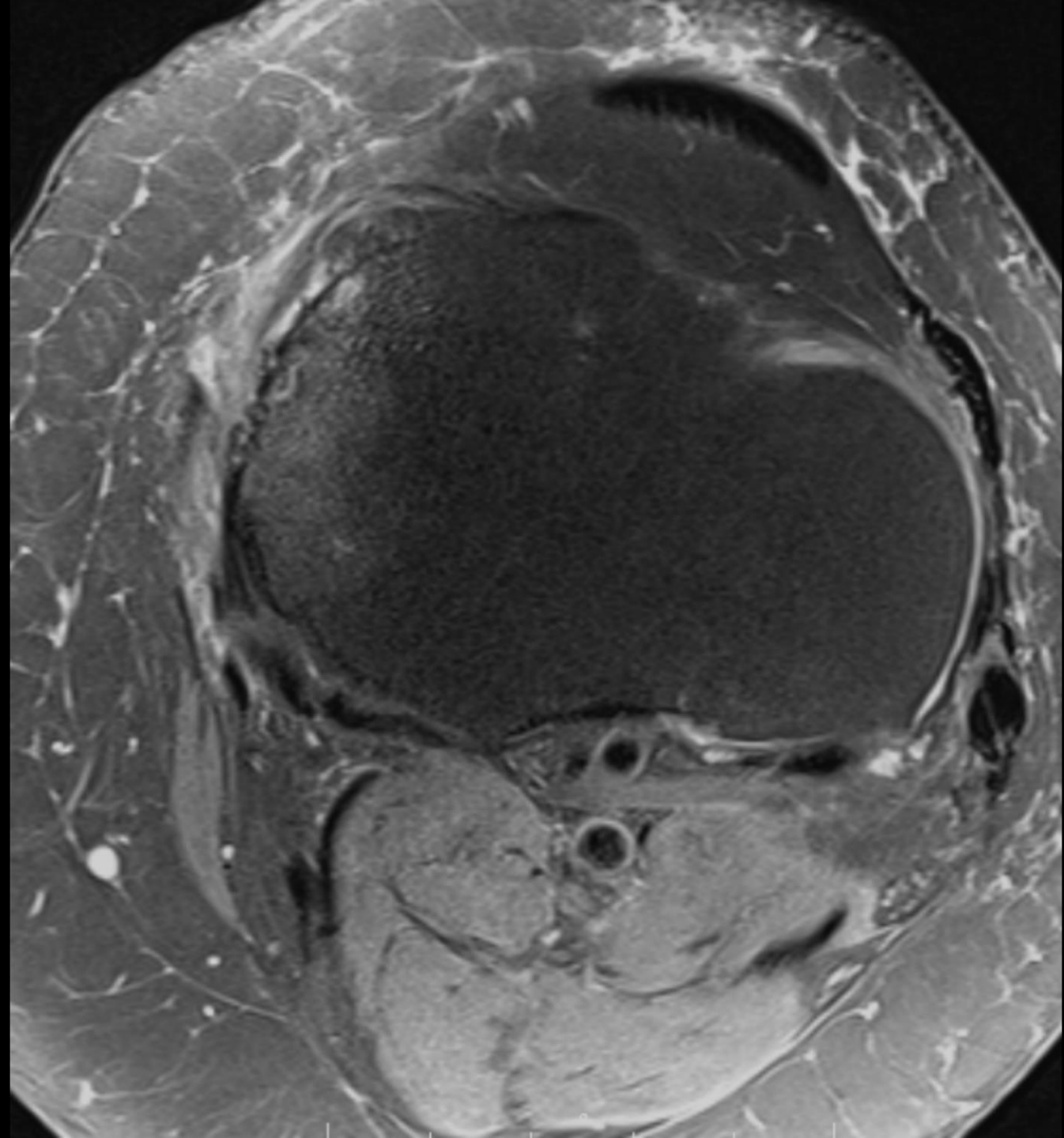


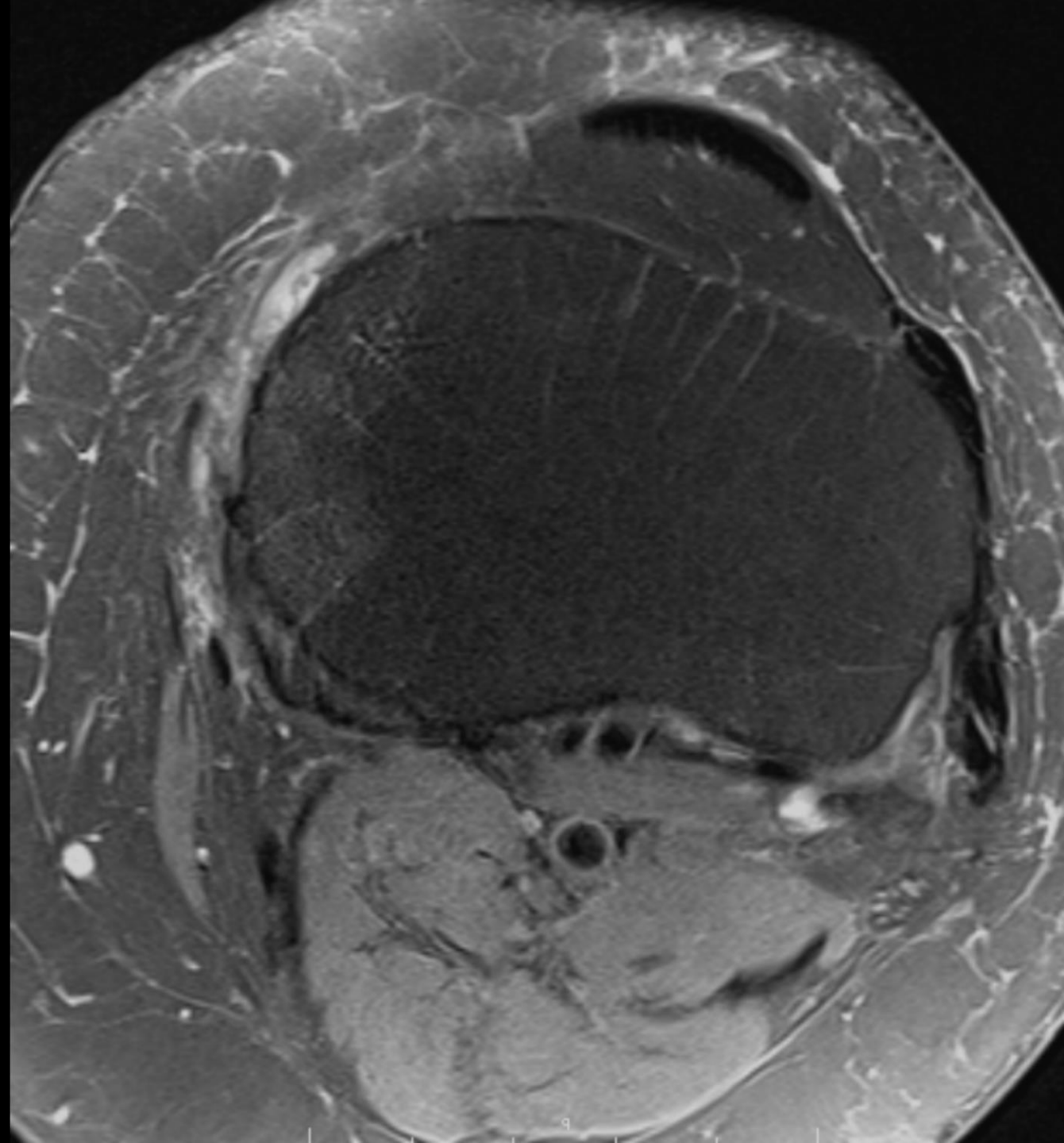

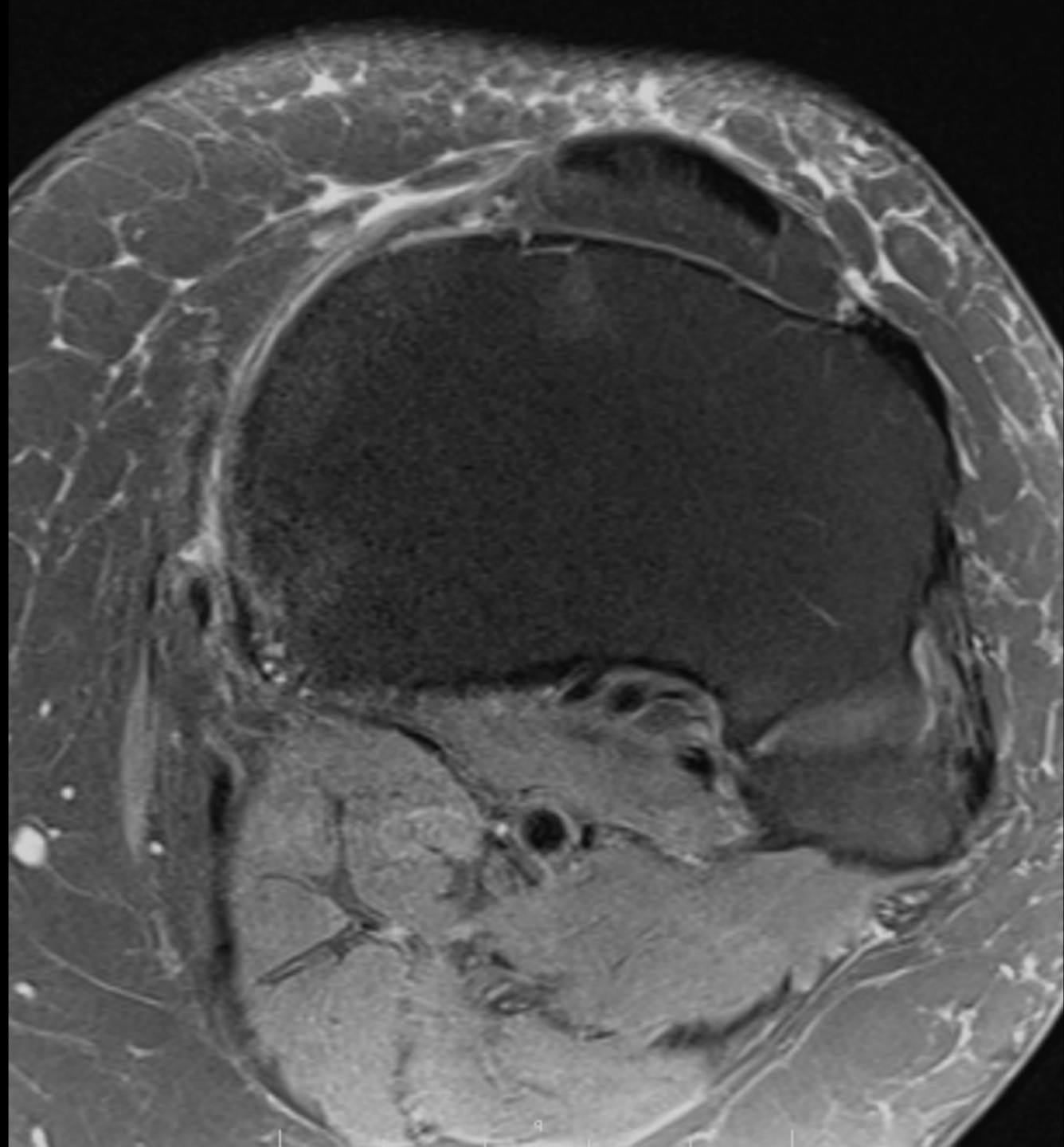













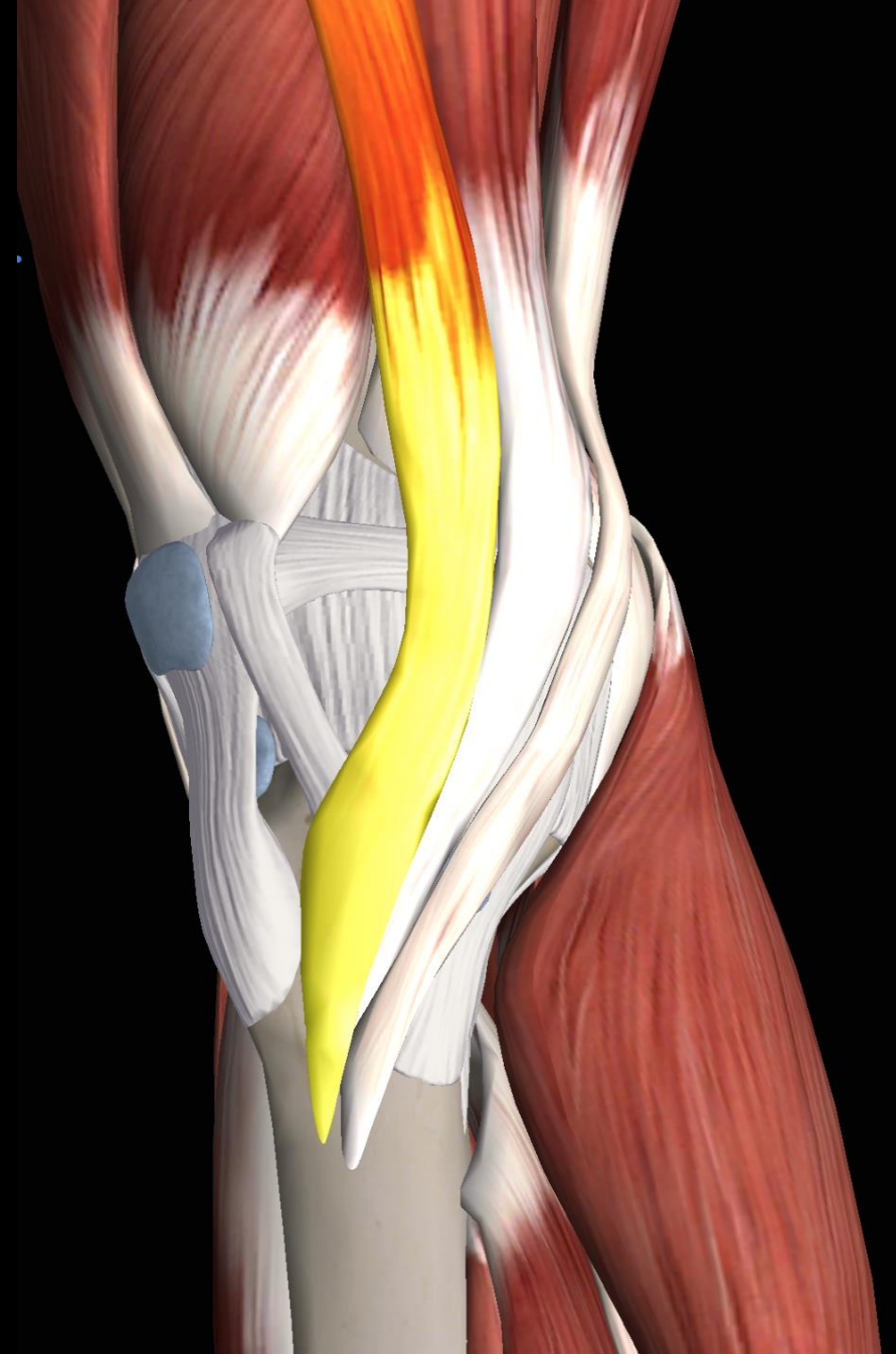
# Pes anserinus: Sartorius

Origin	Anterosuperior iliac spine
Insertion	Proximomedial tibia, anterior-most of the three tendons
Artery	Femoral artery
Nerve	Femoral nerve
Action	Flexion, lateral rotation, and abduction of the thigh; flexion and medial rotation of the leg

## Clinical pearls:

- Near posteromedial femoral condyle where friction can occur
- Most superficial pes anserinus tendon and prone to injury
- Longest muscle in human body (spans the hip and knee)

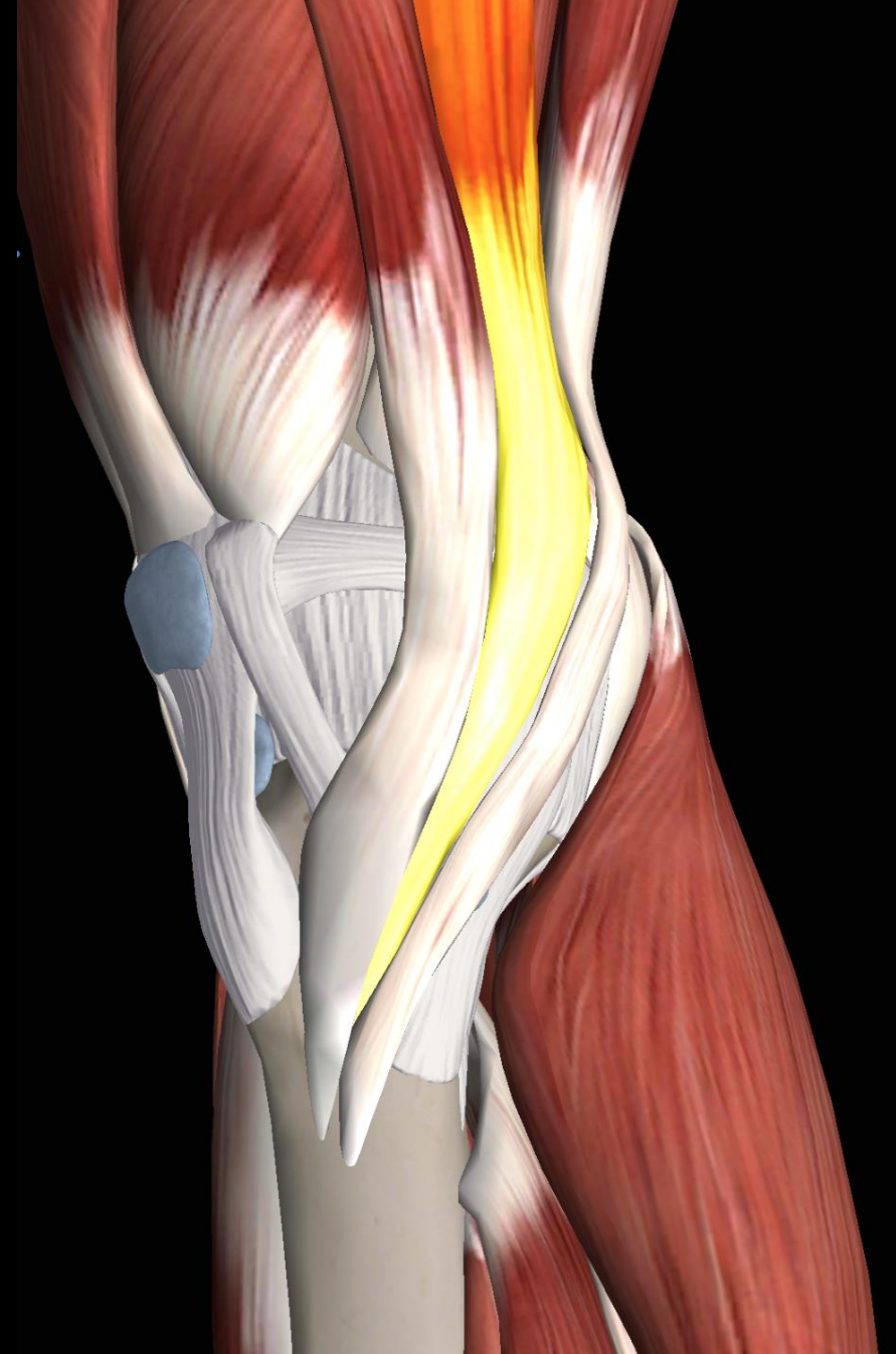

# Pes anserinus: Gracilis

Origin	Ischiopubic ramus
Insertion	Proximomedial tibia, middle of the three tendons
Artery	Medial femoral circumflex artery
Nerve	Anterior branch of the obturator nerve
Action	Flexion of hip and knee

## Clinical pearls:

- Near posteromedial femoral condyle where friction can occur
- Intimate with saphenous nerve, which can be injured during ACL graft harvesting
- Gracilis is Latin for slender

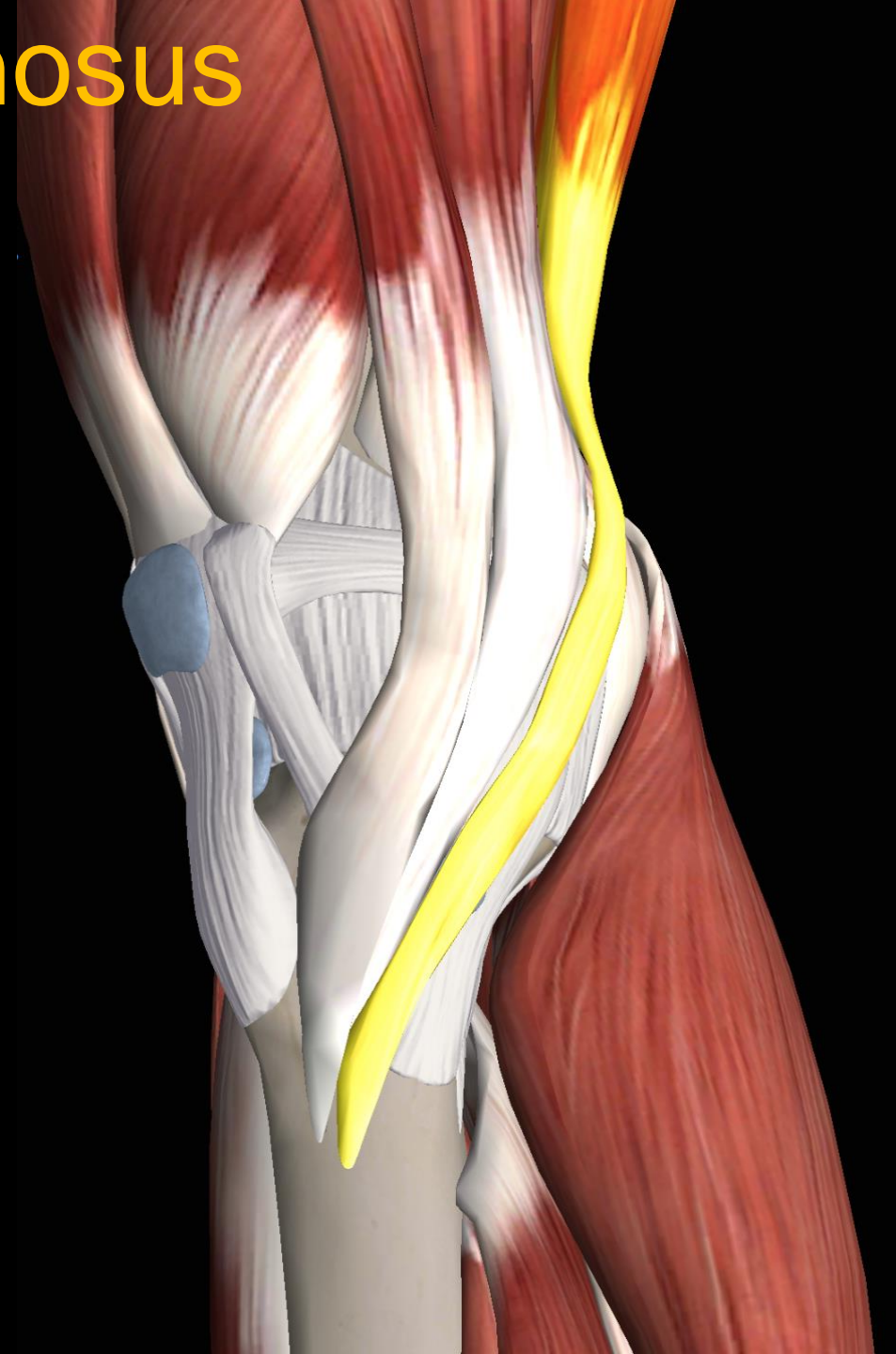

# Pes anserinus: Semitendinosus

Origin	Ischial tuberosity
Insertion	Proximomedial tibia, posterior-most of the three tendons
Artery	Inferior gluteal artery
Nerve	Sciatic nerve
Action	Flexion of knee and extension of hip

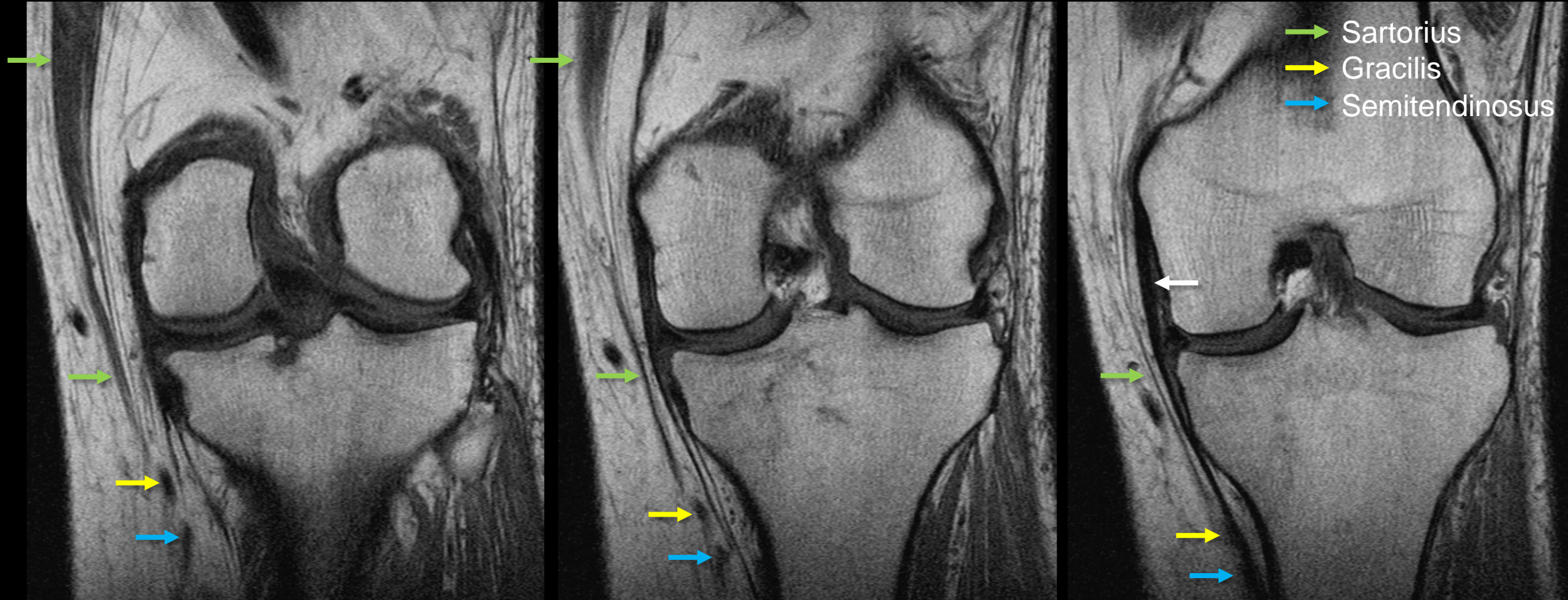
## Clinical pearl:

- Accessory insertions and fascial bands can cause premature ACL graft amputation during harvesting
- Lack of accessory insertions may predispose to pes snapping syndrome



# Pes anserinus and medial knee: Coronals

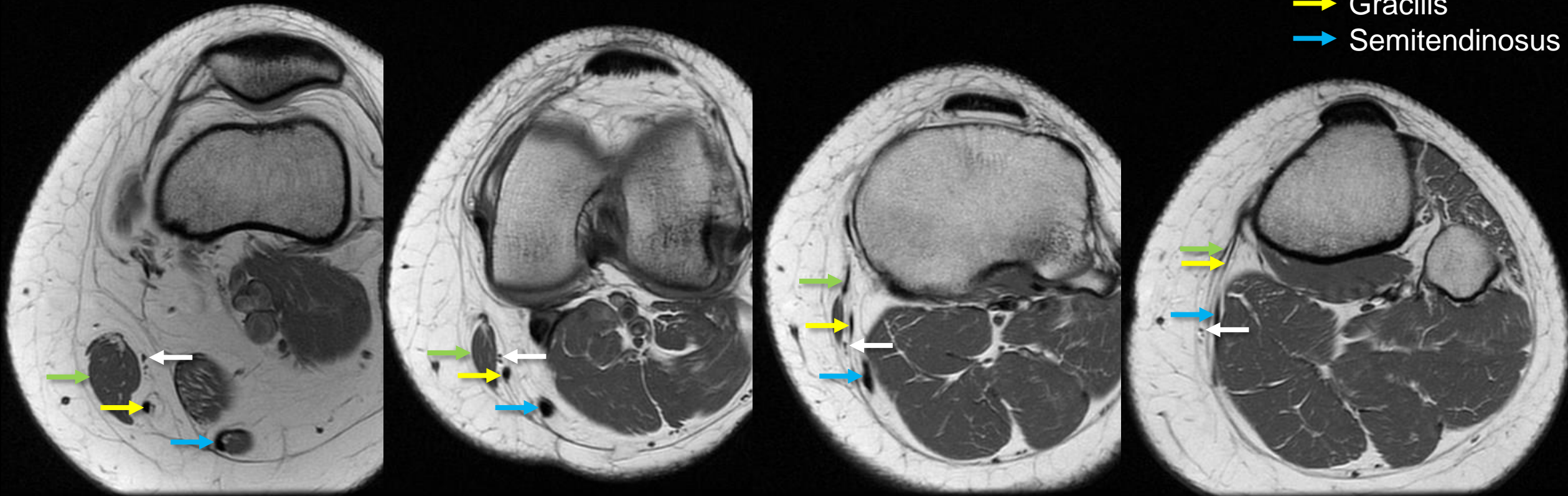
- Posterior to anterior images show sartorius broadening prior to fusing with the two deeper tendons. Note, that the pes anserinus is superficial to tibial collateral ligament (white arrow).



# Pes anserinus and medial knee: Axials

- Proximal to distal images show the pes anserinus. Saphenous nerve (white arrow) exits between the sartorius and gracilis as it pierces the deep fascia.

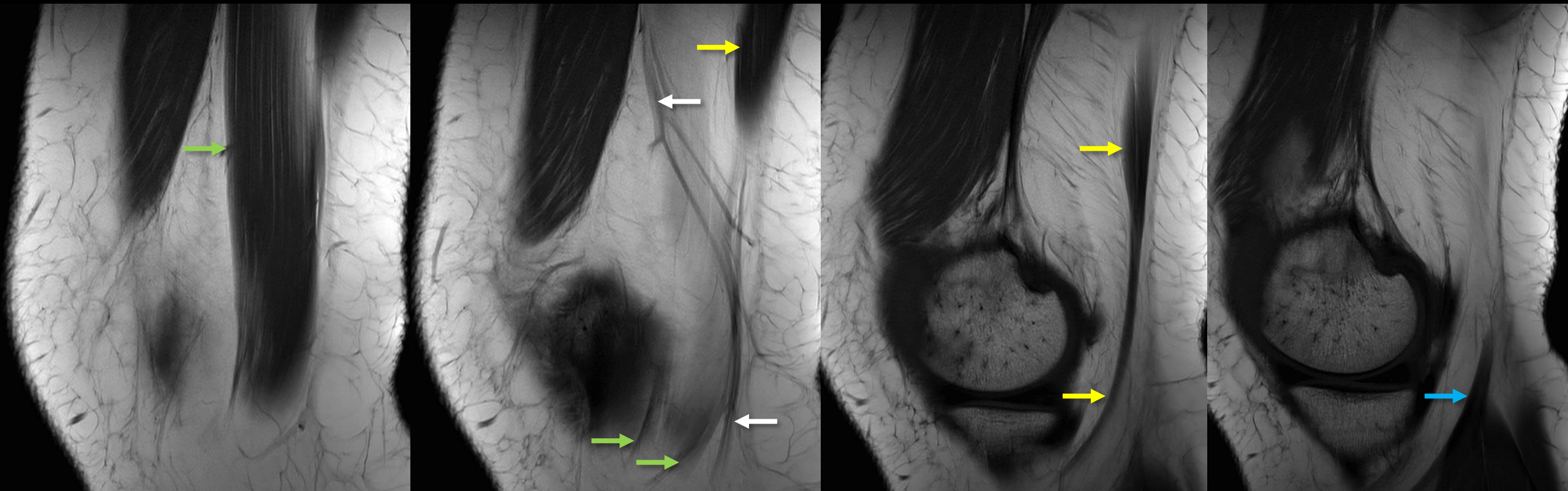
- Sartorius
- Gracilis
- Semitendinosus



# Pes anserinus and medial knee: Sagittals

- Medial to lateral images show the pes anserinus. The sartorius and gracilis are in close proximity to the medial femoral condyle where friction can occur. The saphenous nerve (white arrow) is also seen.

→ Sartorius  
→ Gracilis  
→ Semitendinosus





# Pes anserinus: cystic pathologies

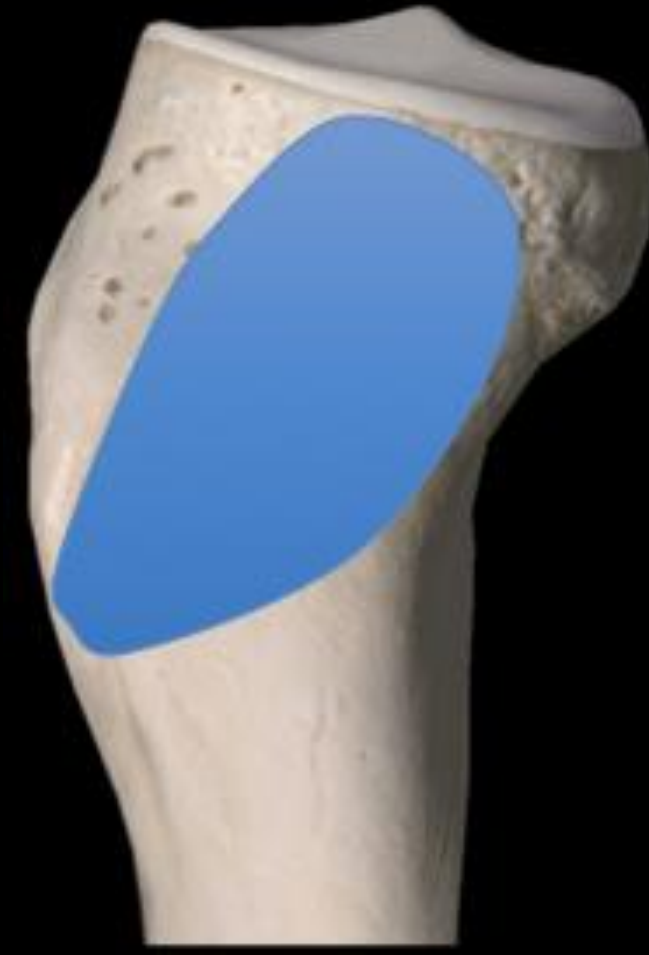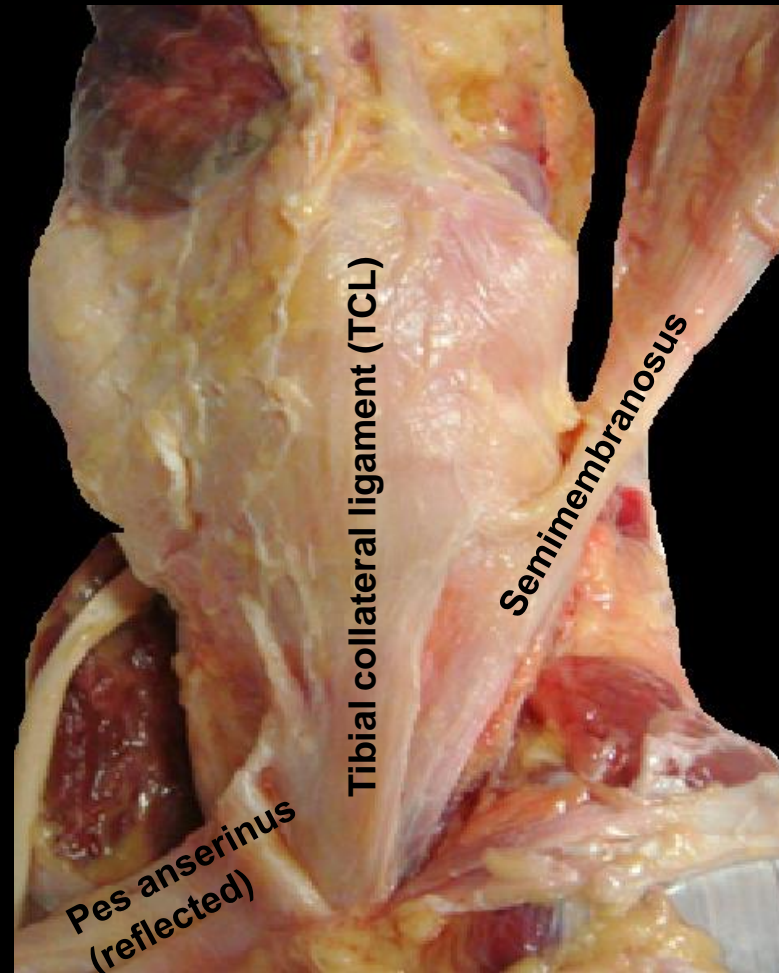
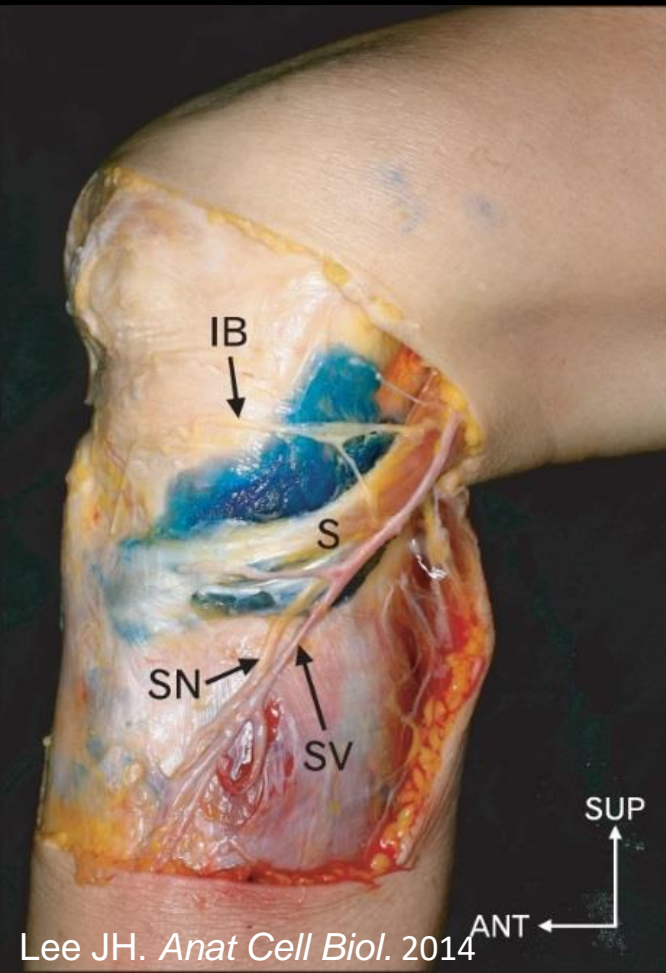
<b>MEDIAL KNEE FLUID/CYSTIC LESIONS</b>
Pes anserinus bursitis
Semimembranosus bursitis
Medial collateral ligament bursitis
Parameniscal cyst
Cystic tumors
Posteromedial friction syndrome

- A sound anatomic understanding of the medial knee usually allows differentiation these entities



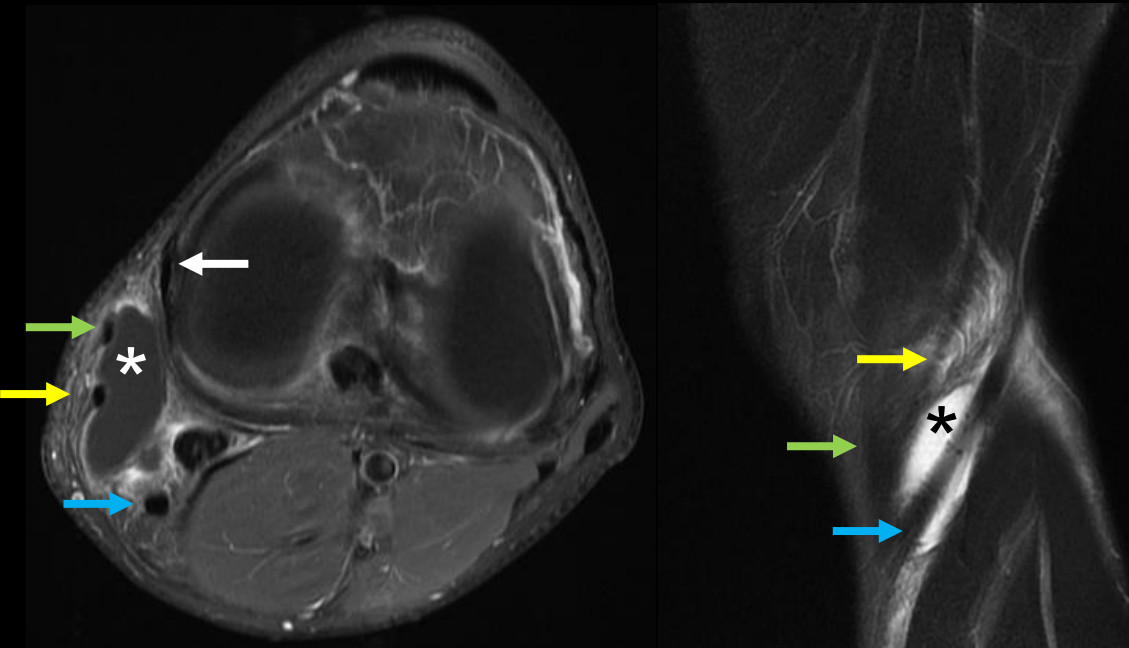
# Anatomy: Pes anserinus bursa

- Deep to pes anserinus tendons
- Superficial to the TCL
- Extends 15 mm below TT
- Extends to joint line, occasionally above

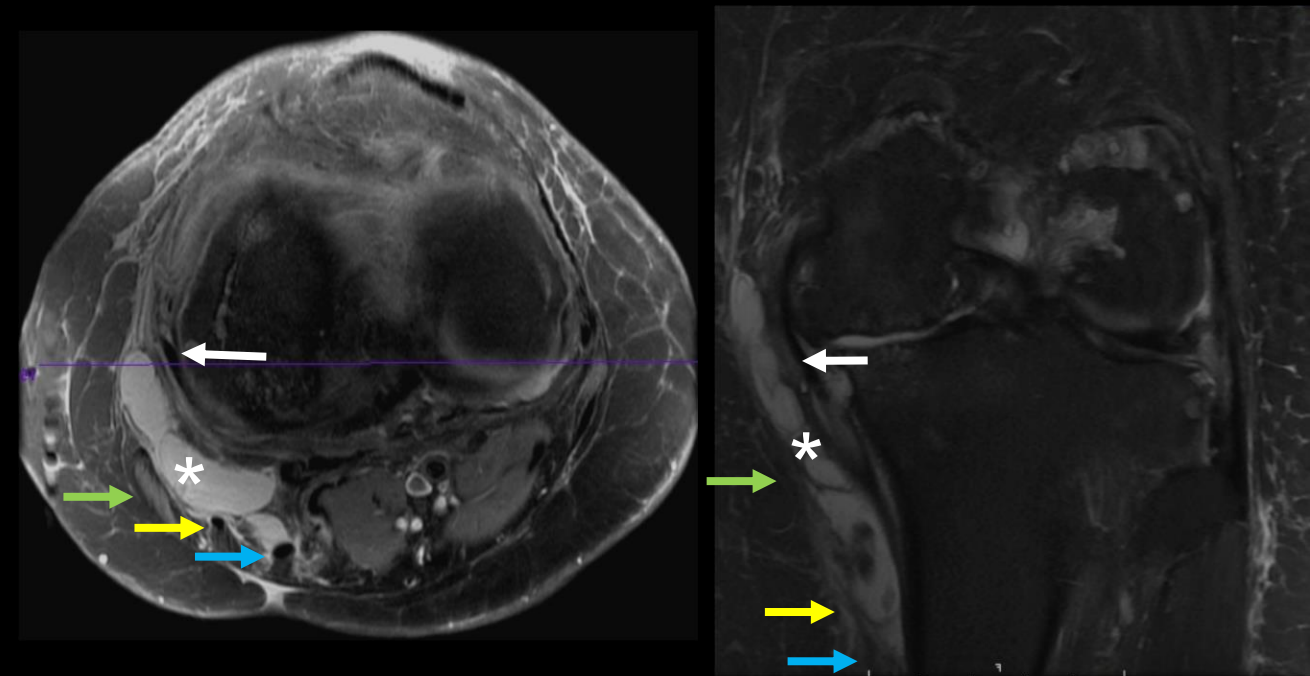


# Medial knee fluid/cystic lesions

- *Pes anserinus bursitis* (asterisk)
  - Bursa is deep to the pes anserinus and superficial to the TCL (white arrow)
  - Occurs in runners, but is also associated with diabetes and obesity
  - May be caused by friction with osteophytes



Pes anserine bursitis in an active patient

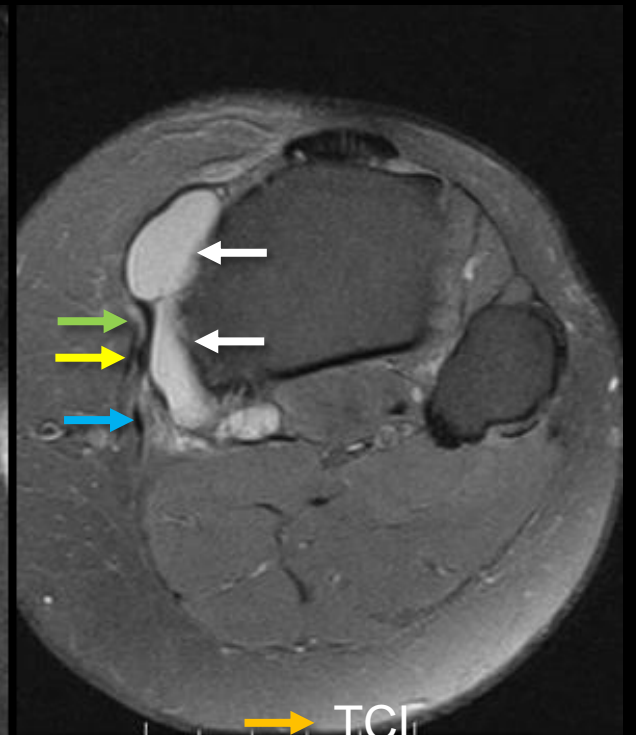
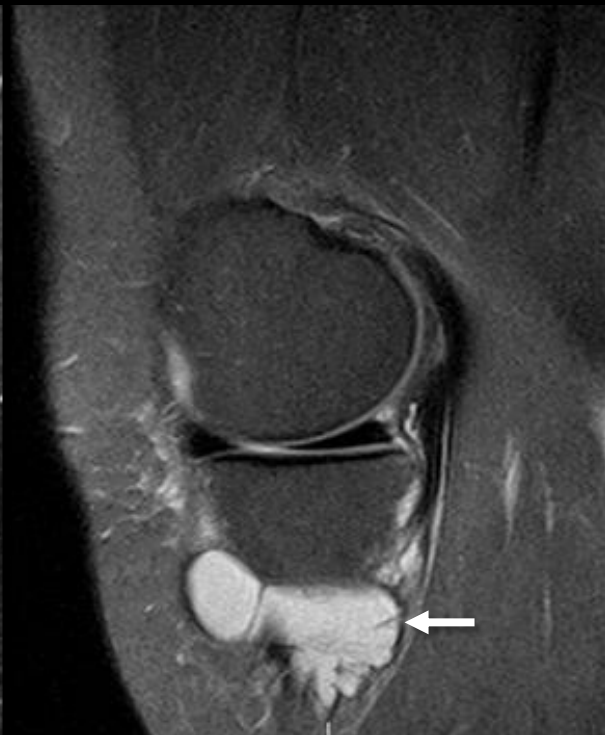
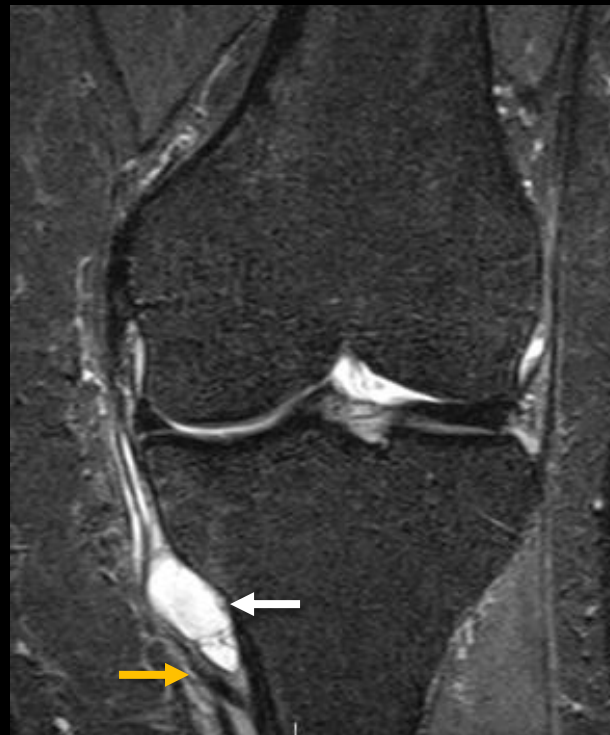
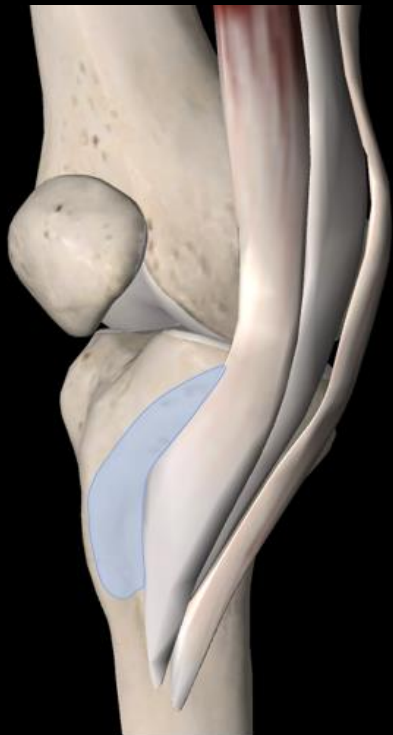Pes anserine bursitis with osteoarthrosis

- Sartorius
- Gracilis
- Semitendinosus

# Medial knee fluid/cystic lesions

- *Pes anserinus bursitis* (white arrow)
  - Bursa is interposed between pes anserinus and tibia, but may invaginate deep to the TCL



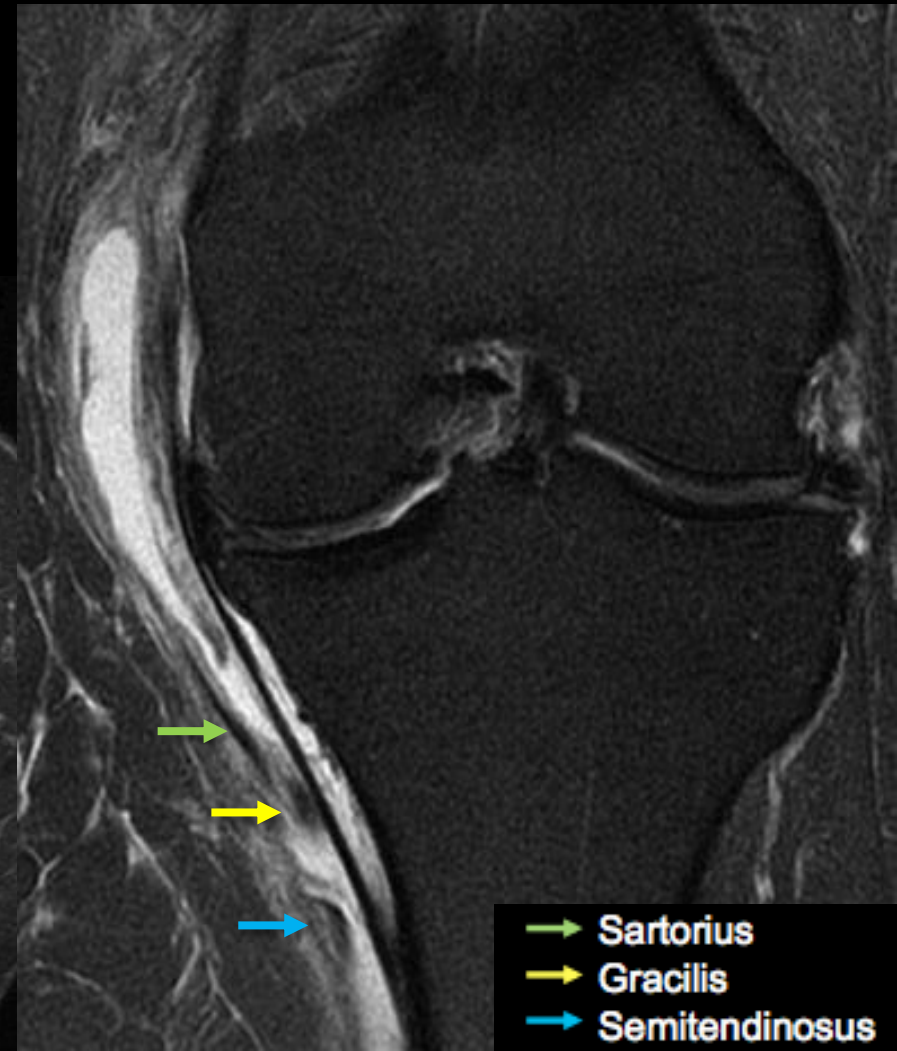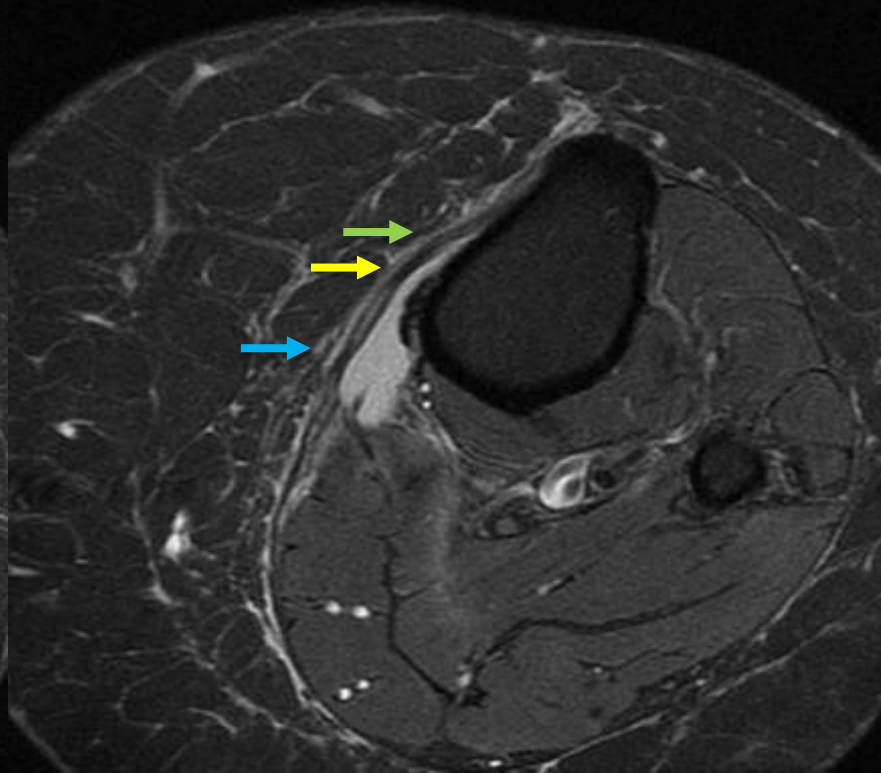
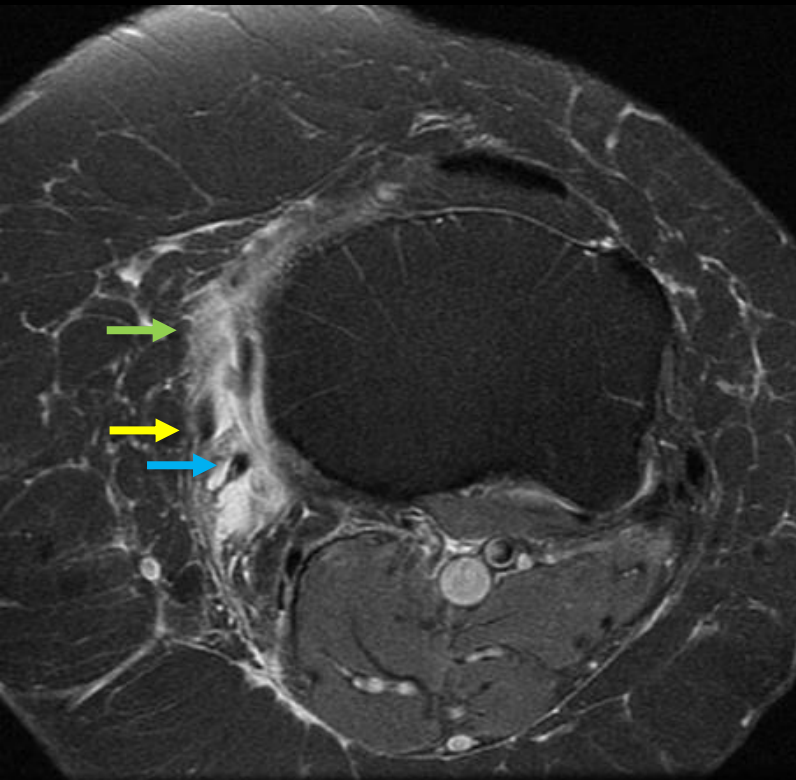
M. Pathria, MD

- TCL
- Sartorius
- Gracilis
- Semitendinosus

# Medial knee fluid/cystic lesions

- *Pes anserinus bursitis*
  - May be post-traumatic

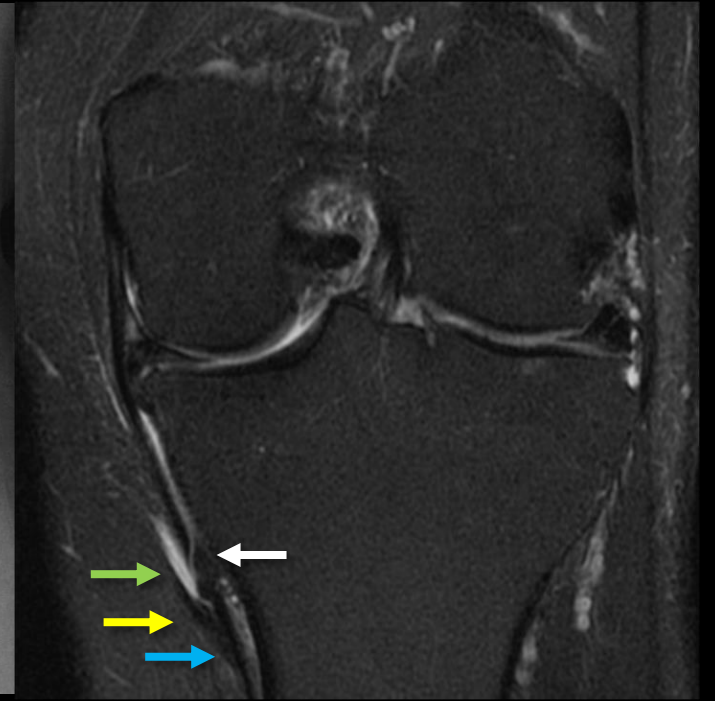
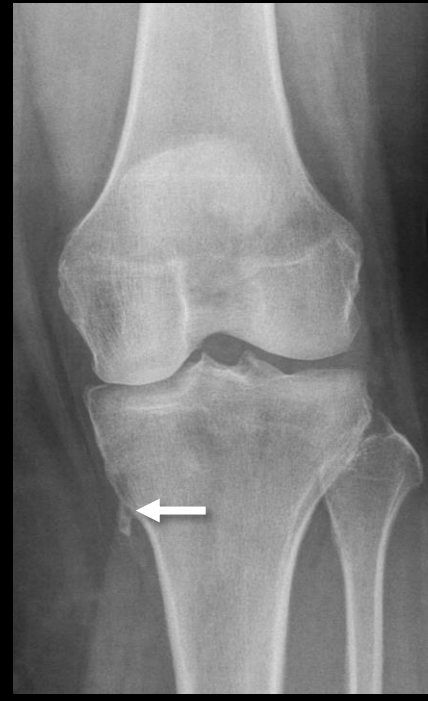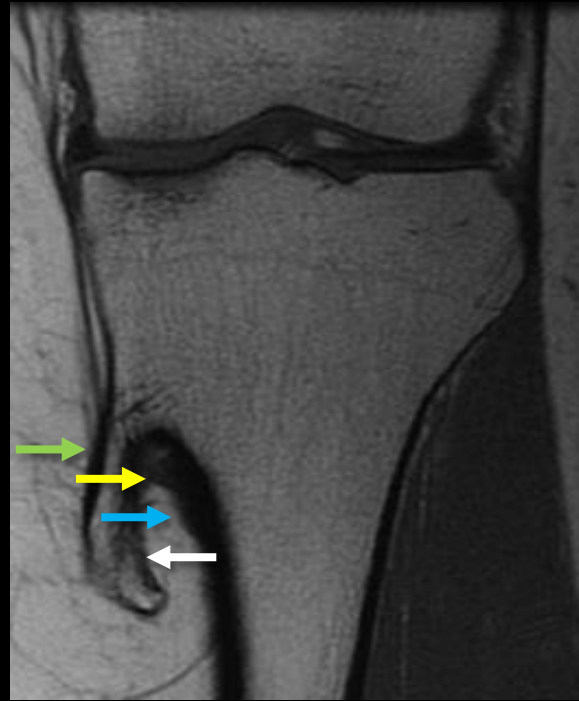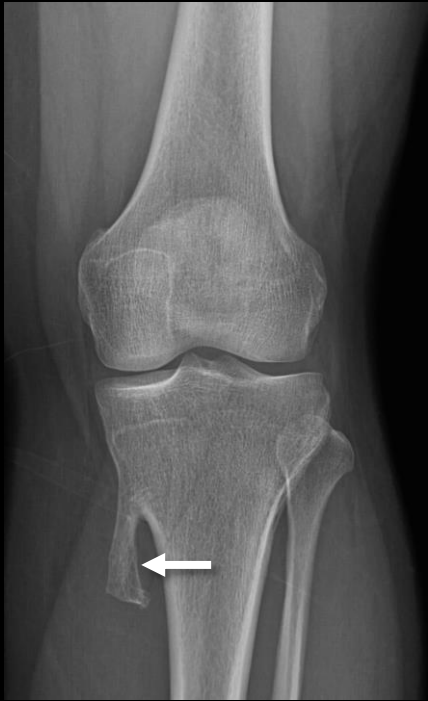Medial knee pain after being hit by a golf cart



→ Sartorius  
→ Gracilis  
→ Semitendinosus

# Medial knee fluid/cystic lesions

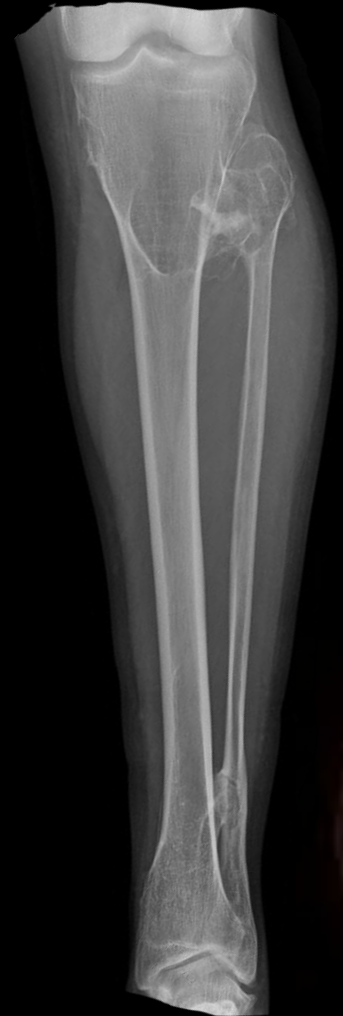- *Pes anserinus bursitis*
  - Can result from friction with an osteochondroma (even small ones)
  - This site is not uncommon for osteochondromas



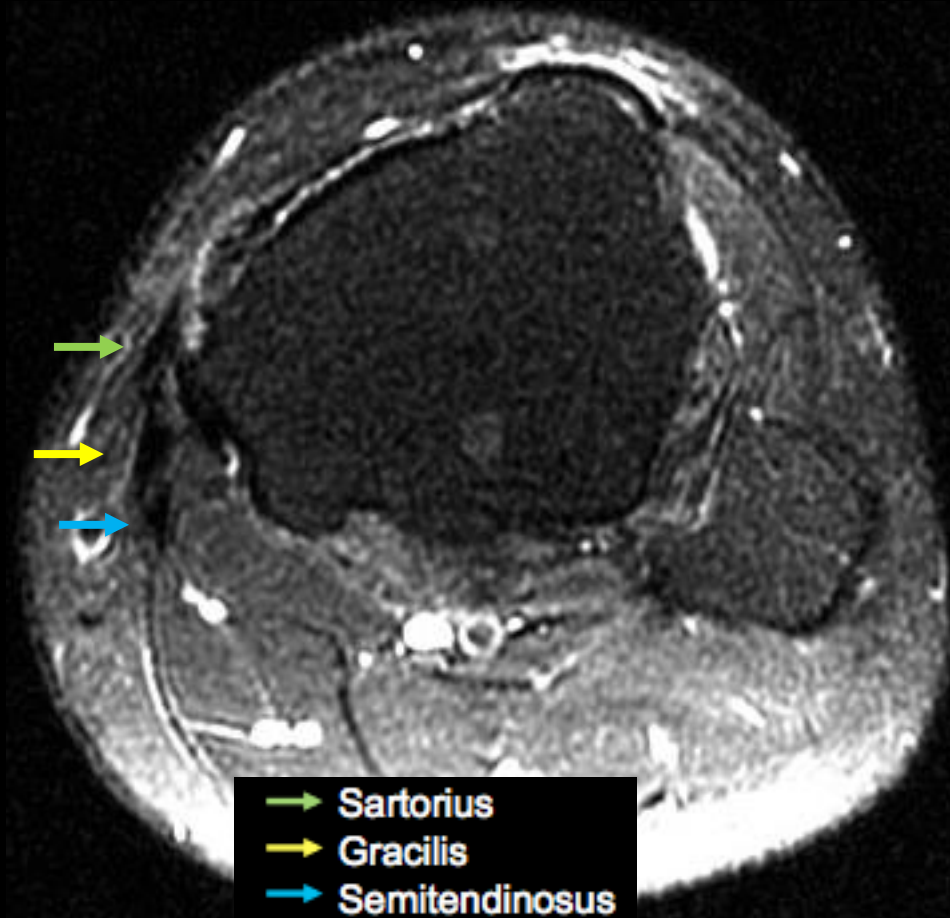
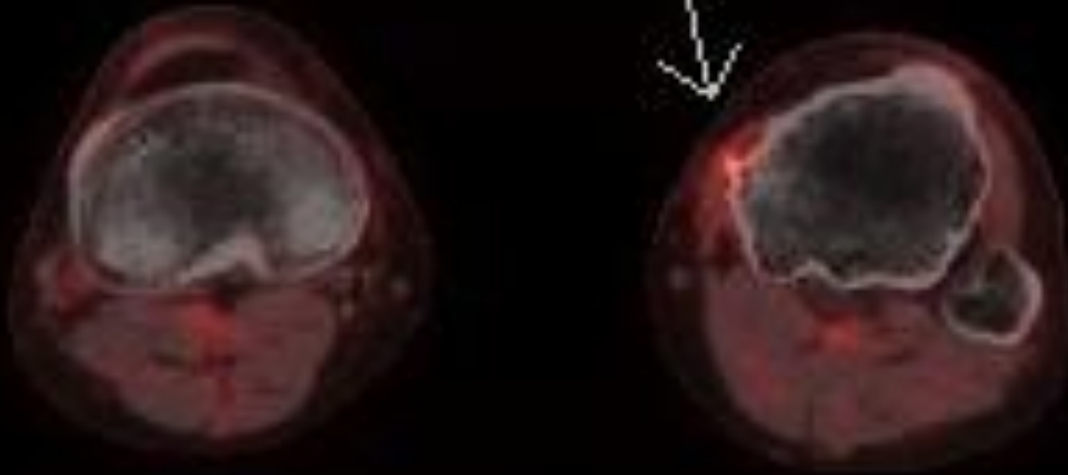
- Sartorius
- Gracilis
- Semitendinosus

# Medial knee fluid/cystic lesions

- *Pes anserinus inflammation*
  - Multiple hereditary osteochondromatosis with new pain at proximal medial tibia



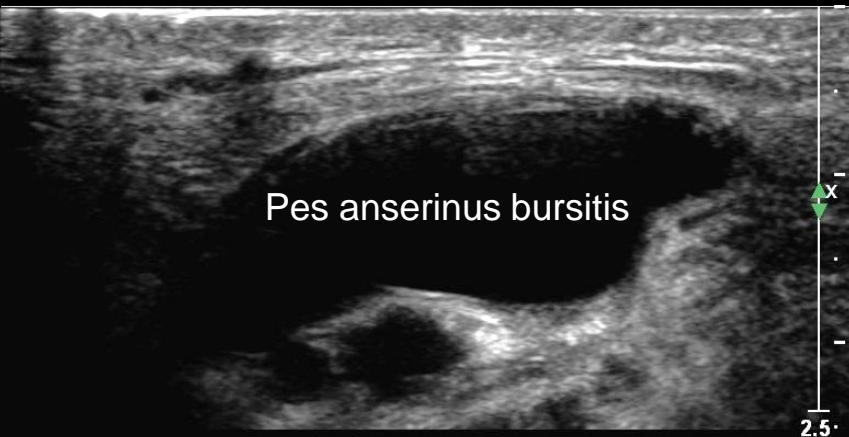SUV max = 2.6



→ Sartorius  
→ Gracilis  
→ Semitendinosus

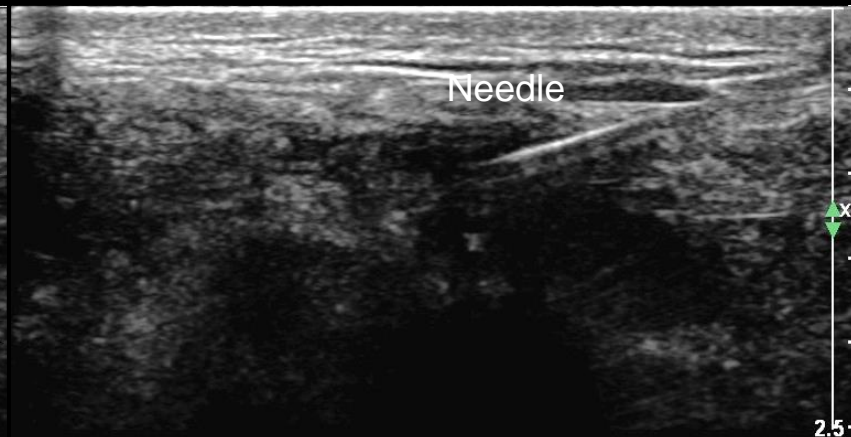# Medial knee fluid/cystic lesions

- *Pes anserinus bursitis*
  - Often self-limited and treated conservatively
  - Aspiration and local analgesic/steroid injection (white arrow) can be performed
    - Lee JH. *Anat Cell Biol.* 2014
      - suggest injection site 2 cm medial and 1 cm superior to inferomedial tibial tuberosity



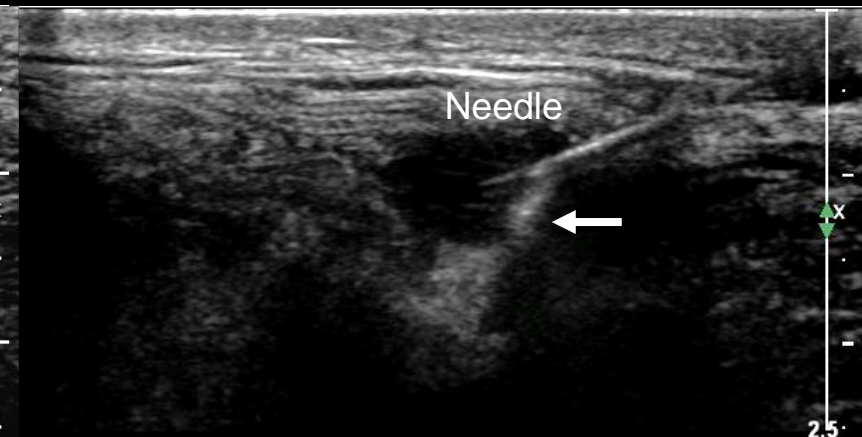
RT KNEE LONG

Initial image



RT KNEE LONG

Aspiration



RT KNEE LONG

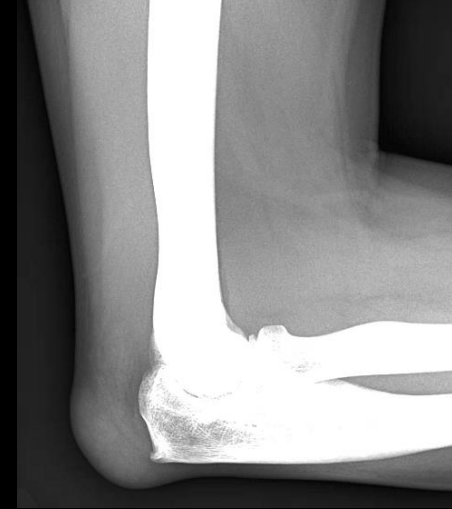Steroid injection

B. Huang, MD

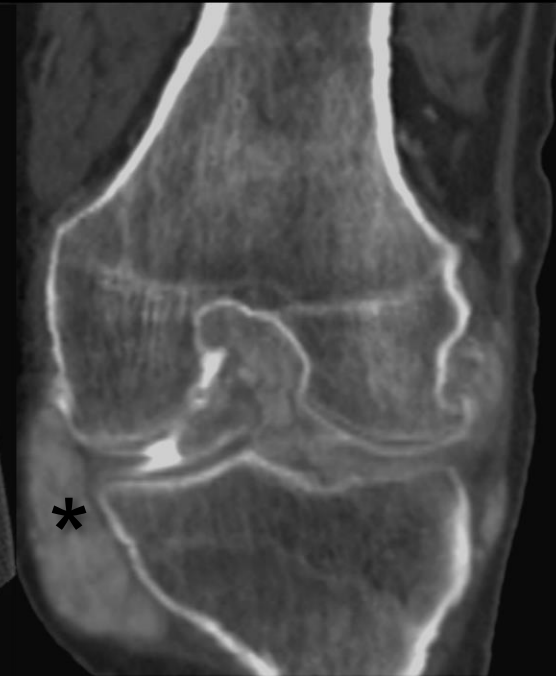
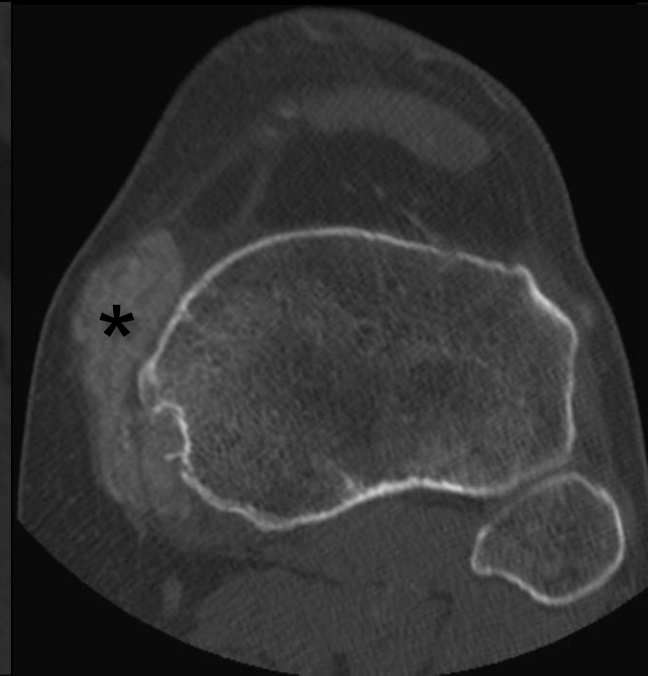
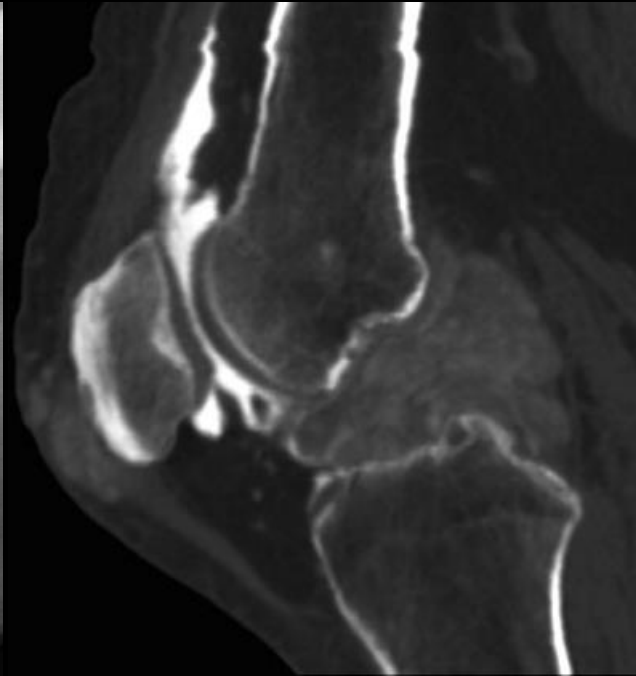
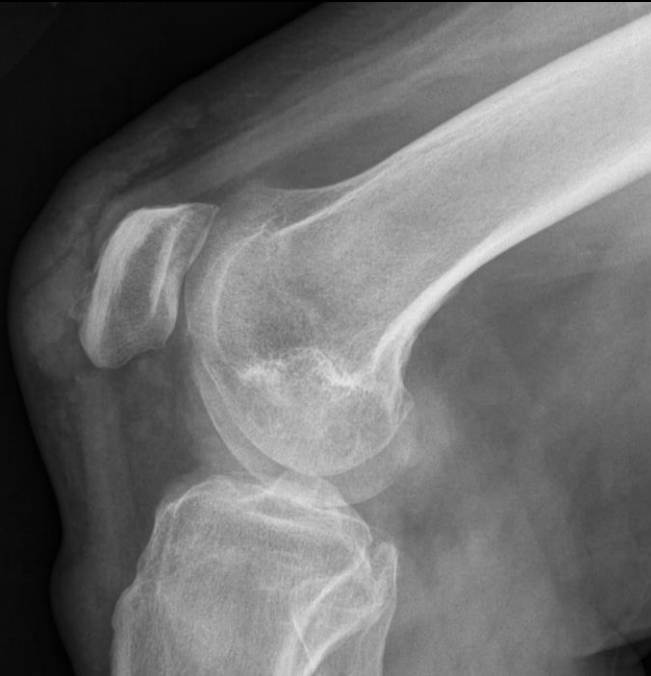# Crystal deposition at the pes anserinus

- *Gout*

- Gout is a known cause of olecranon bursitis



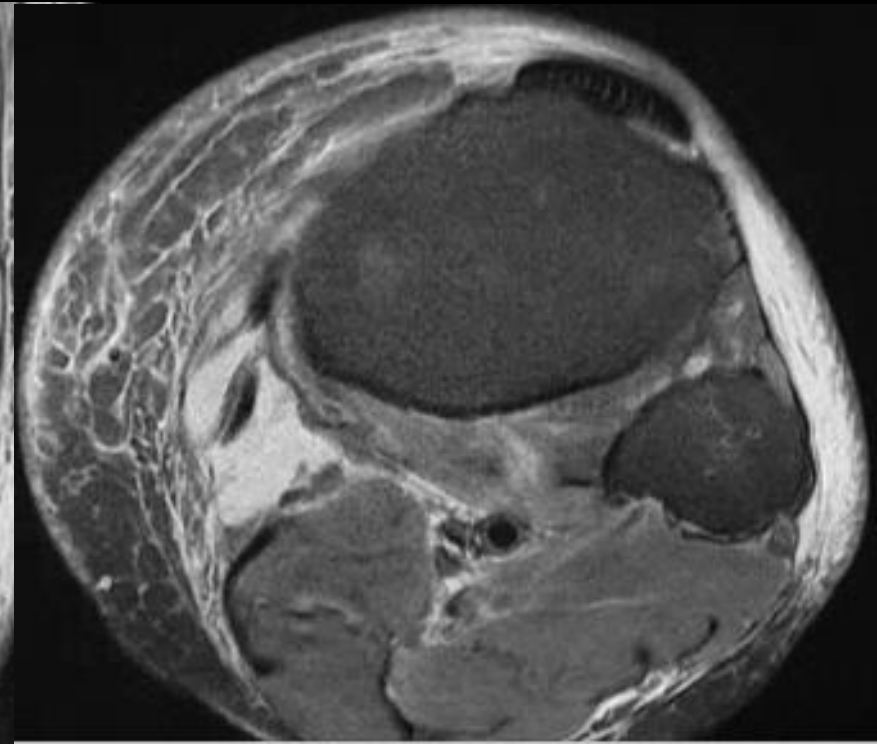
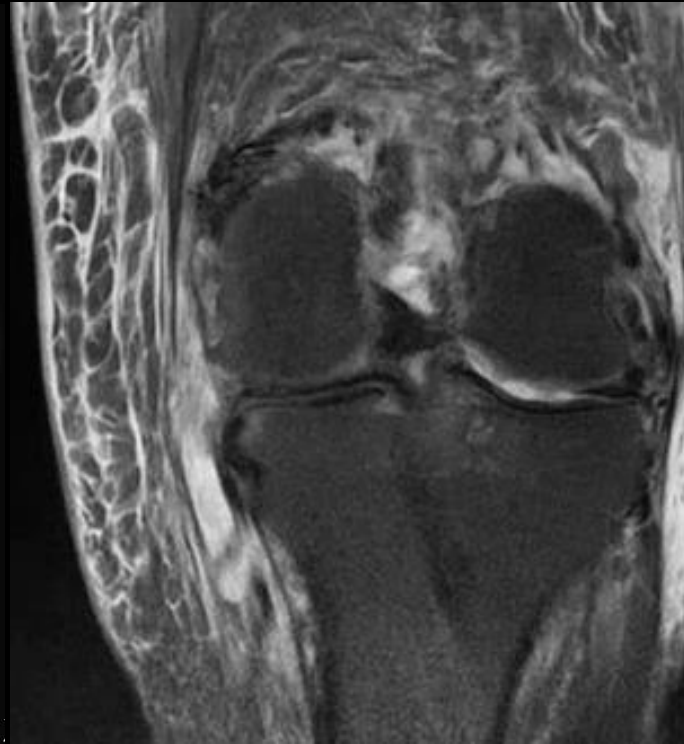
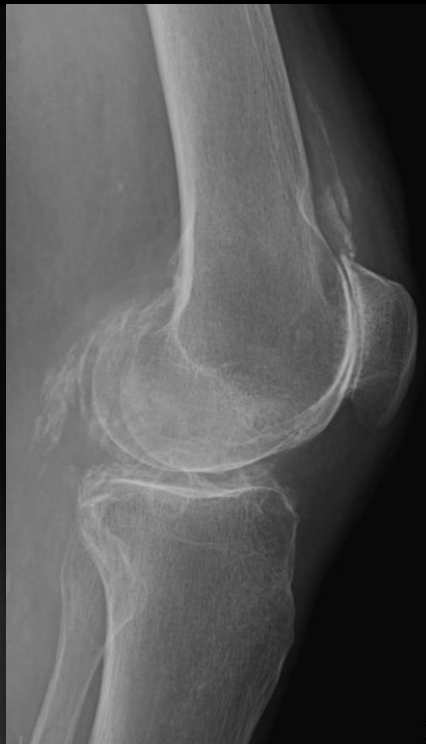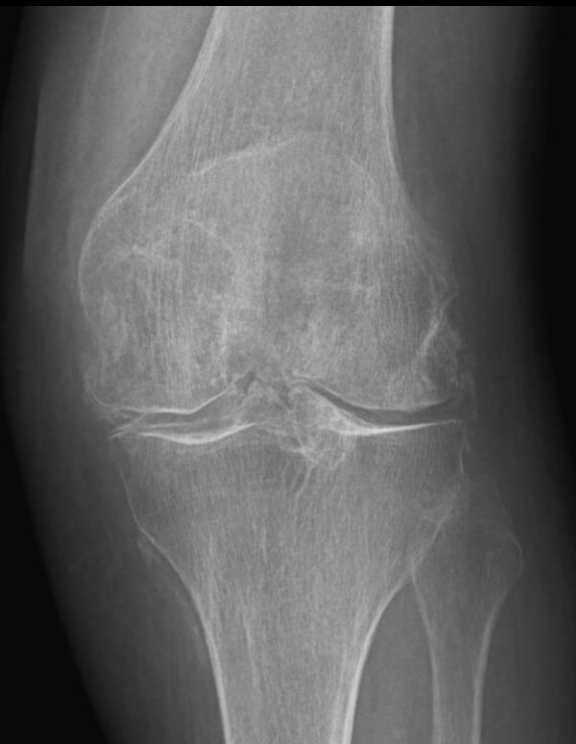- Gout is an uncommon cause of pes anserinus bursitis (asterisks)





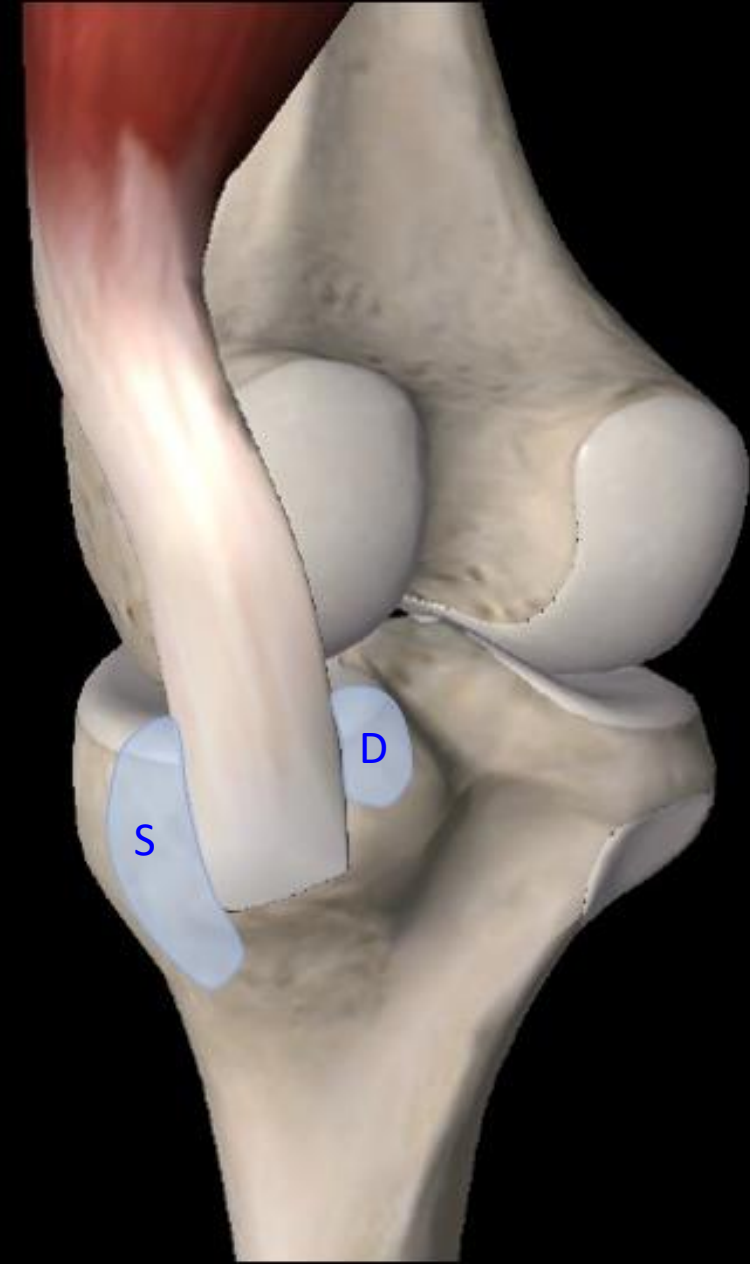
# Crystal deposition at the pes anserinus

- *Calcium pyrophosphate dihydrate deposition*
  - Often in articular cartilage and fibrocartilage (chondrocalcinosis)
  - Can also affect capsular, synovial, tendinous and ligamentous tissues



# Anatomy: semimembranosus (-TCL) bursa

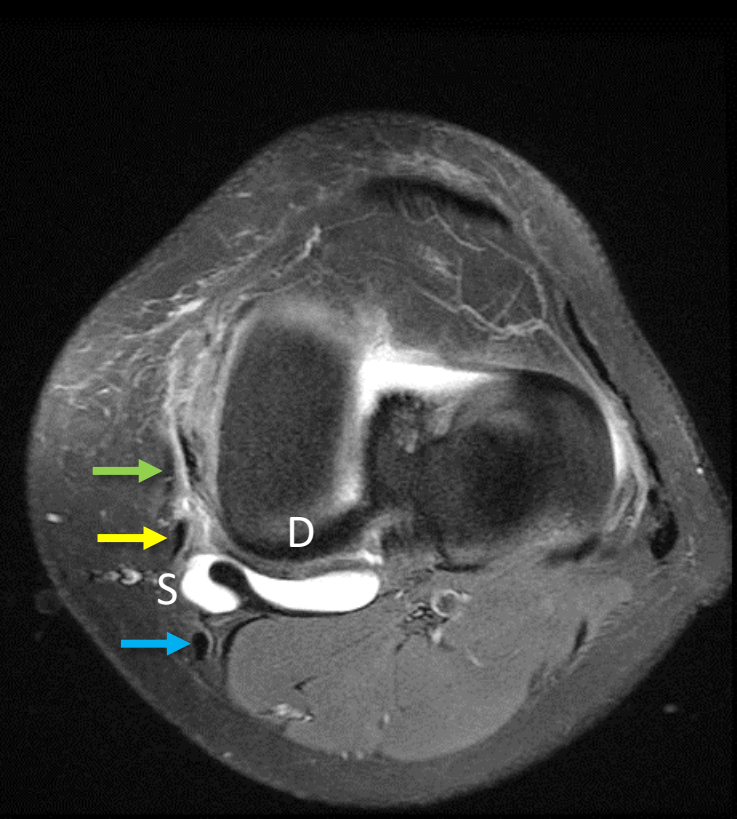
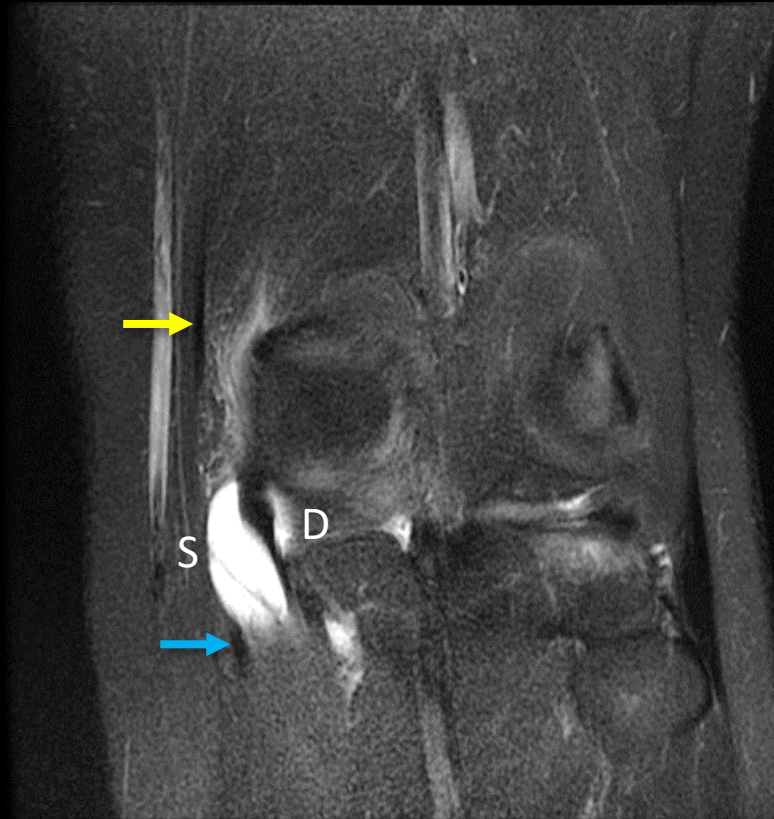
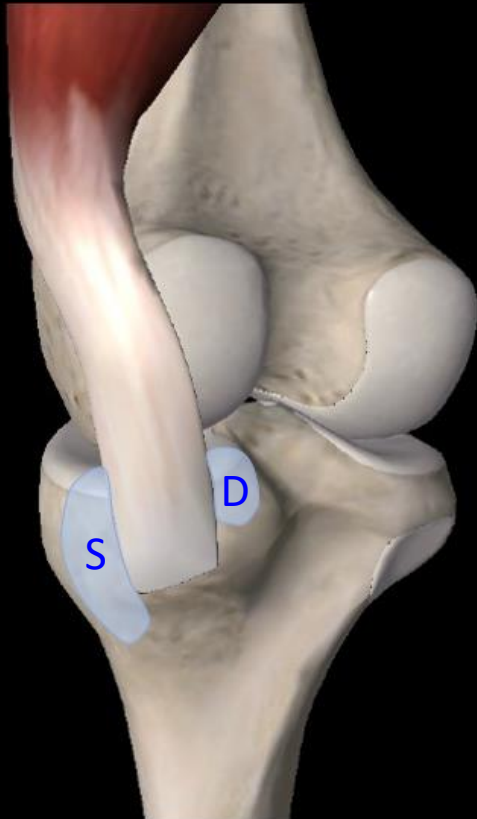
- Characteristic inverted “U” or horseshoe shape formed by two arms
  - Superficial arm (S)
    - Elliptical, between semimembranosus tendon and TCL
  - Deep arm (D)
    - Triangular, between semimembranosus tendon and medial tibial condyle
- Largest average dimensions: 21 mm AP x 10 mm CC



# Medial knee fluid/cystic lesions

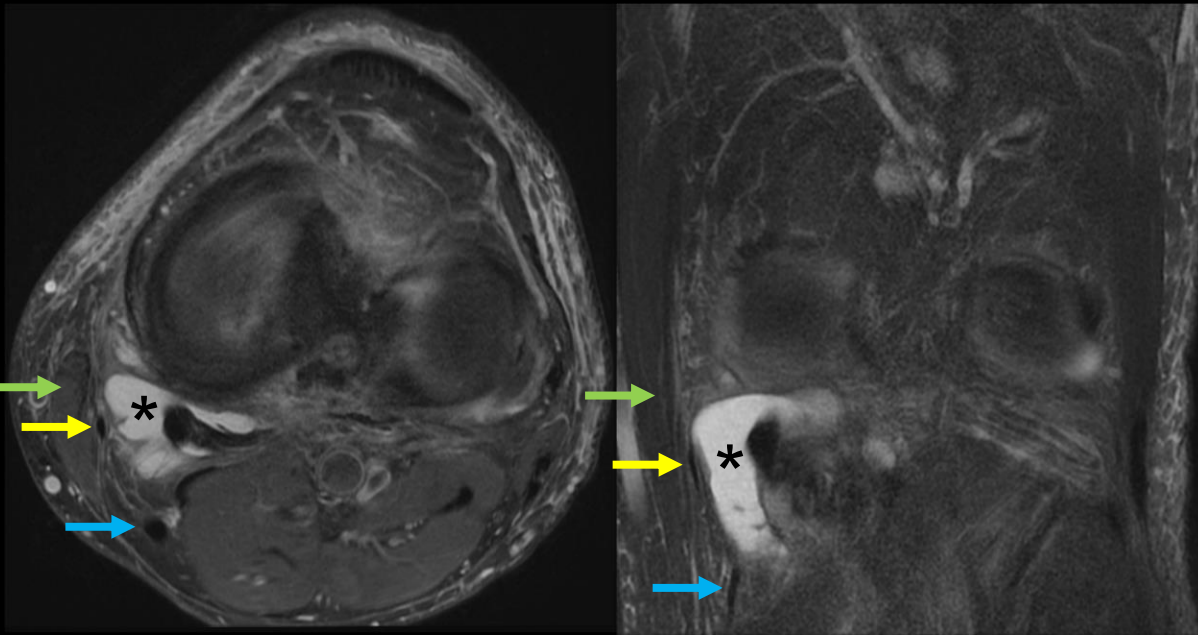
- *Semimembranosus bursitis*
  - Inverted “U”/horseshoe shape as superficial (S) and deep (D) arms surround the semimembranosus tendon

- Sartorius
- Gracilis
- Semitendinosus

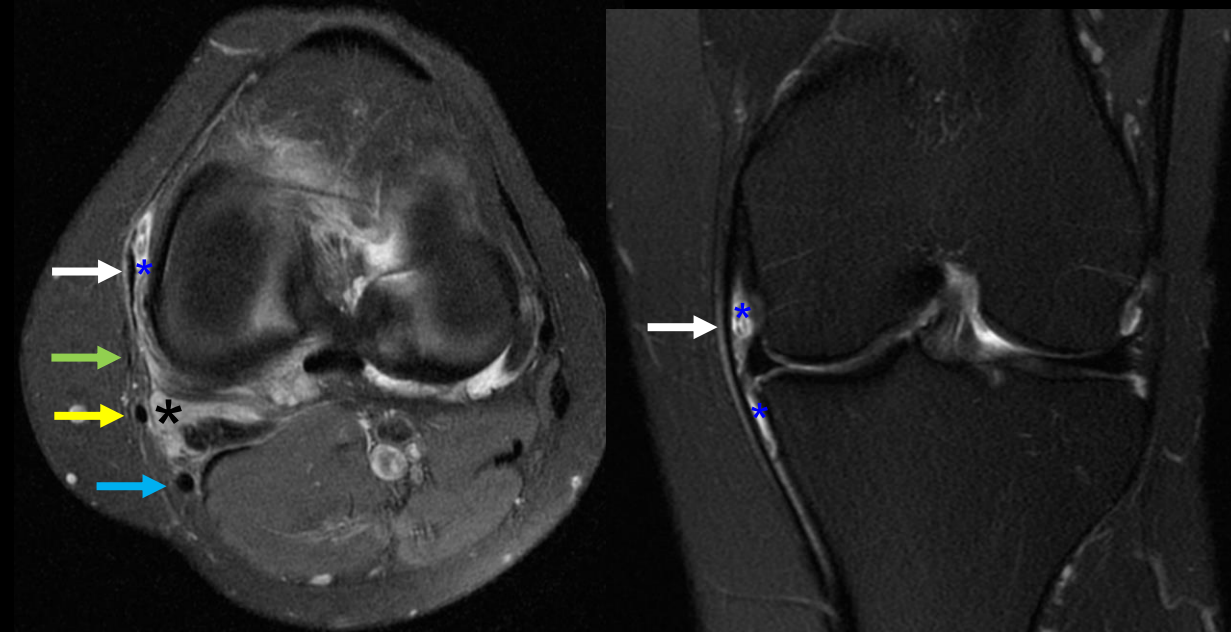


# Medial knee fluid/cystic lesions

- *Semimembranosus bursitis* (black asterisk)
  - Often communicates with the MCL bursa (blue asterisk)



Semimembranosus bursitis in an active patient.

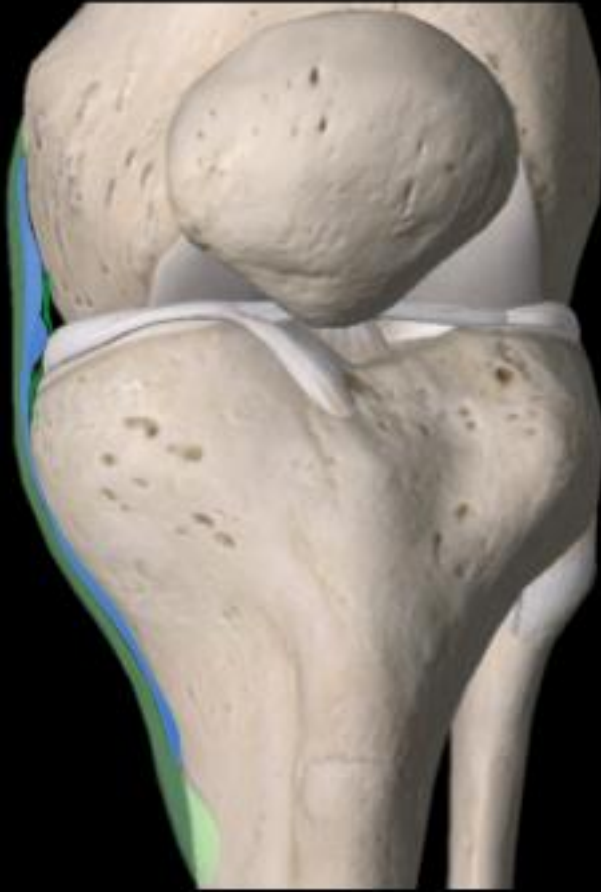

Semimembranosus and MCL bursitis and synovitis in a patient with rheumatoid arthritis.

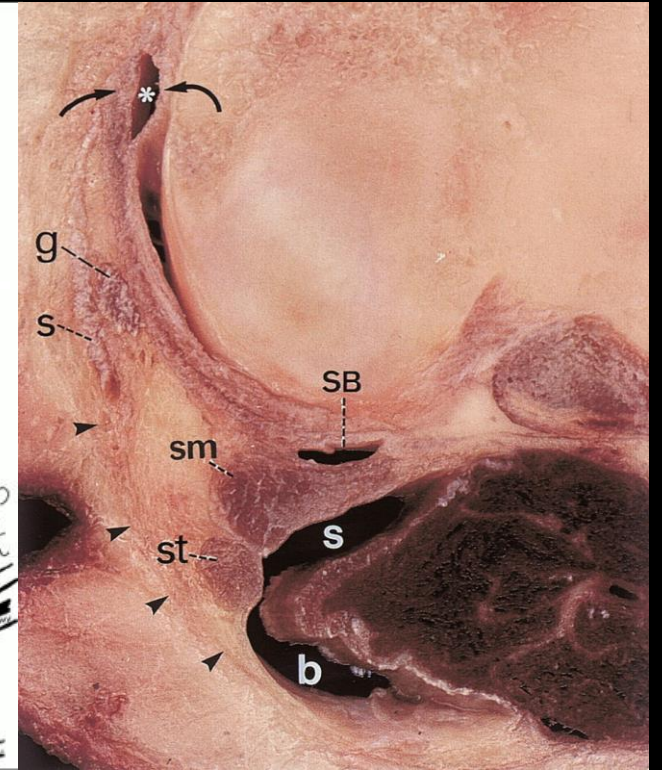
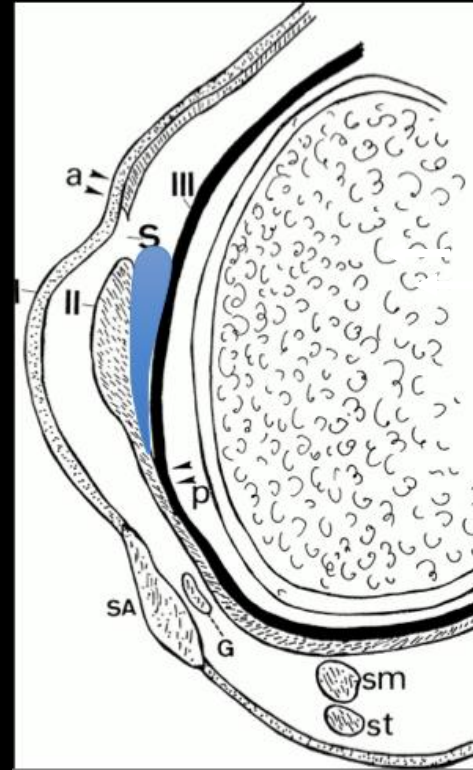
- Sartorius
- Gracilis
- Semitendinosus

# Anatomy: tibial collateral ligament bursa

- Between the superficial and deep MCL
- Meniscomemoral and meniscotibial compartments may or may not communicate
- Anterior border: anterior TCL
- Posterior border: merging of layers 2&3

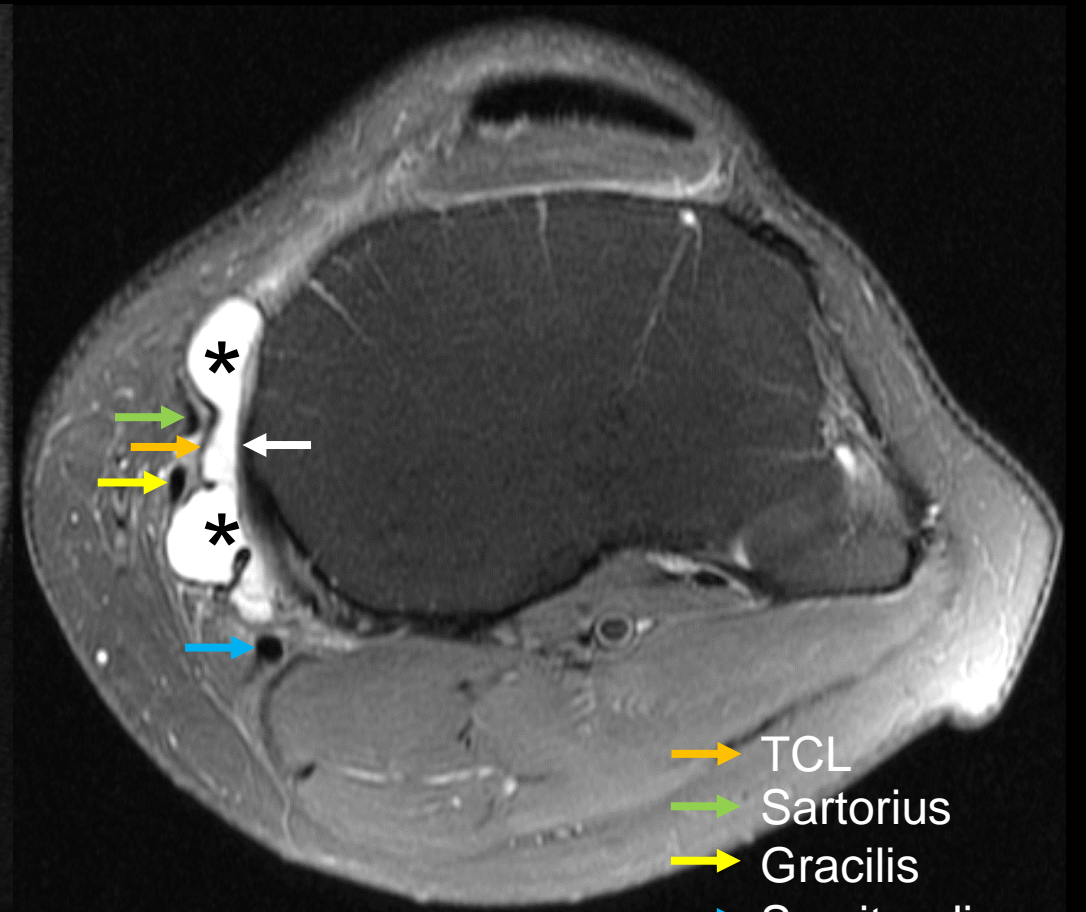
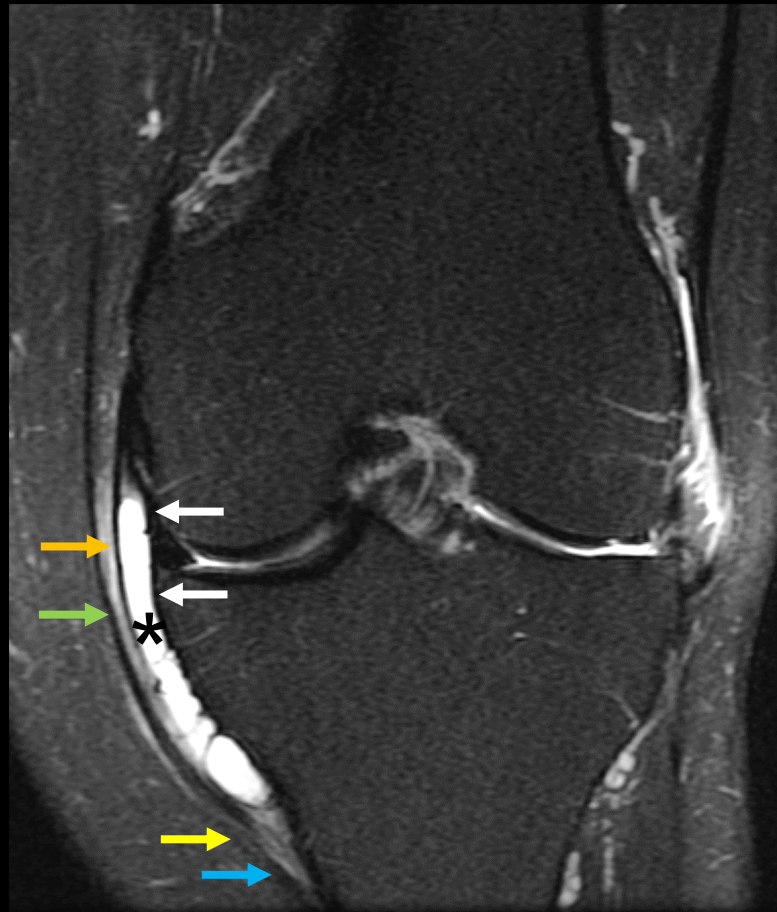
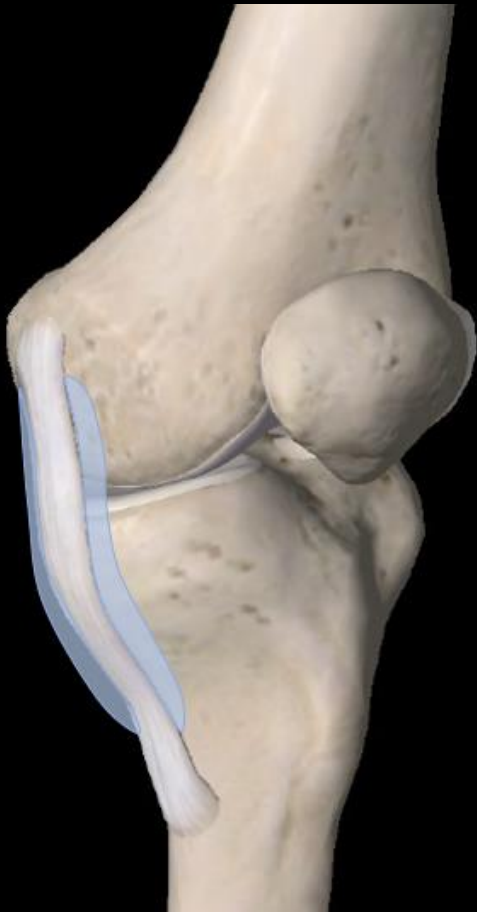
De Maeseneer M. *RadioGraphics* 2000



# Medial knee fluid/cystic lesions

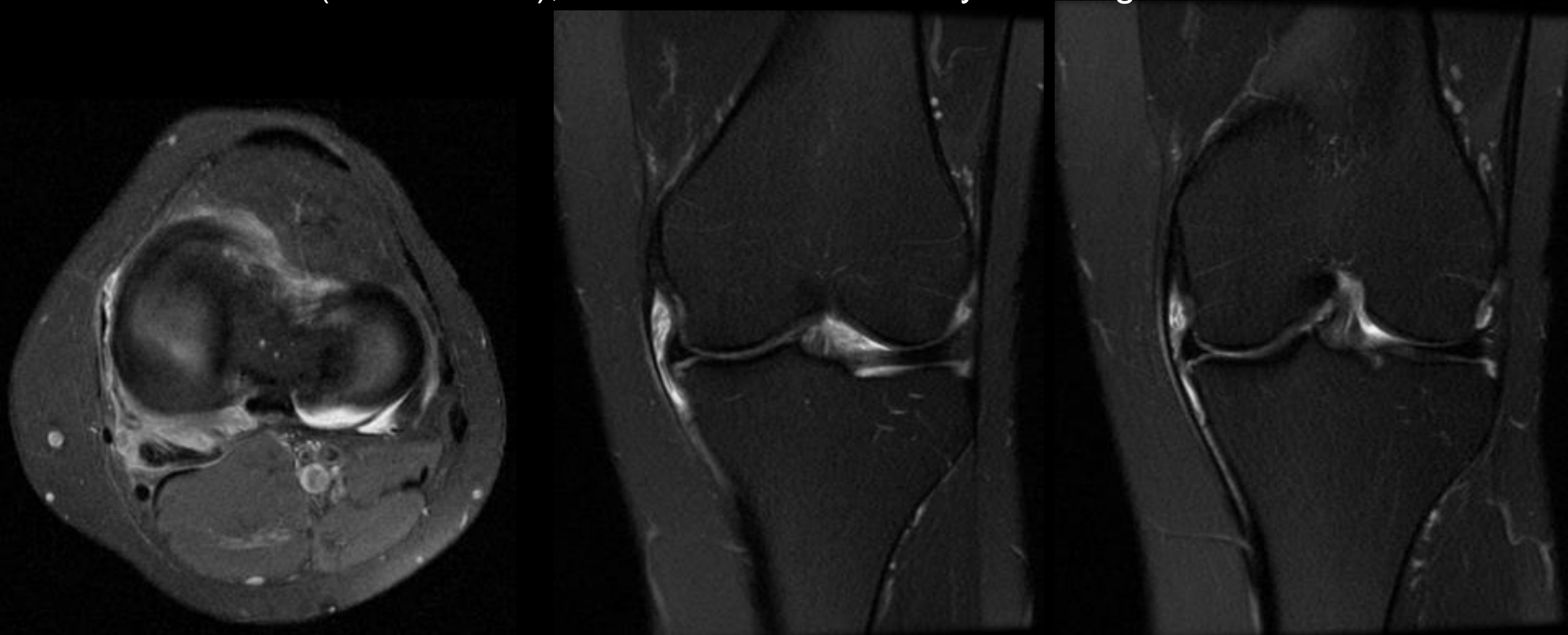
- *TCL bursitis* (black asterisks)
  - Located between the TCL and meniscofemoral and meniscotibial ligaments (white arrows).



- TCL
- Sartorius
- Gracilis
- Semitendinosus

# Medial knee fluid/cystic lesions

- *TCL bursitis*
  - Associated with genu valgum, trauma, osteophytes, flatfoot, rheumatoid arthritis (case shown), horseback and motorcycle riding



# Bursae at the Medial Knee

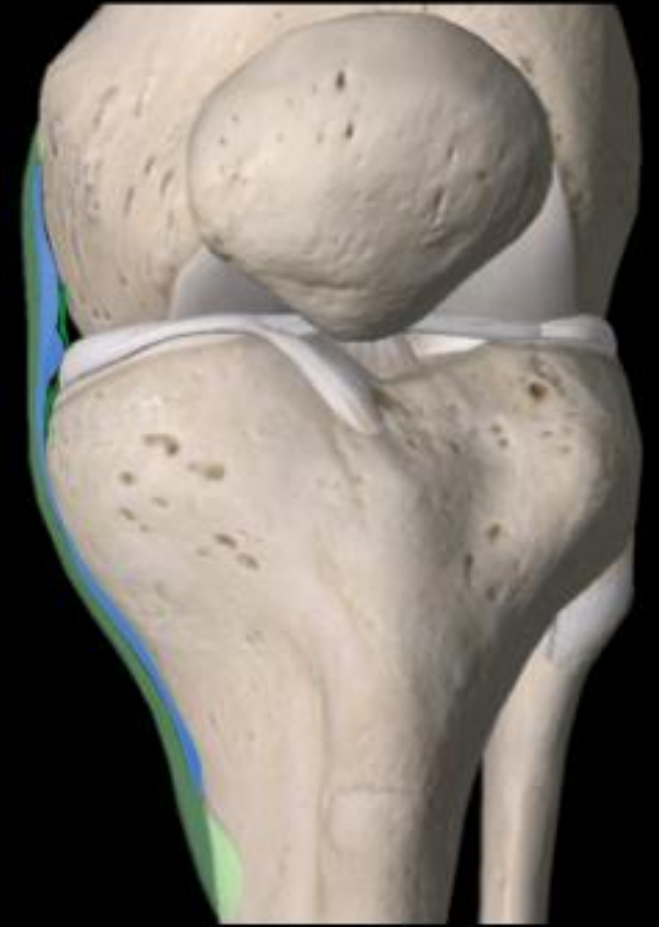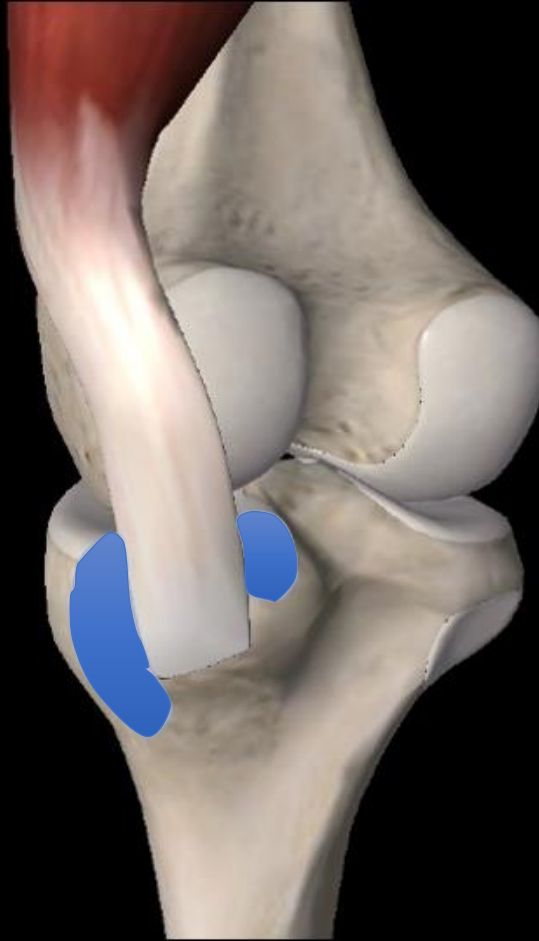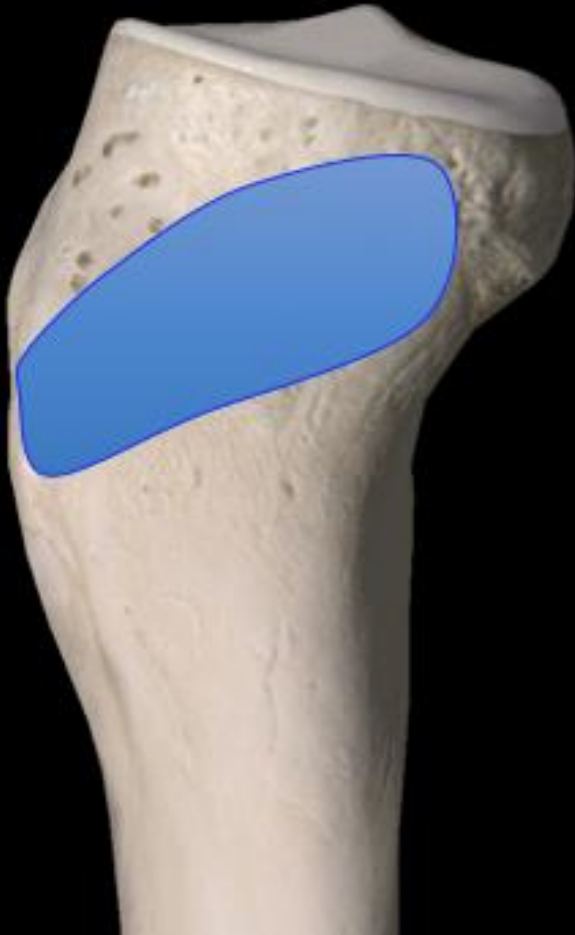- Pes anserine bursa: deep to pes tendons and superficial to TCL

← can communicate →

- Semimembranosus bursa: superficial (s) and deep (d) arms create an inverted “U”

← can communicate →

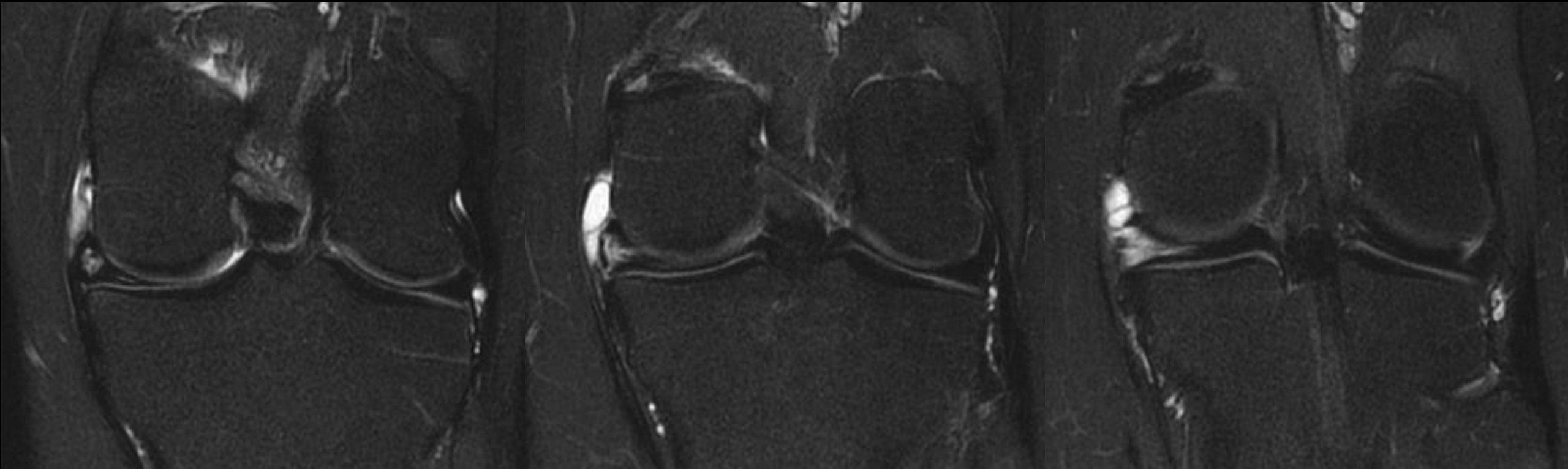
- MCL bursa: between the TCL and deep MCL





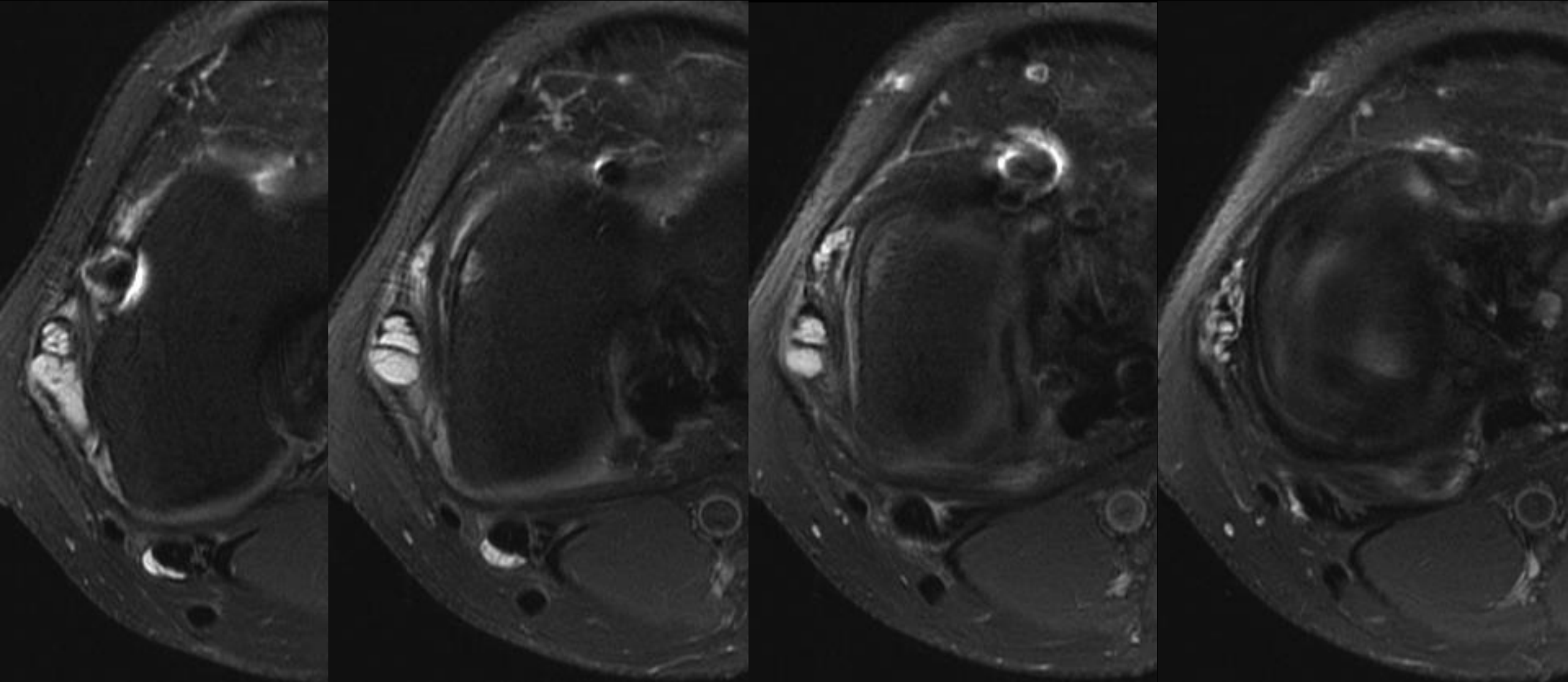
# Medial knee fluid/cystic lesions

- *Parameniscal cyst*
  - Cystic and lobulated with internal septations
  - Connect with a meniscal tear
  - Can be confused with bursitis or other fluid/cystic lesions



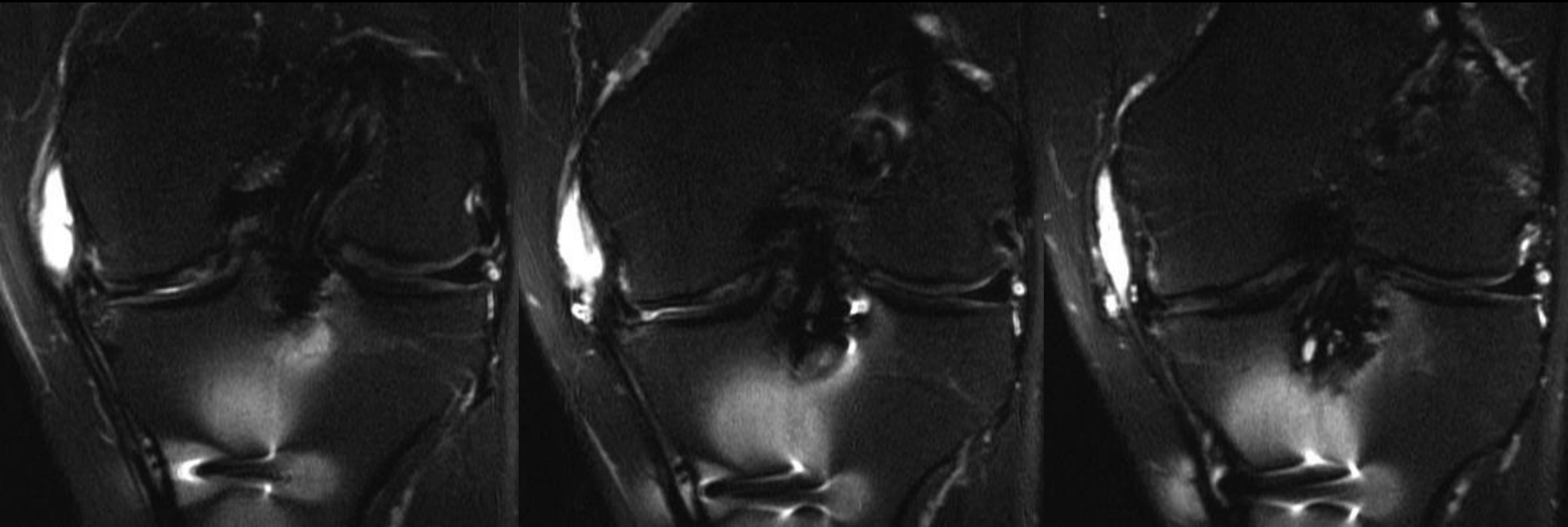
# Medial knee fluid/cystic lesions

- *Parameniscal cyst versus TCL bursitis*



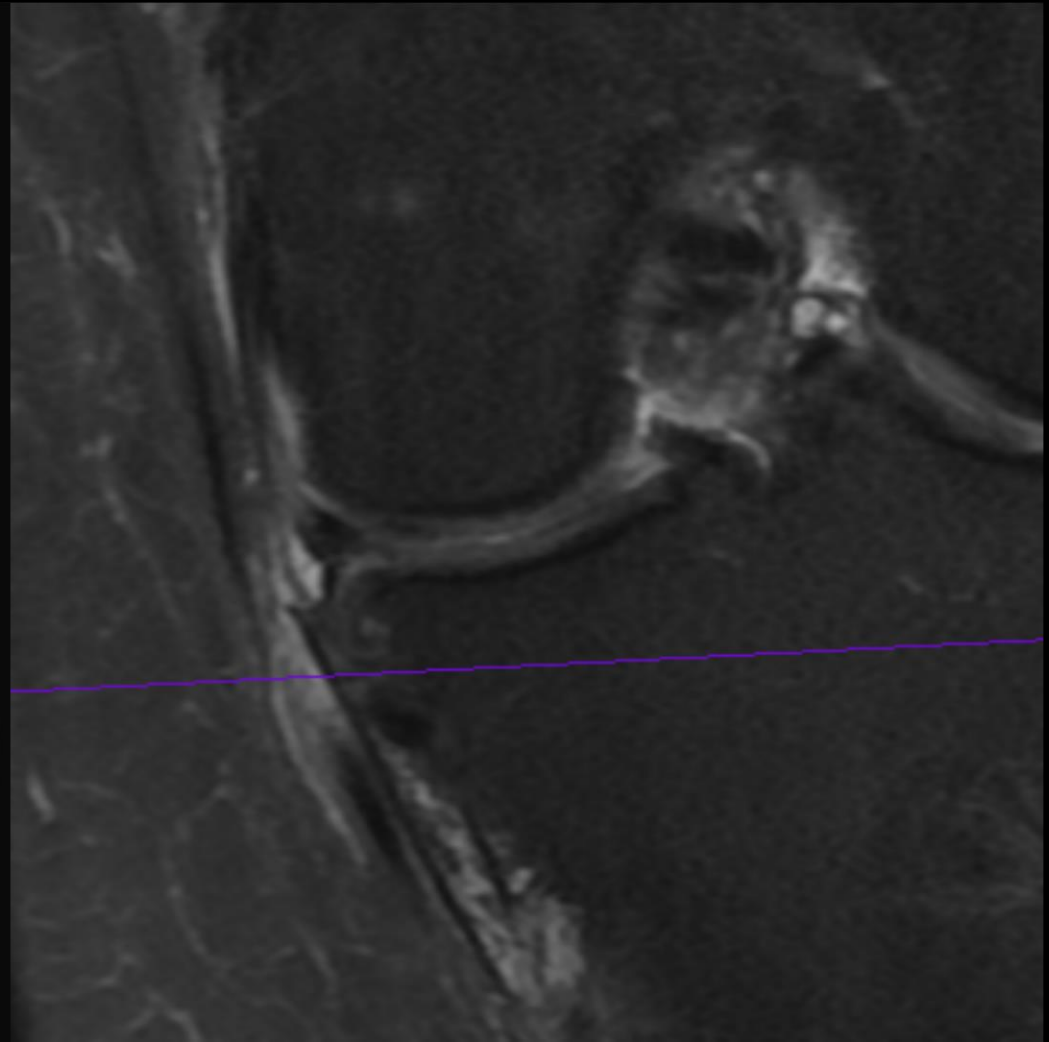
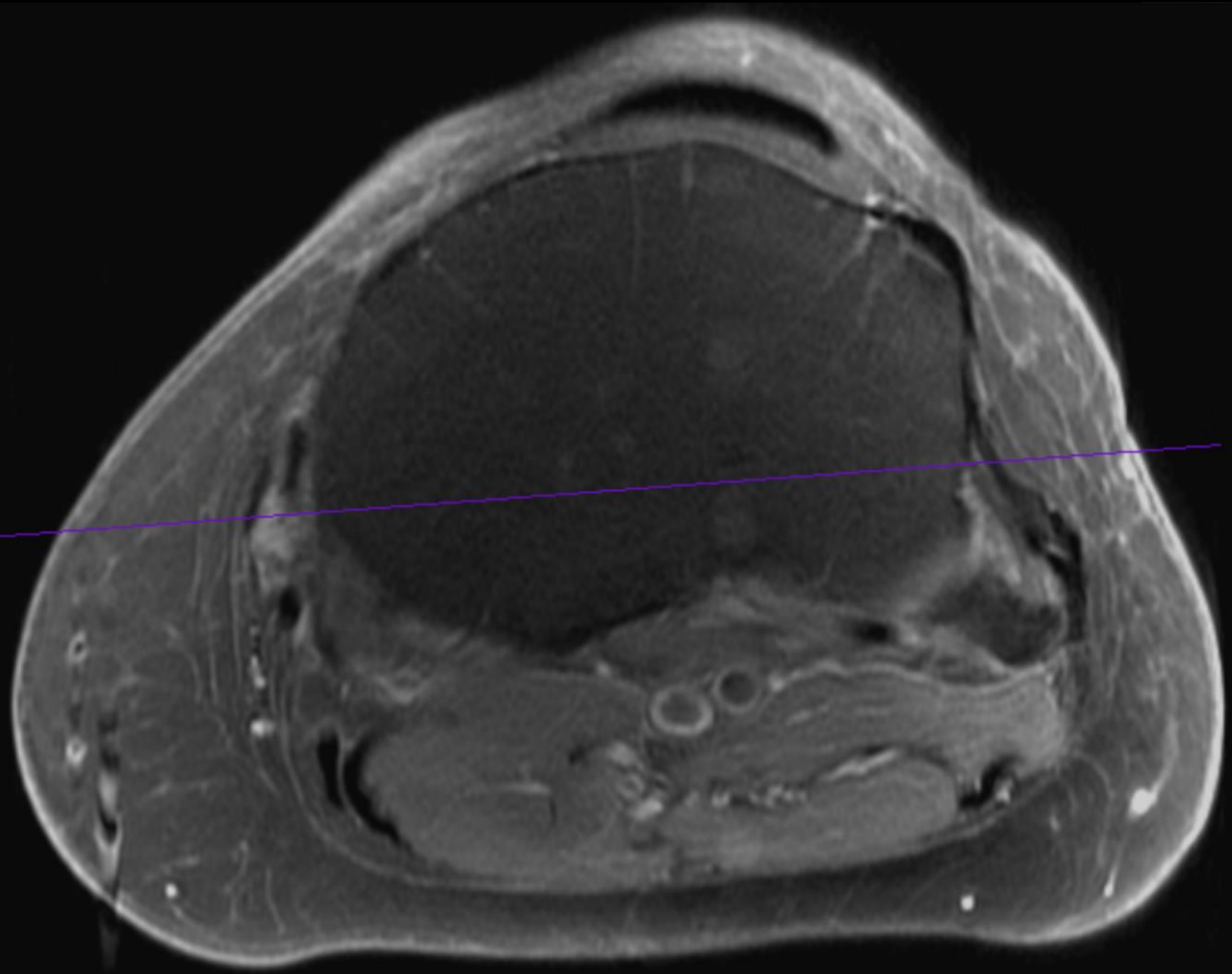
# Medial knee fluid/cystic lesions

- *Parameniscal cyst versus TCL bursitis*



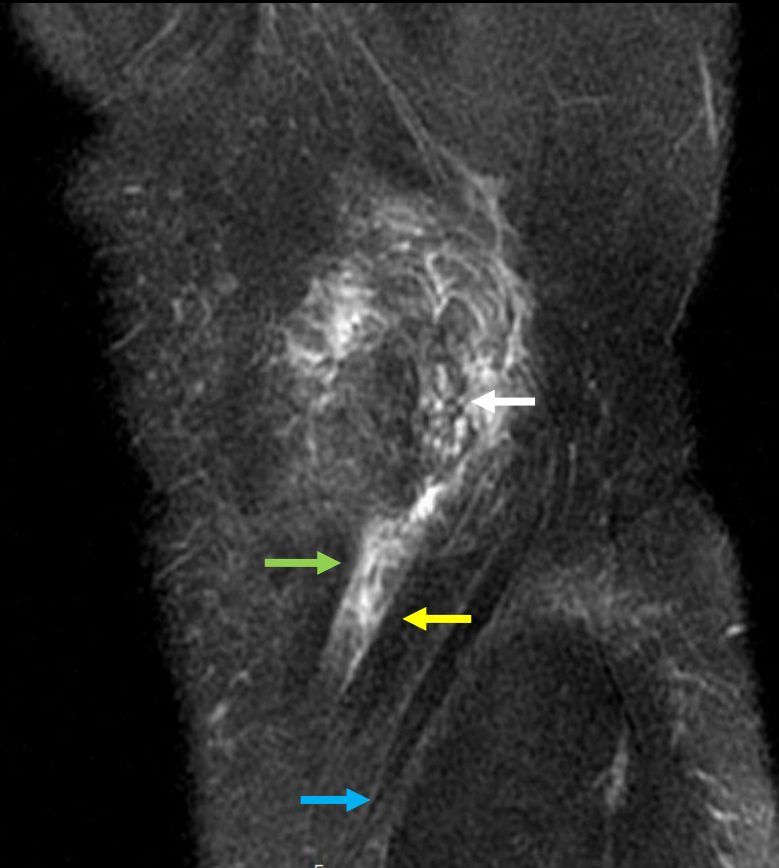
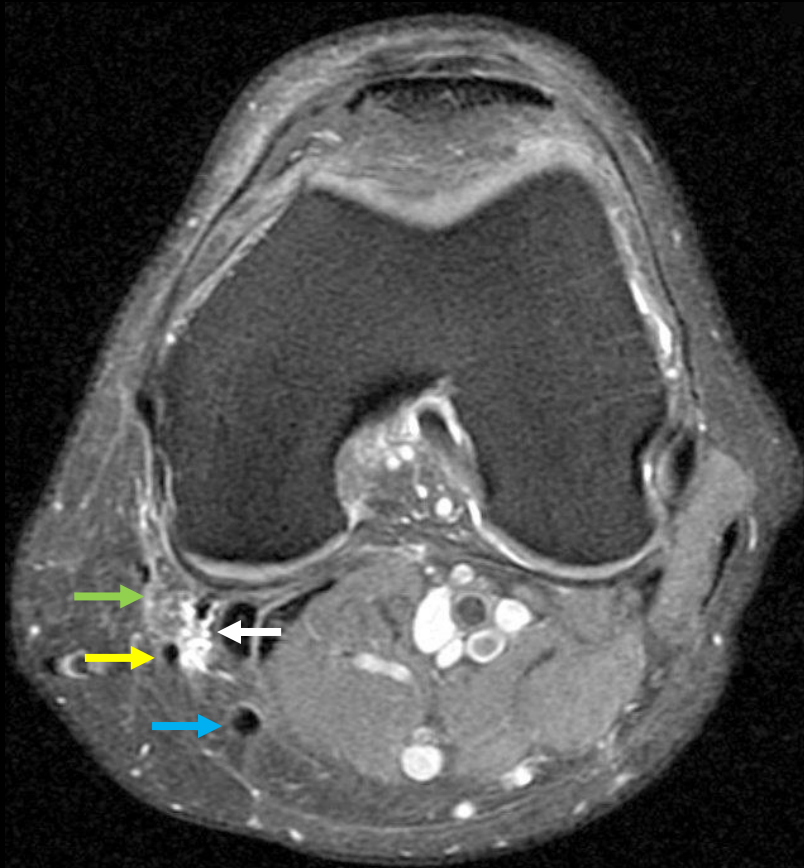
# Medial knee fluid/cystic lesions

- *Parameniscal cyst versus pes anserinus bursitis*



# Medial knee fluid/cystic lesions

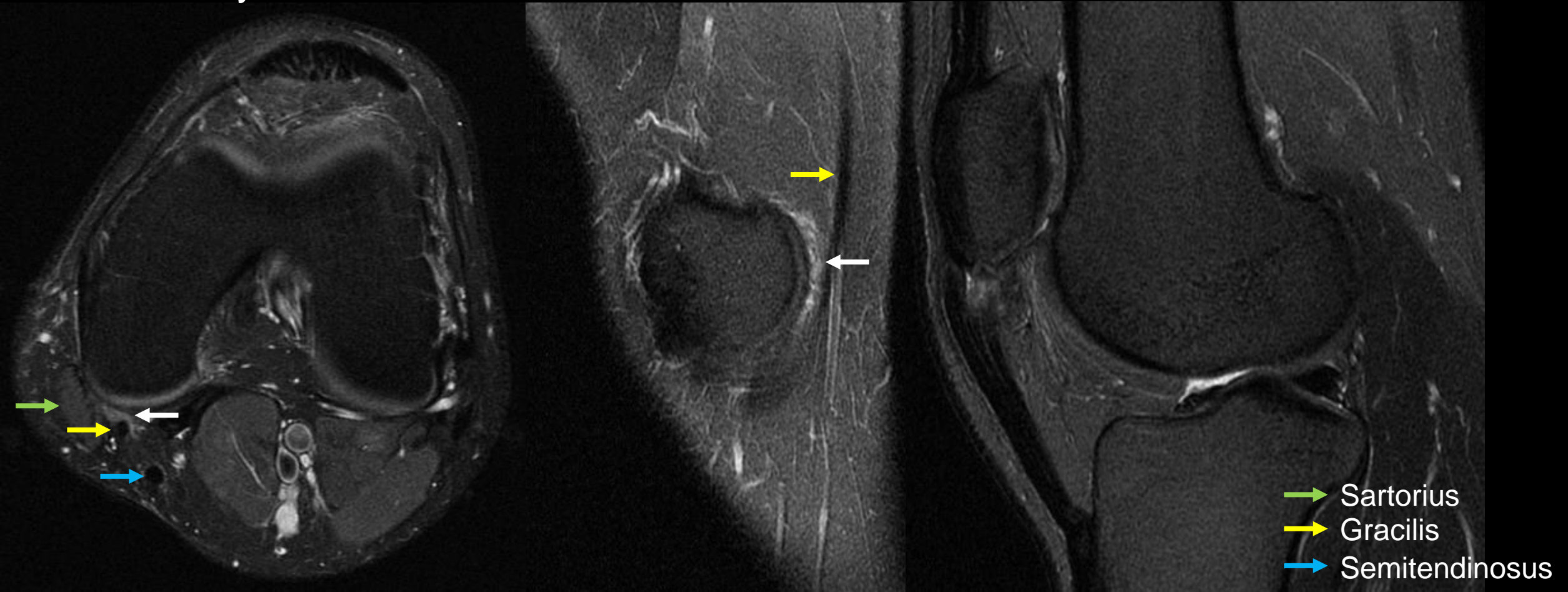
- *Posteromedial knee friction syndrome*
  - Simeone FJ. *Skeletal Radiology* 2015
    - Suggest friction between the femoral condyle, sartorius and/or gracilis tendons as a cause of medial knee pain



- Sartorius
- Gracilis
- Semitendinosus

# Medial knee fluid/cystic lesions

- *Posteromedial knee friction syndrome*
  - Friction between the femoral condyle, sartorius and/or gracilis tendons may cause medial knee pain in active patients
  - May be associated with less distance between the tendons and bone

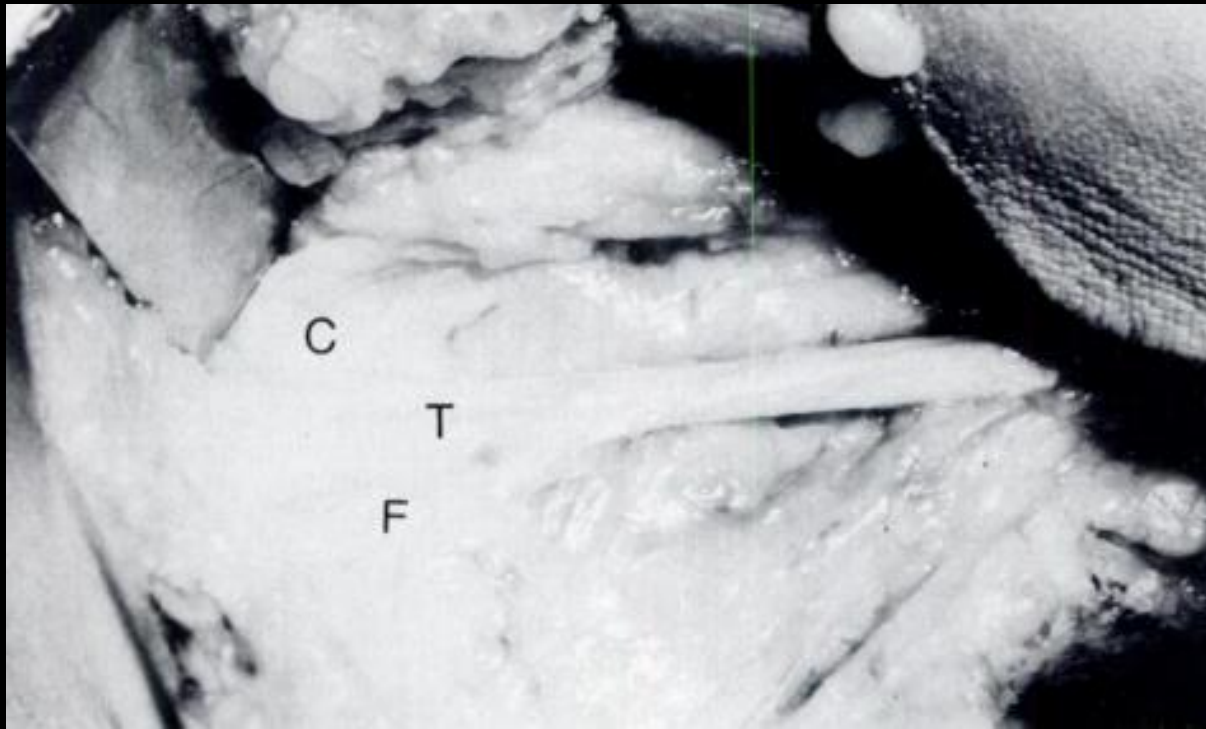


# Pes anserine snapping syndrome

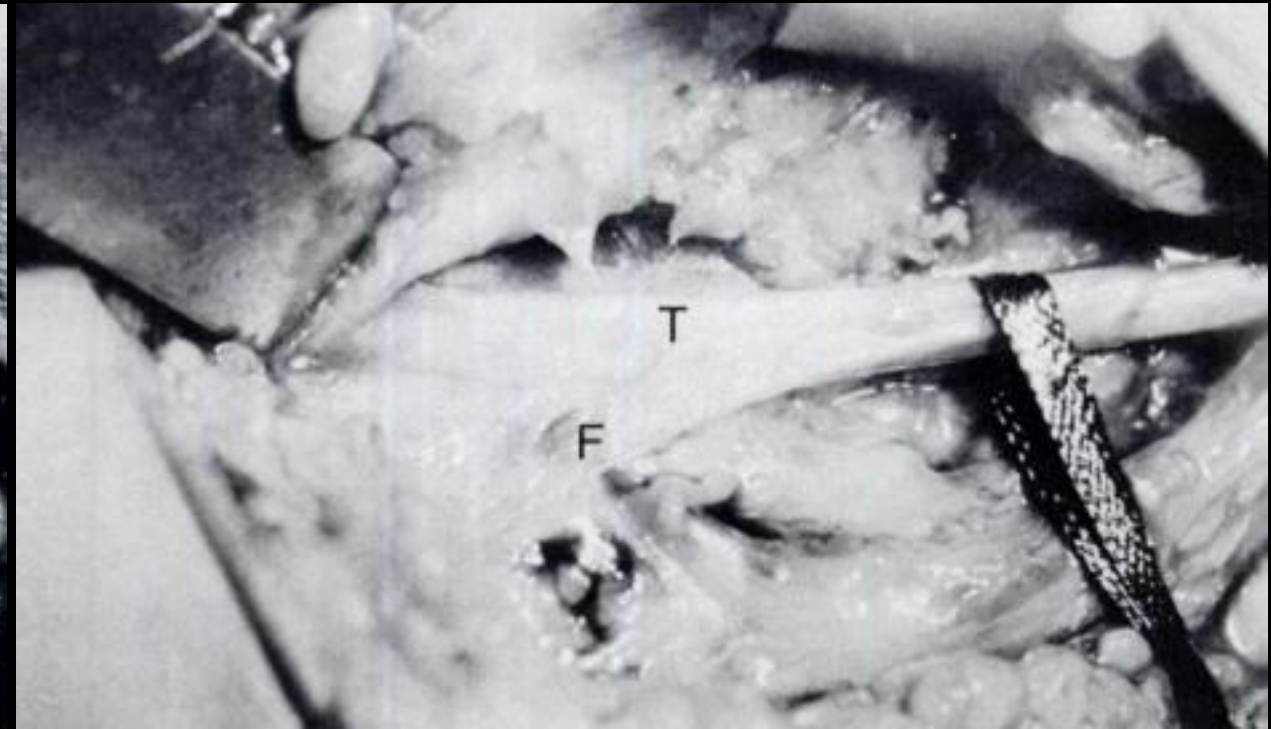
- Semitendinosus and/or gracilis tendons snapping at the medial knee
- Snapping occurs over the tibial condyle or semimembranosus
- May be associated with fewer/weaker accessory bands
- Tendon release has been performed in small case series

Lyu SR. *JBS* 1989

Flexion

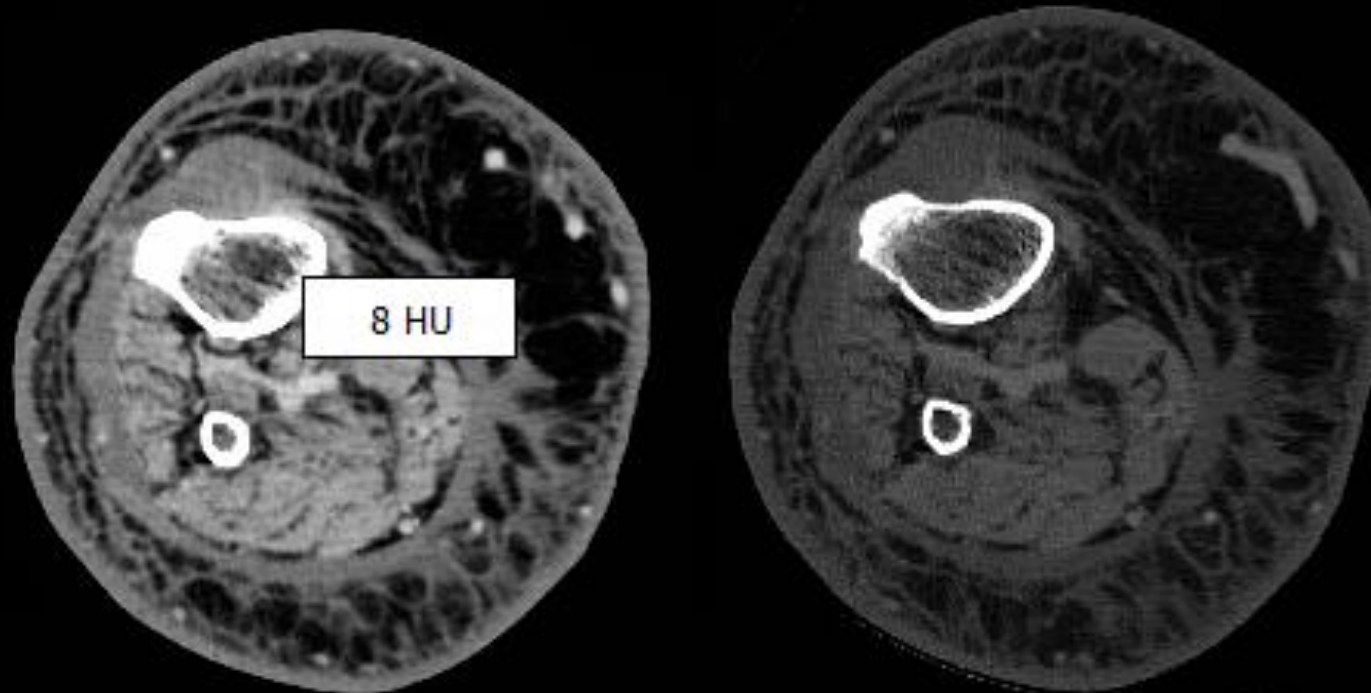


Extension



# Medial knee fluid/cystic lesions

- *Periosteal ganglion cyst*
  - Ollier (1864) and Poncet (1874) described “periostitis aluminosa” and “ganglion periostale”-mucinous fluid below the periosteum
  - May arise by mucoid degeneration of fibrous periosteum in tubular bone
  - Often at proximal tibia near pes anserinus
  - Ddx: periosteal chondroma, myxoma, nerve sheath tumor



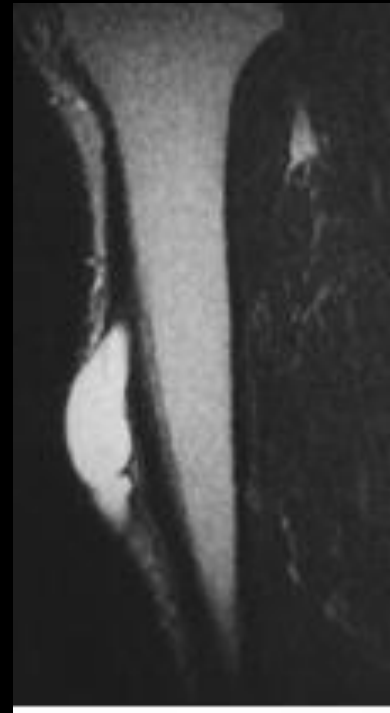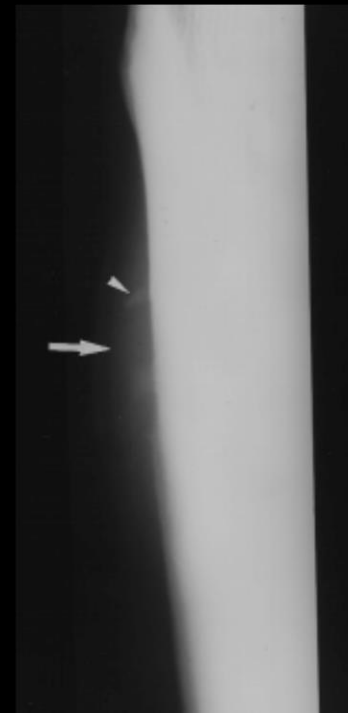

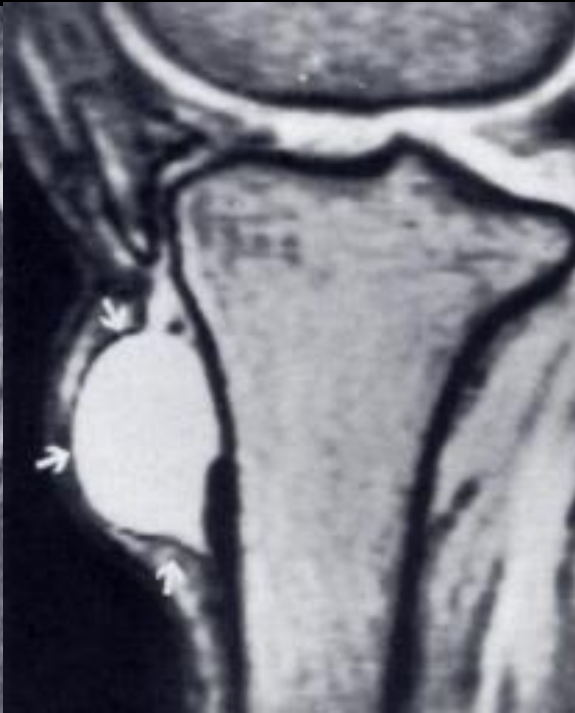
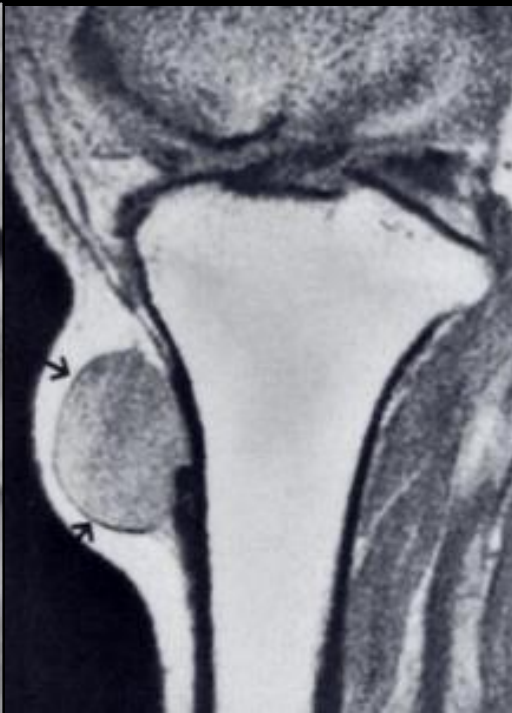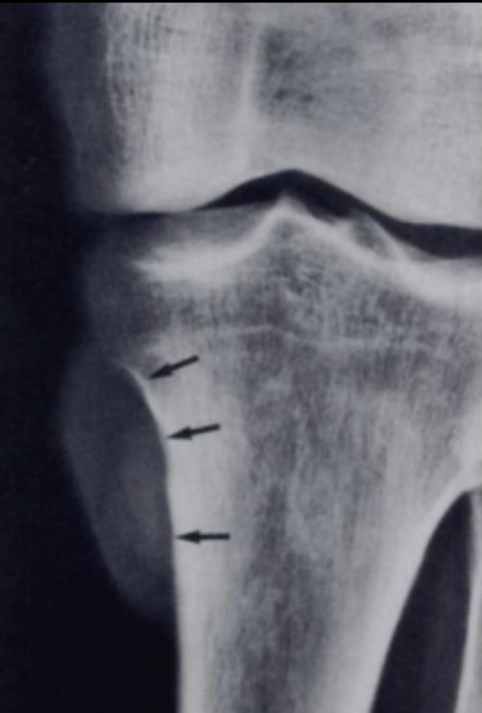# Medial knee fluid/cystic lesions

- *Periosteal ganglion cyst*
  - Additional sites: medial malleolus, distal shafts of radius, ulna and femur
  - Imaging
    - Cystic lesion
    - Cortical scalloping with sclerotic margin
    - Thick reactive periosteal bone spicules

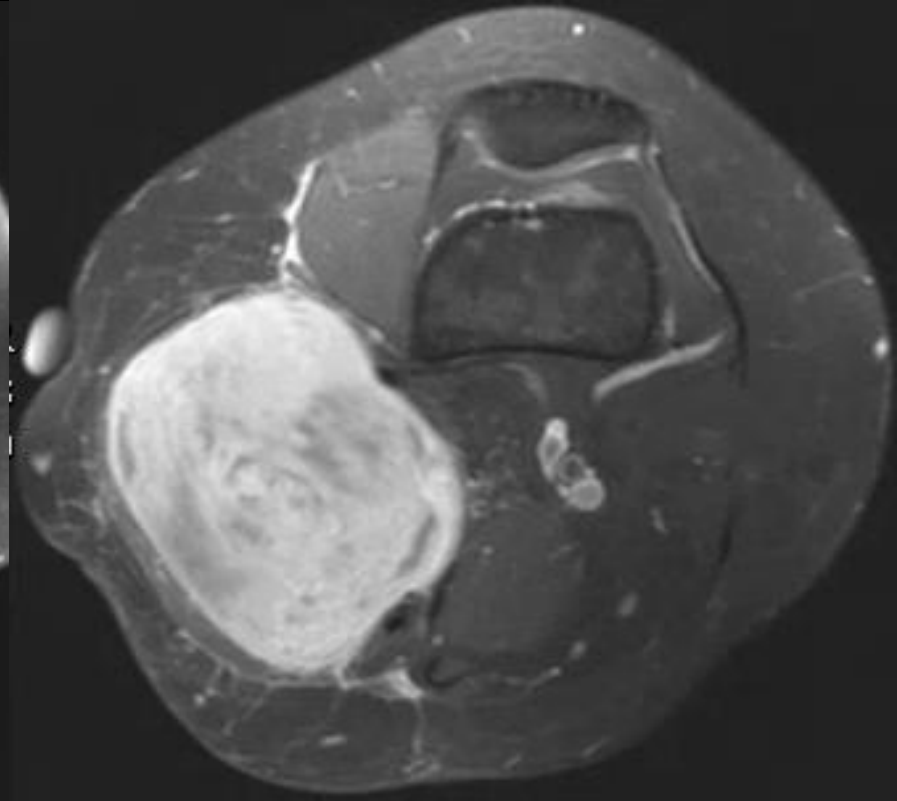
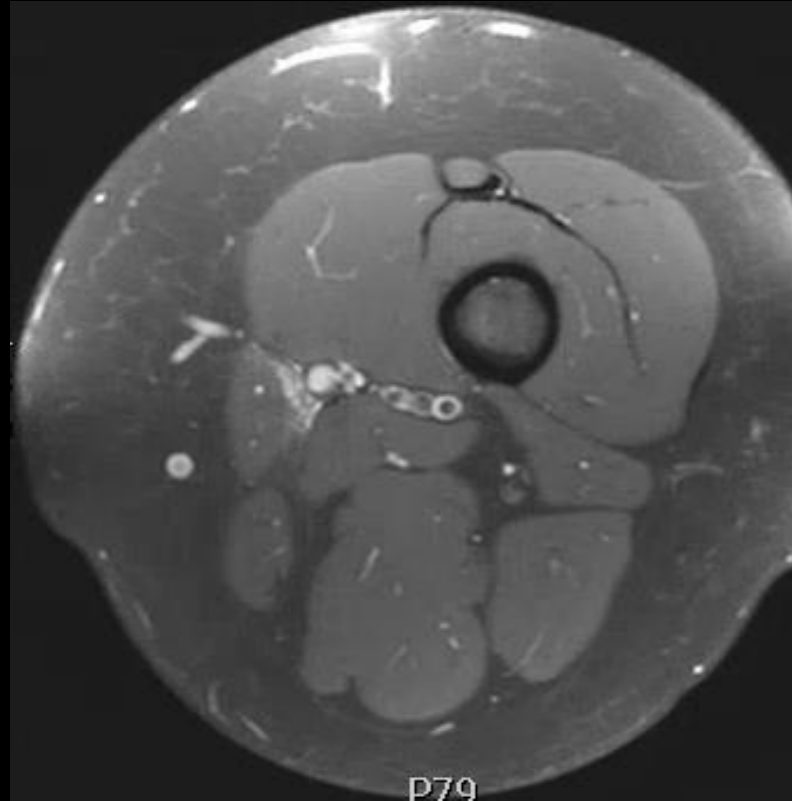
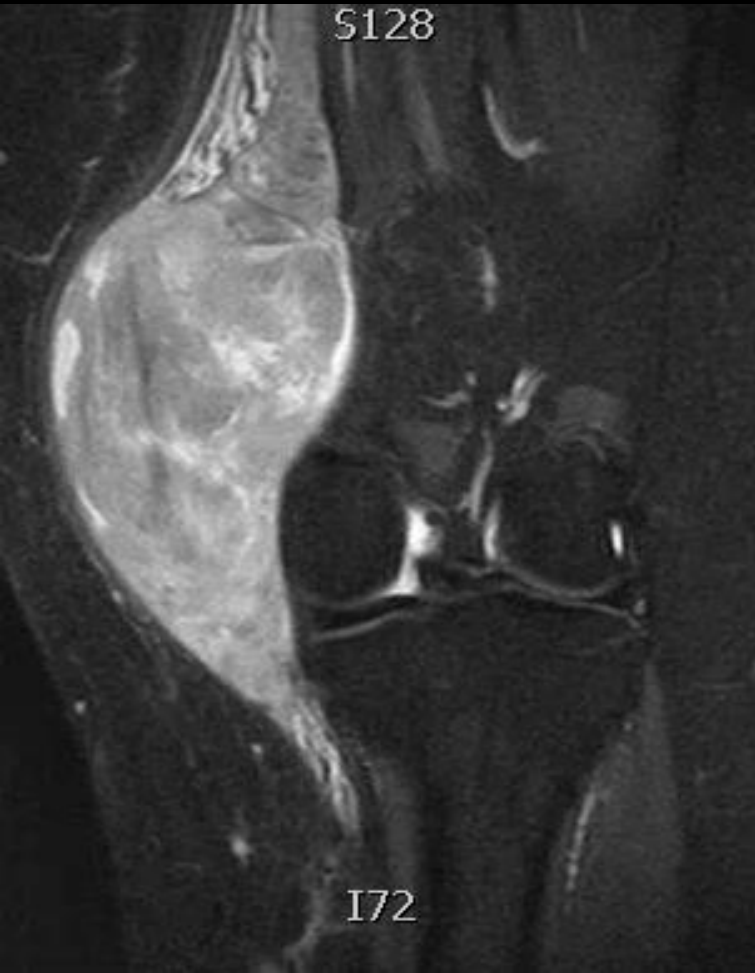Abdelwahab IF. *Radiology* 1993

Valls R. *Eur. Radiol.* 1997



# Medial knee fluid/cystic lesions

- *Peripheral nerve sheath tumor*
  - Saphenous nerve courses deep to sartorius at the knee
  - PNST can arise from the saphenous nerve



# Pes anserinus: cystic pathologies

<b>MEDIAL KNEE FLUID/CYSTIC LESIONS</b>
Pes anserinus bursitis
Semimembranosus bursitis
Medial collateral ligament bursitis
Parameniscal cyst
Cystic tumors
Posteromedial friction syndrome

- A sound anatomic understanding of the medial knee usually allows differentiation these entities

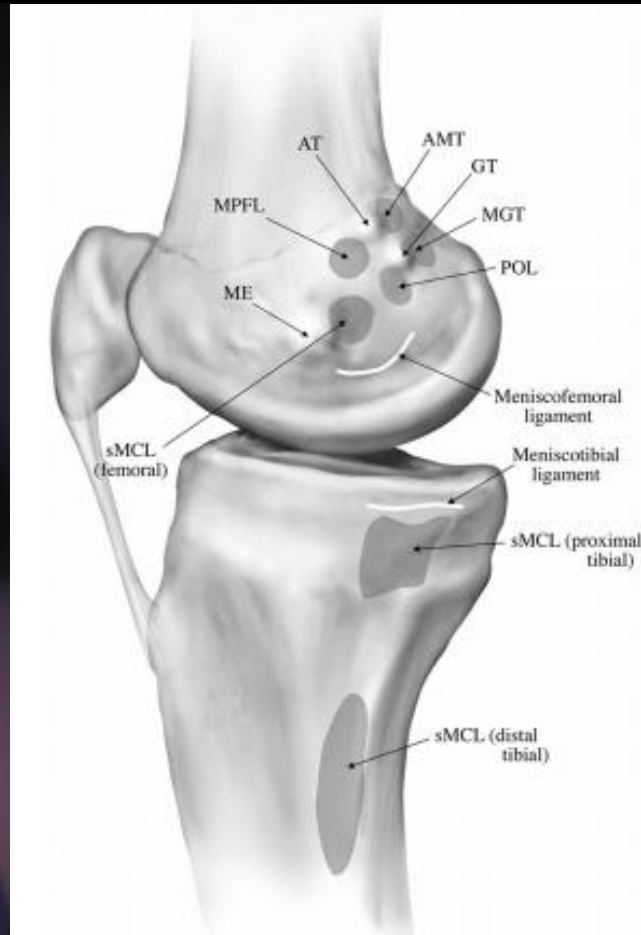
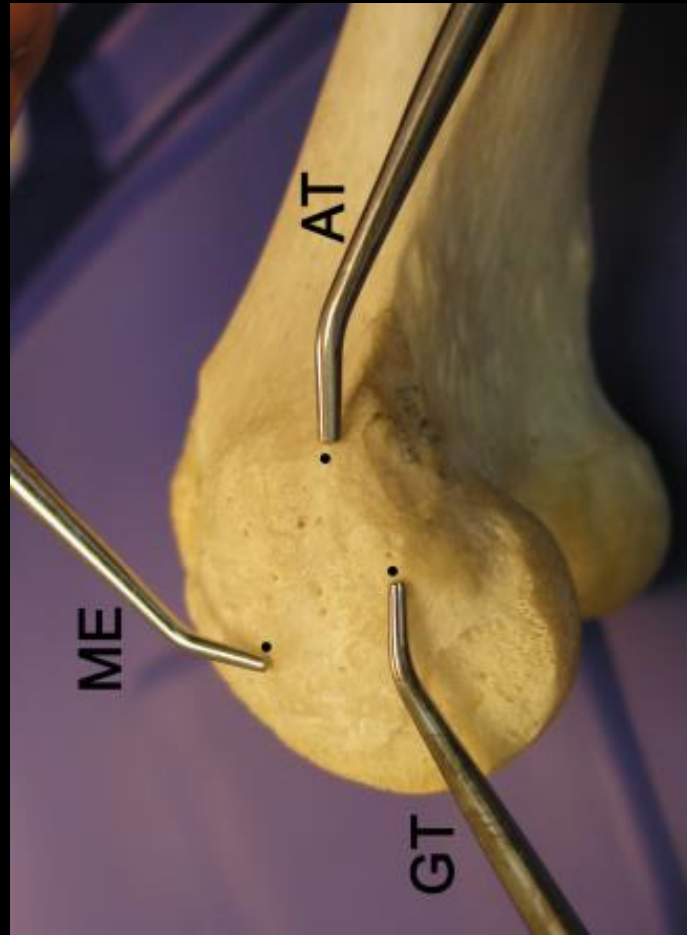


# Trauma: valgus knee stabilizers

- Ligamentous valgus stabilizers
  - MCL and POL anatomy
  - Clinical grading of valgus injuries
  - MRI of TCL injuries
    - Pseudotear
    - Proximal tears
    - Distal TCL tears
- Pes anserinus
  - Myotendinous injury
    - Sartorius injuries
    - Semitendinosus injuries
    - Multiple pes tendon injuries often associated with major ligamentous trauma

# Medial knee osseous landmarks

- Three bony landmarks
  - medial epicondyle
  - adductor tubercle
  - gastrocnemius tubercle

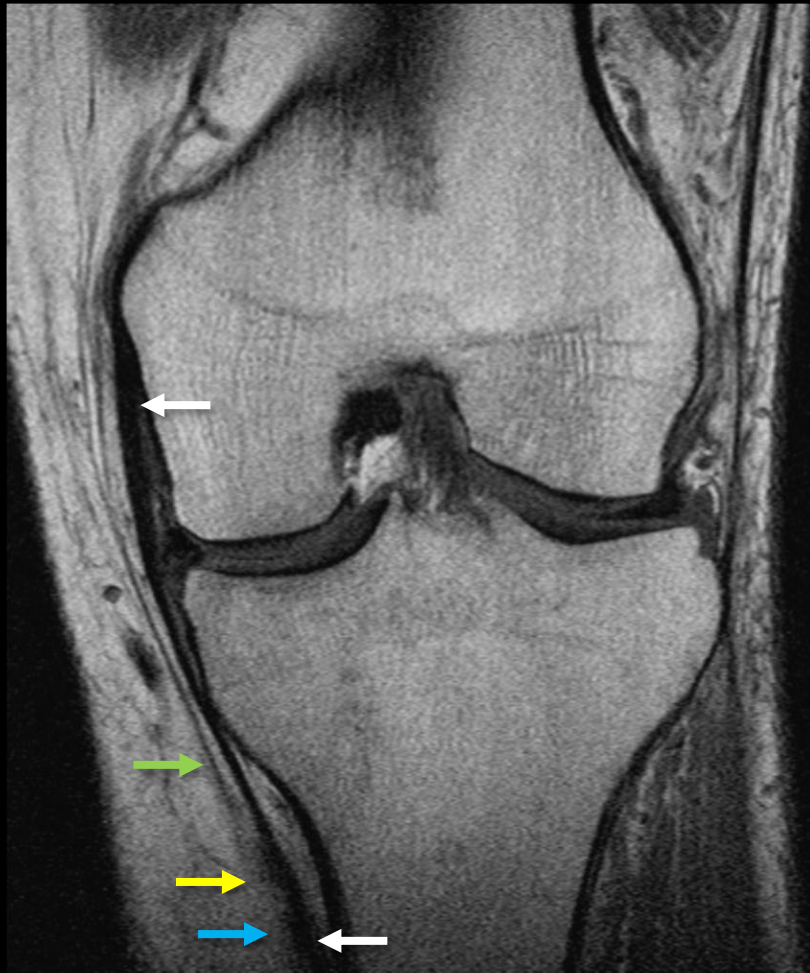

# Tibial collateral ligament

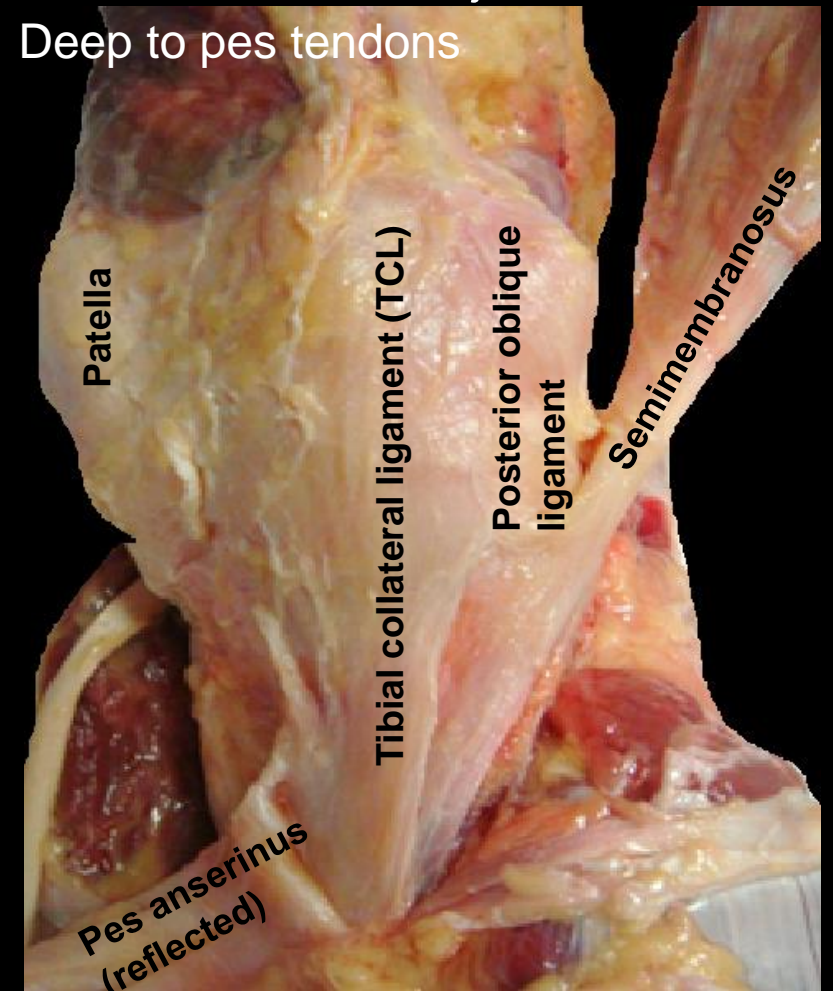
Failure at 557 N

Wijdicks CA. *Am J Sports Med* 2010

- *Origin:*
  - 3-4 mm proximal and posterior to the medial epicondyle



- *Insertion:*
  - 1: Soft tissue 12 mm below joint line to anterior arm semimembranosus
  - 2: Tibia ~60 mm below joint line
    - Deep to pes tendons



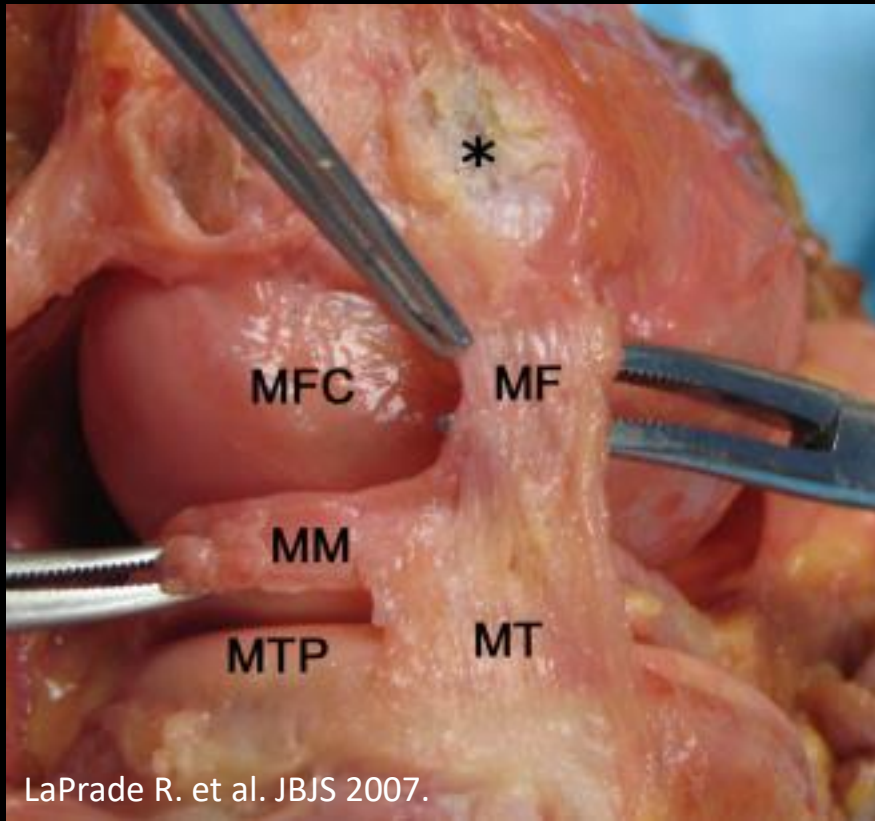
# Deep medial collateral ligament

Failure at 101 N

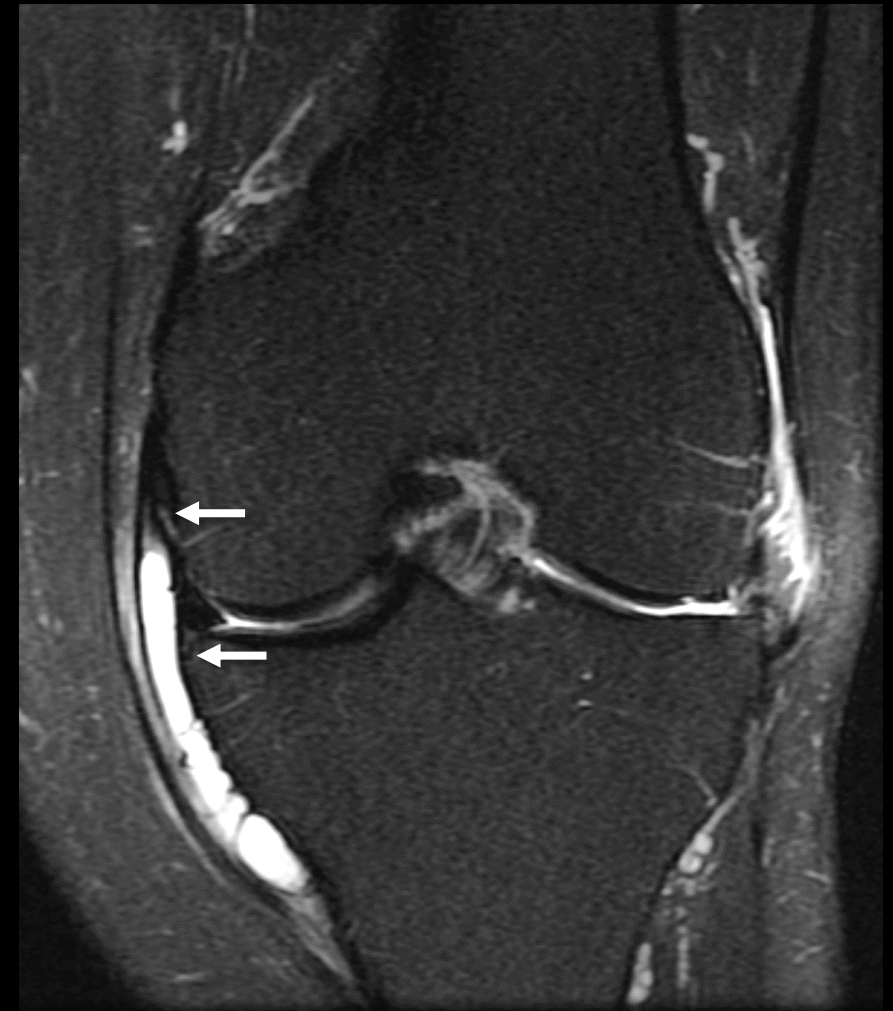Wijdicks CA. *Am J Sports Med* 2010

- Two bands of thickened capsular tissue
  - *Meniscomfemoral ligament*: longer, attaches distal and deep to TCL origin
  - *Meniscotibial ligament*: shorter and thicker, attaches distal to tibial cartilage

- Blends posteriorly with the capsular arm of the posterior oblique ligament



LaPrade R. et al. *JBSJ* 2007.



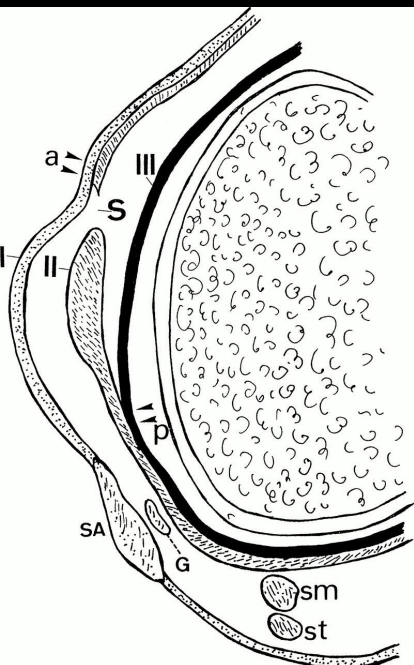


# Posterior oblique ligament

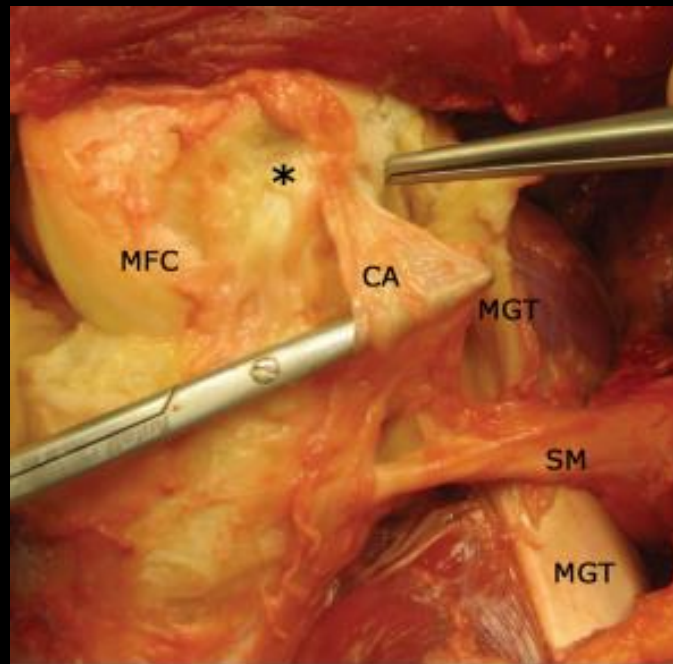
Failure at 256 N

Wijdicks CA. *Am J Sports Med* 2010

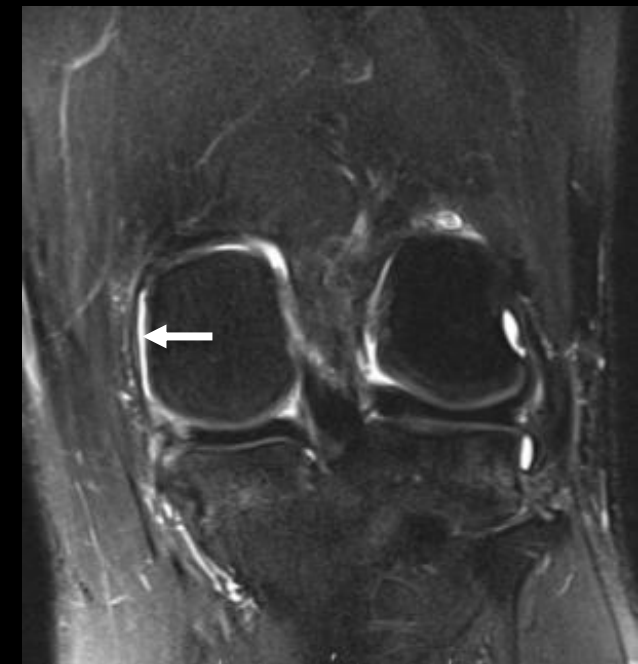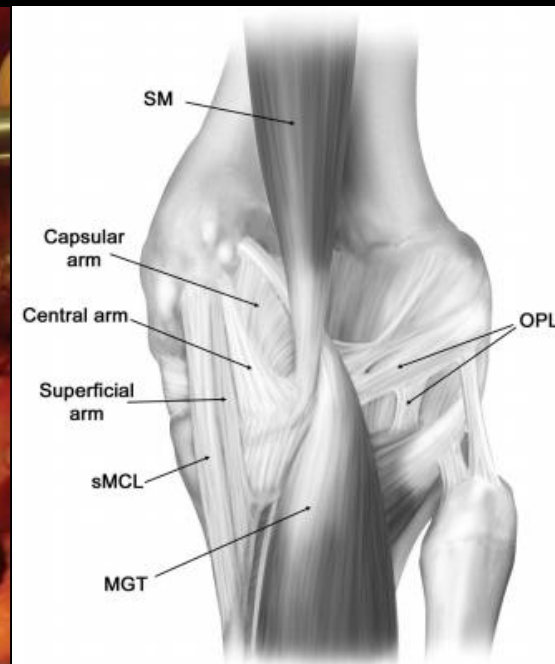
- Merging of posterior TCL (layer 2) and the joint capsule (layer 3)
- *Origin*: Just distal to gastrocnemius tubercle
- Valgus stabilizer in extension
- Three fascial attachments
  - Superficial: thin
  - **\*Central\***: thickest
    - attaches to posteromedial meniscus and joint capsule
  - Capsular: thin



De Maeseneer M.  
*RadioGraphics* 2000

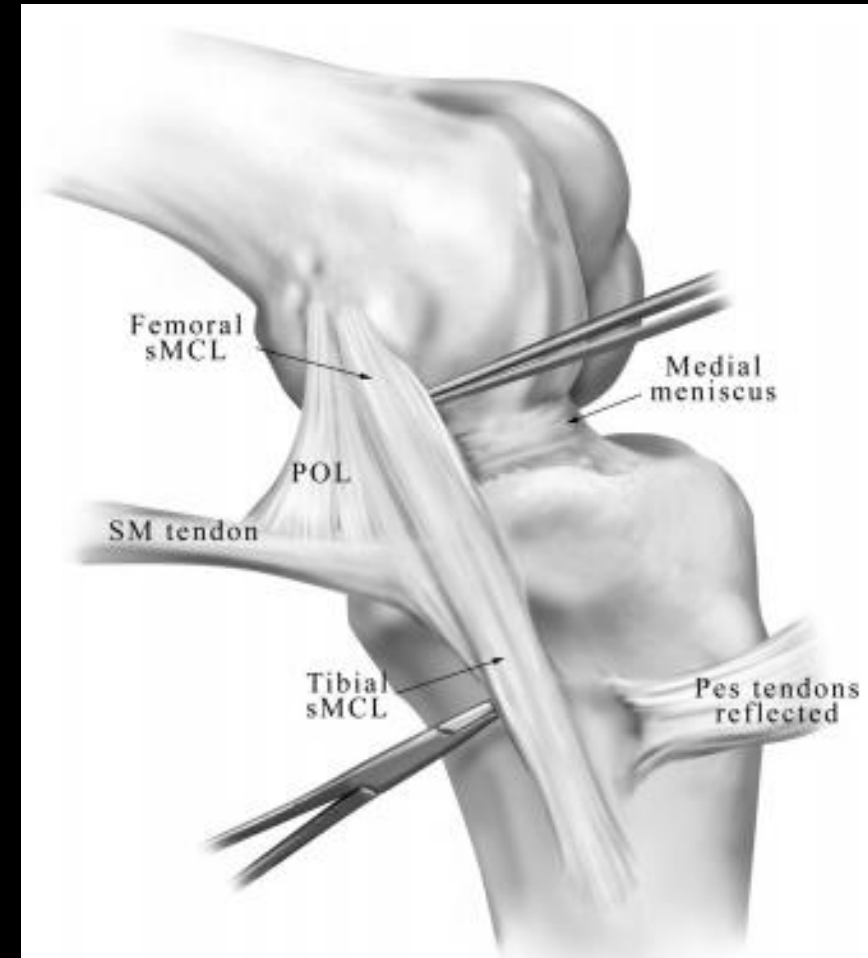


LaPrade R. *JBJS* 2007



# Medial collateral ligament trauma

- Clinical exam is performed at 30° knee flexion and in full extension
  - Laxity at 30° indicates TCL injury
  - Laxity in extension indicates more extensive injury
- Clinical grading
  - Grade 1: Microscopic tear
    - Point tender without laxity
  - Grade 2: Incomplete tear with gross fiber disruption
    - 5-15° valgus instability at 30° flexion
  - Grade 3: Complete tear
    - >15° instability at 30°, flexion, +/- instability at extension

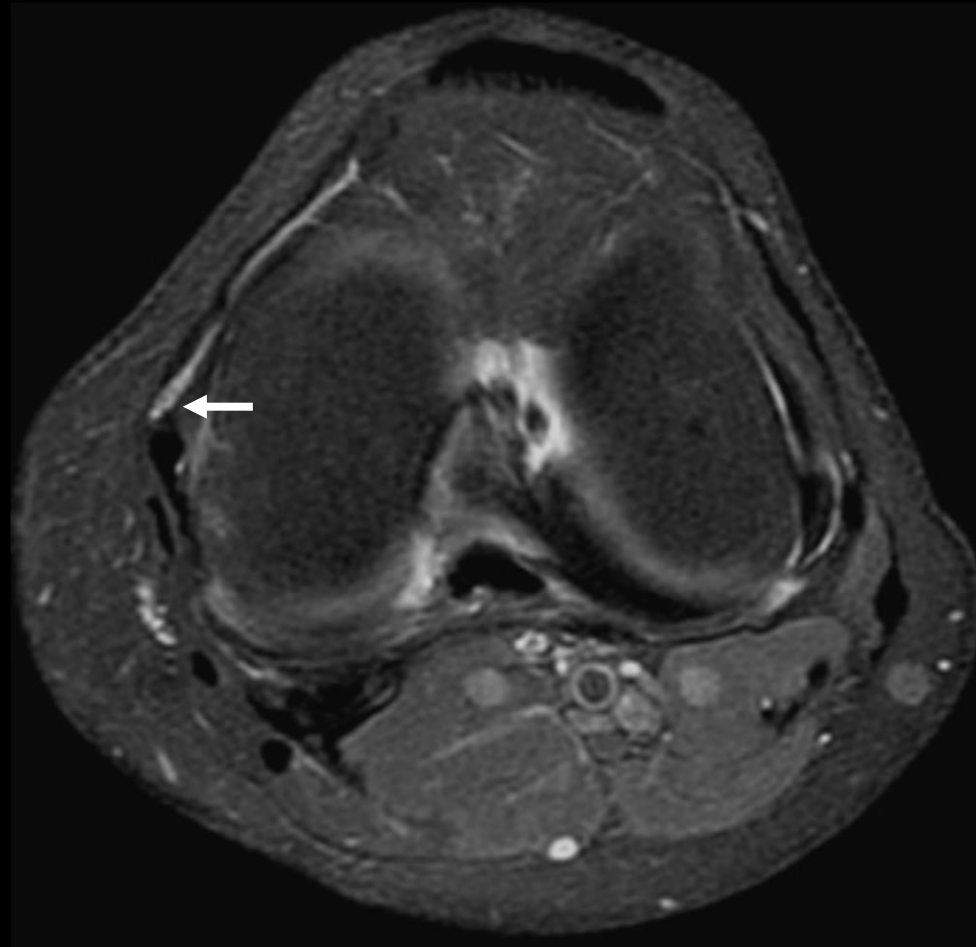
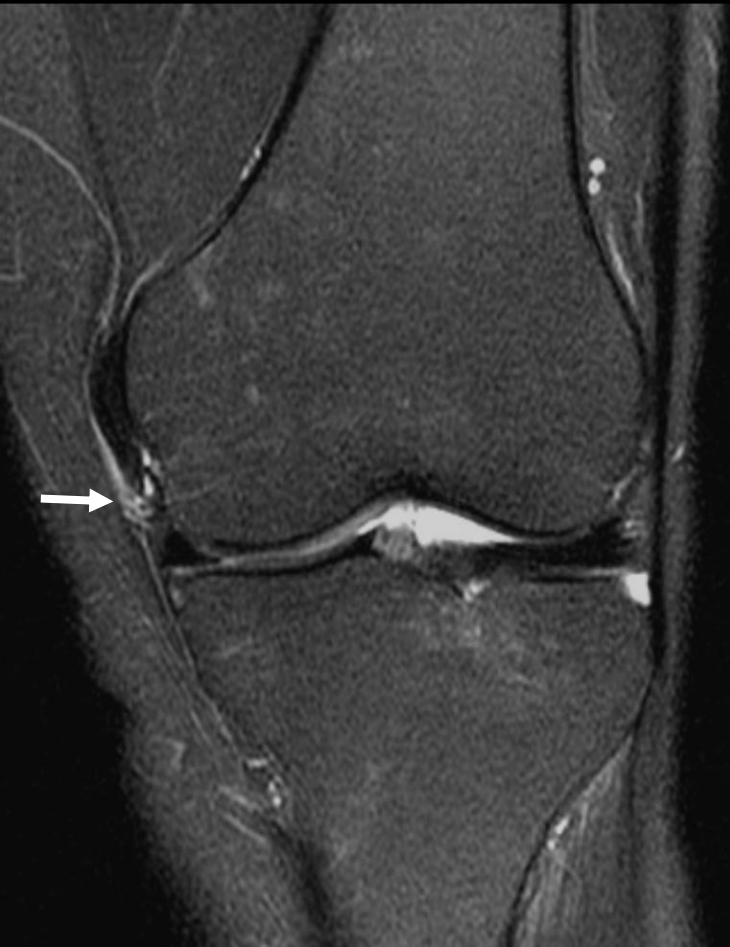

# Medial collateral ligament trauma

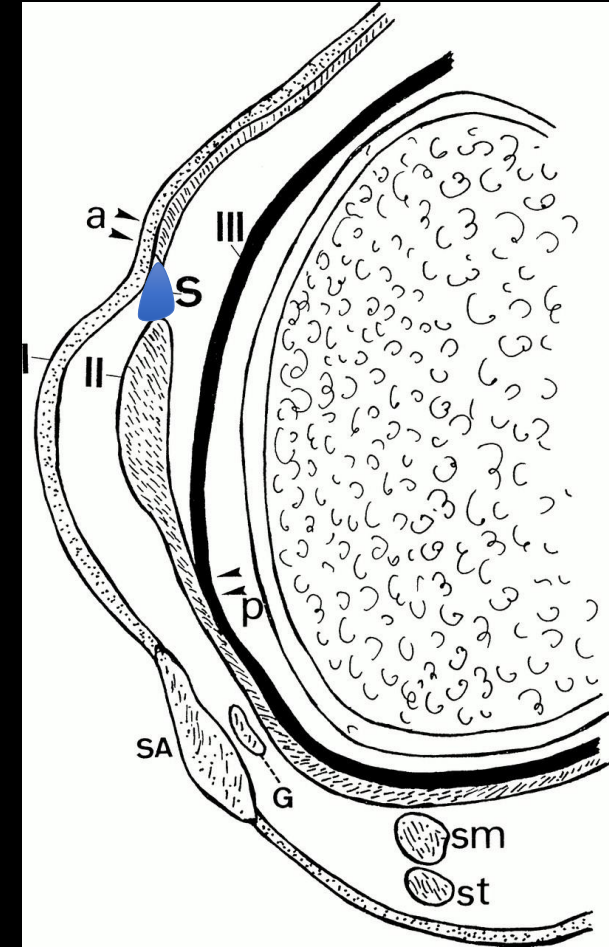
- MRI grading has focused on TCL
  - Grade 1: Microscopic tear
    - Periligamentous edema, intact TCL
  - Grade 2: Incomplete tear with gross fiber disruption
    - Partial tear with edema
  - Grade 3: Complete tear
    - Complete disruption of ligament fibers
  - Pseudotear at/above joint line anteriorly

# Medial collateral ligament trauma

- Pseudotear
  - Located anterior to the superior TCL, can simulate a tear on coronal images

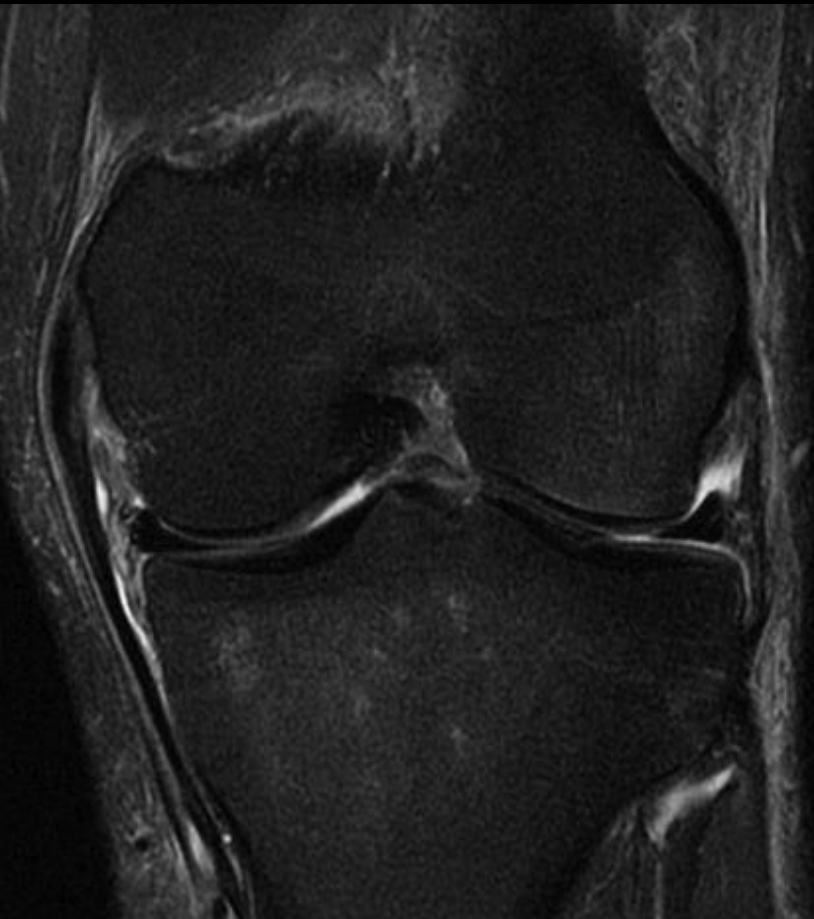

De Maeseneer M. *RadioGraphics* 2000

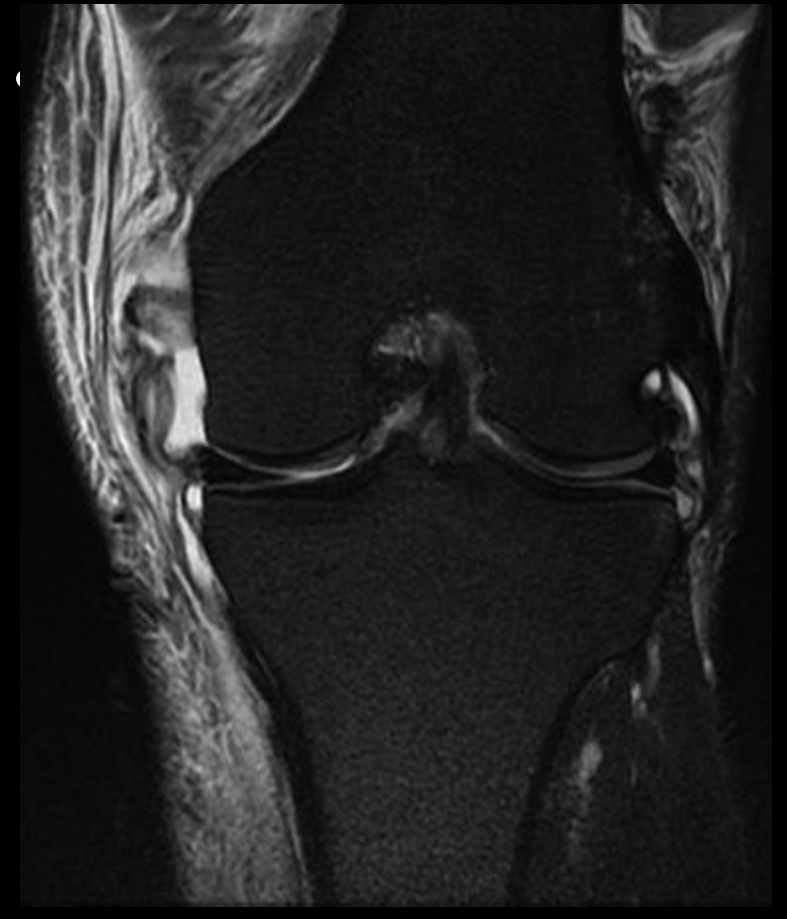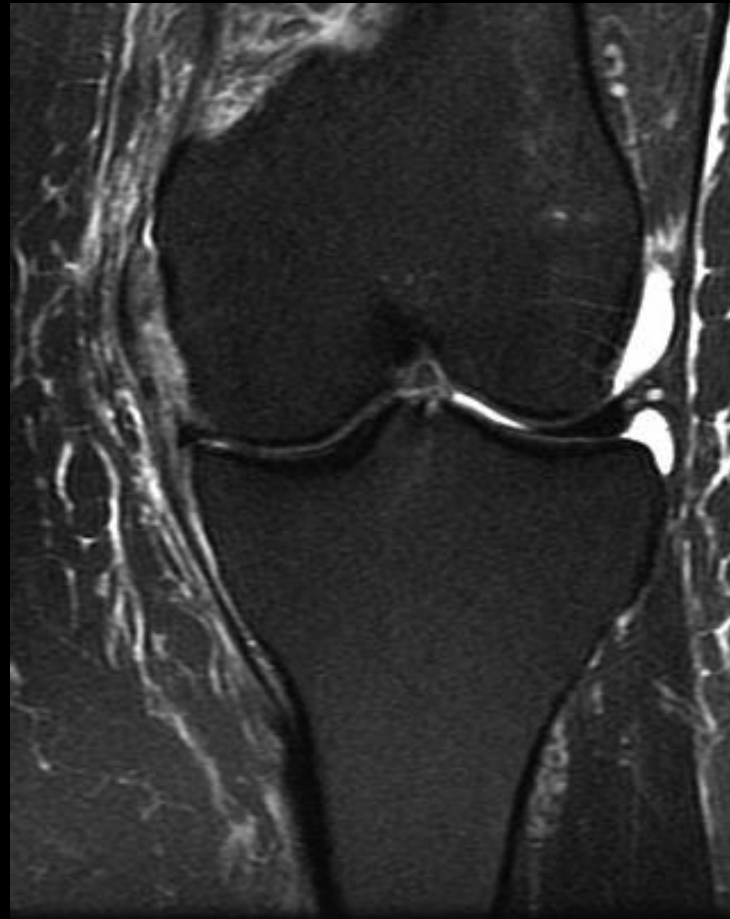


# MRI grading of TCL tears

- Grade I TCL tear
  - Periligamentous edema with intact fibers

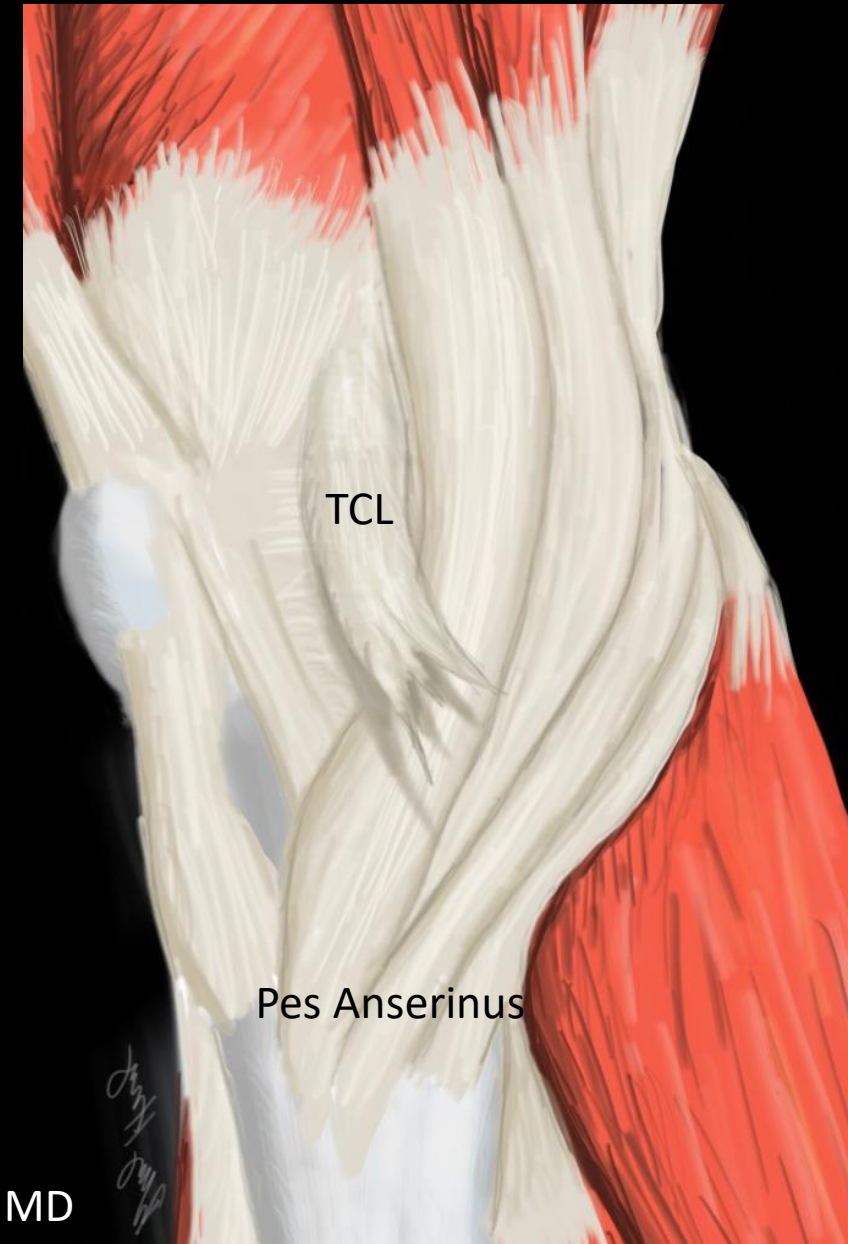


- Grade II TCL tear



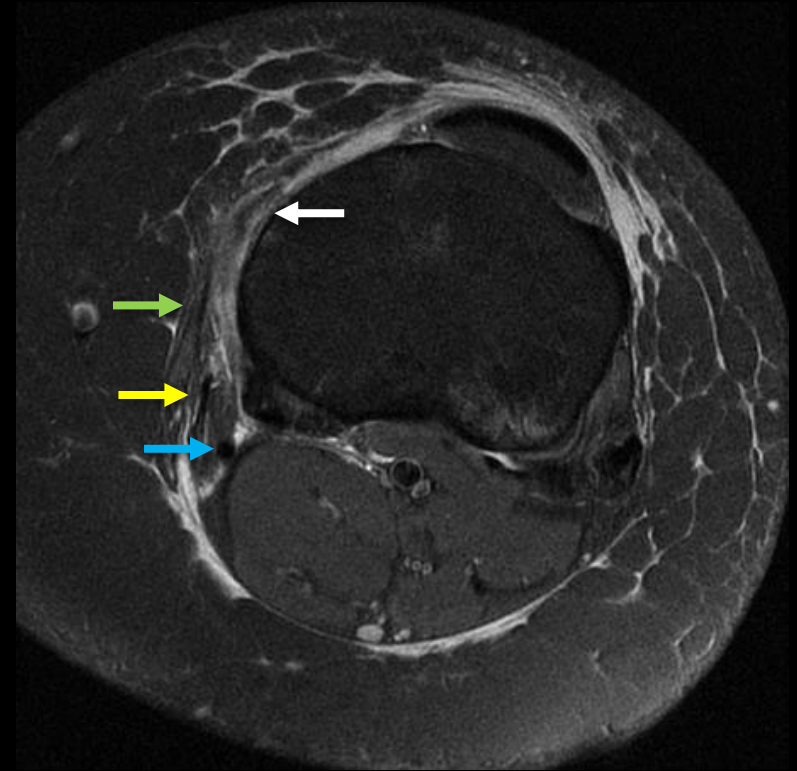
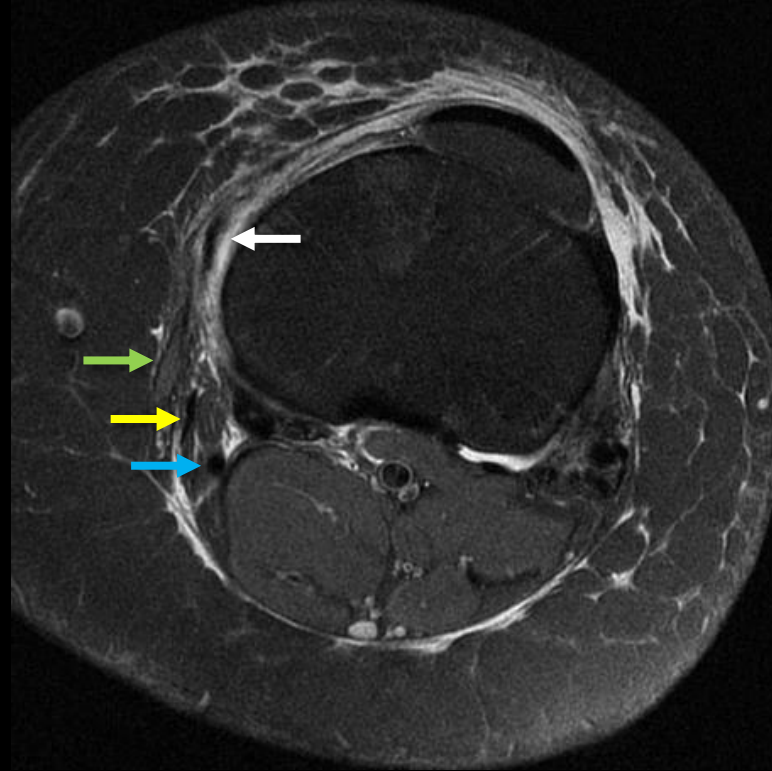
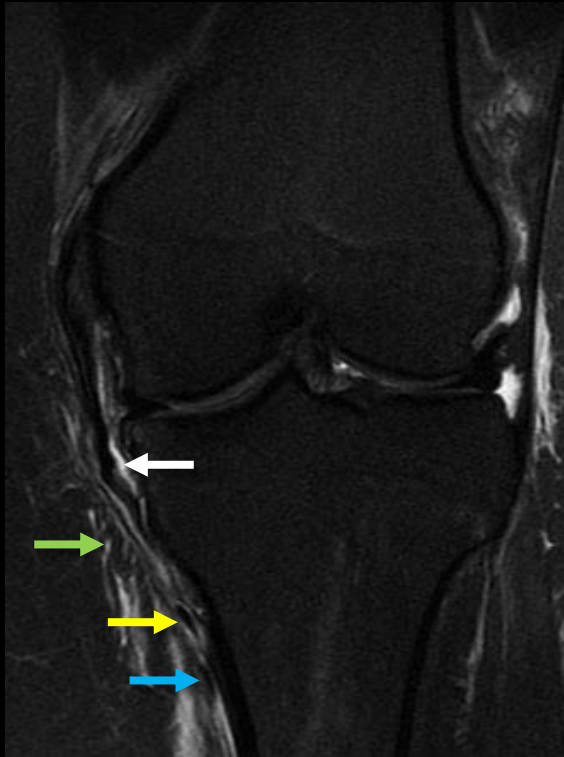# Trauma: valgus knee stabilizers

- Tibial collateral ligament
  - Commonly injured proximally
  - Often treated non-surgically
    - Good vascularity allows healing
    - Early mobilization is critical
    - Indelicato PA. JBJS 1983
      - Surgically and conservatively treated isolated grade III MCL complex injuries had no significant difference in functional outcomes
- *Distal grade III* tears can result in *Stener-like lesion* if torn ligament displaces superficial to the pes tendons
  - Laxity at 30°, but not in extension
  - This injury requires surgery



# Tibial collateral ligament trauma

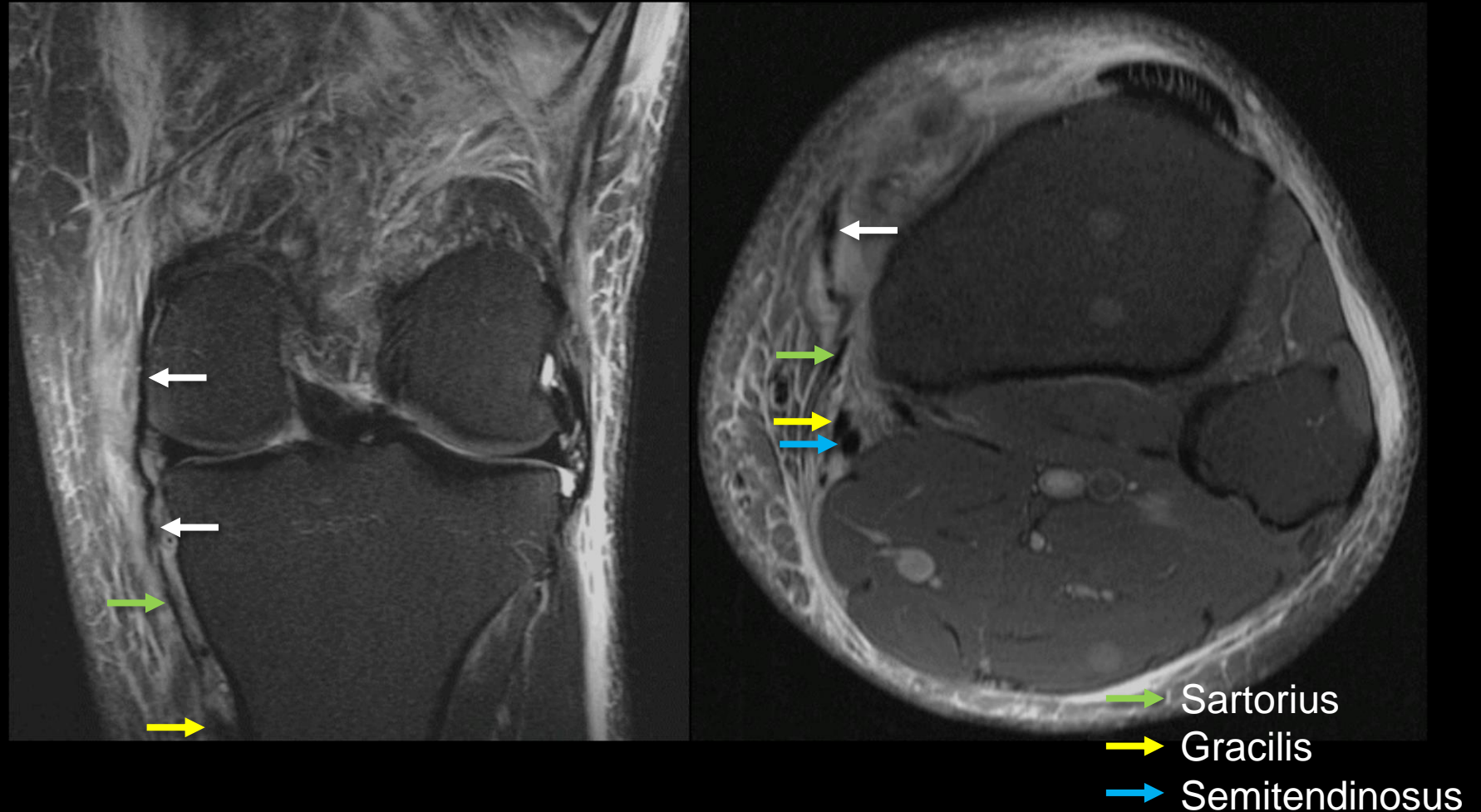
- *Distal TCL tear without Stener-like lesion* (white arrow)
  - Distal tears are less common than proximal
  - Imperative for TCL to remain deep to the pes anserinus for proper healing



- Sartorius
- Gracilis
- Semitendinosus

# Tibial collateral ligament trauma

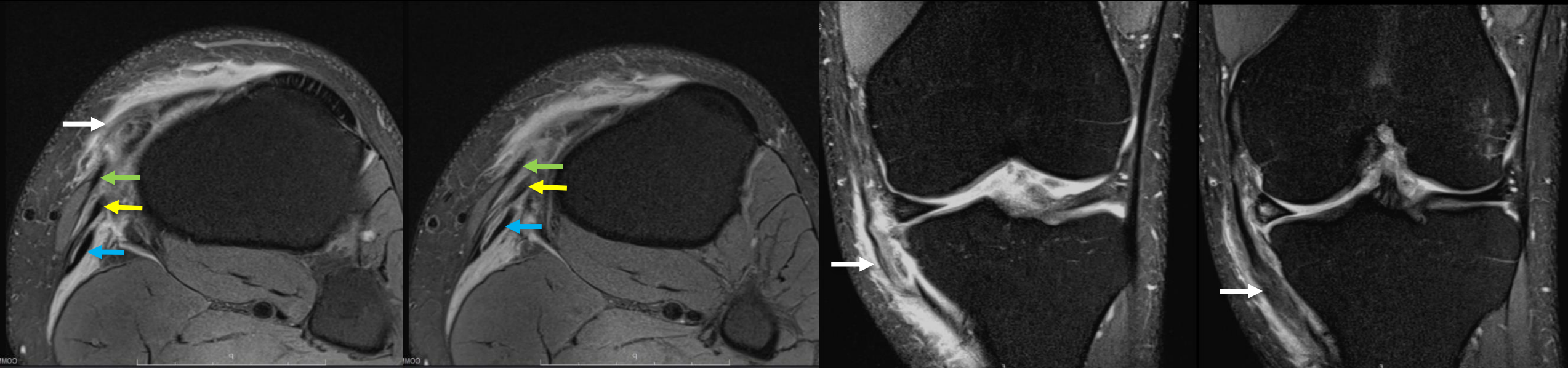
- *Distal TCL tear with Stener-like lesion* (white arrow)
  - Torn distal TCL fibers are displaced superficial to the pes anserinus
  - Prevents anatomic healing and requires surgery





# Tibial collateral ligament trauma

- *Distal TCL tear with Stener-like lesion (white arrow)*
  - Torn distal TCL displaced superficial to the pes anserinus, which can impede anatomic healing



M. Pathria, MD

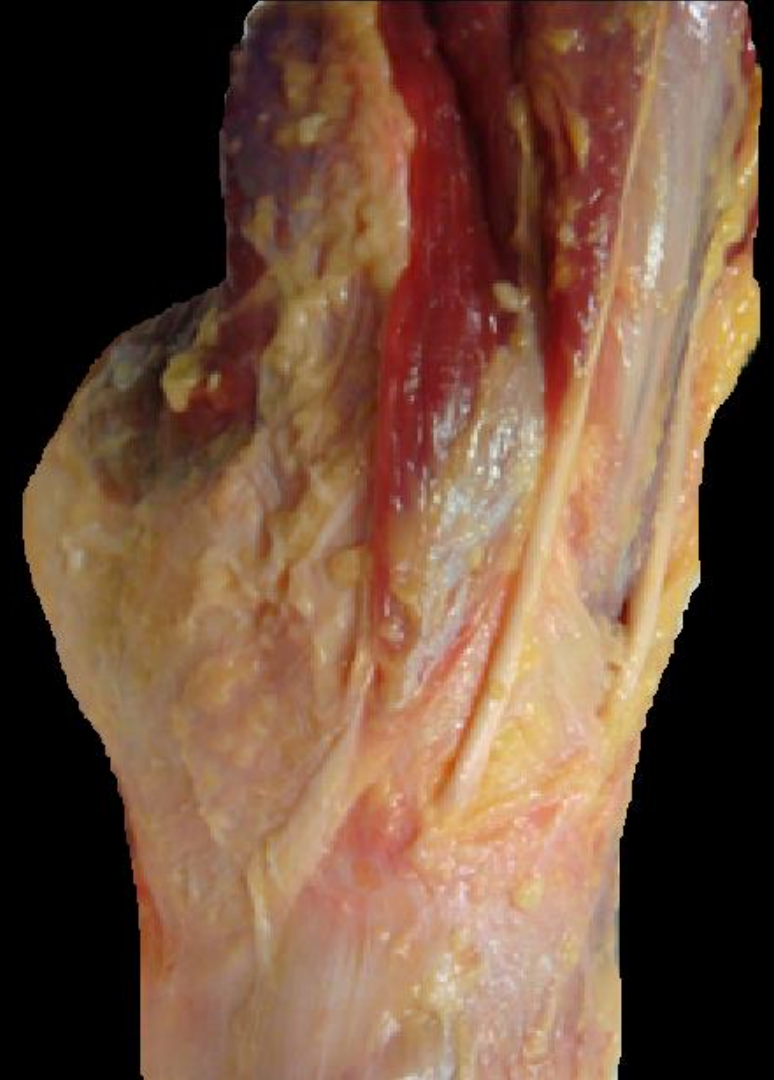- Sartorius
- Gracilis
- Semitendinosus

# Musculotendinous injury

- Musculotendinous injury (MTI)
  - *Muscle contusion*
    - Blunt direct trauma
    - Muscle compressed between object and underlying bone
    - Intramuscular hematoma and interstitial hemorrhage
    - Injury to adjacent subcutaneous tissues and bone
  - *Myotendinous strain*
    - Excessive tension
    - Majority occur at myotendinous junction
  - *Tendon avulsion*
    - Forceful eccentric contraction
- Risk factors for MTI
  - Composition (type II fibers)
  - Biarticular
  - Large muscle
  - Pennate architecture
  - Eccentric action

# Pes musculotendinous trauma

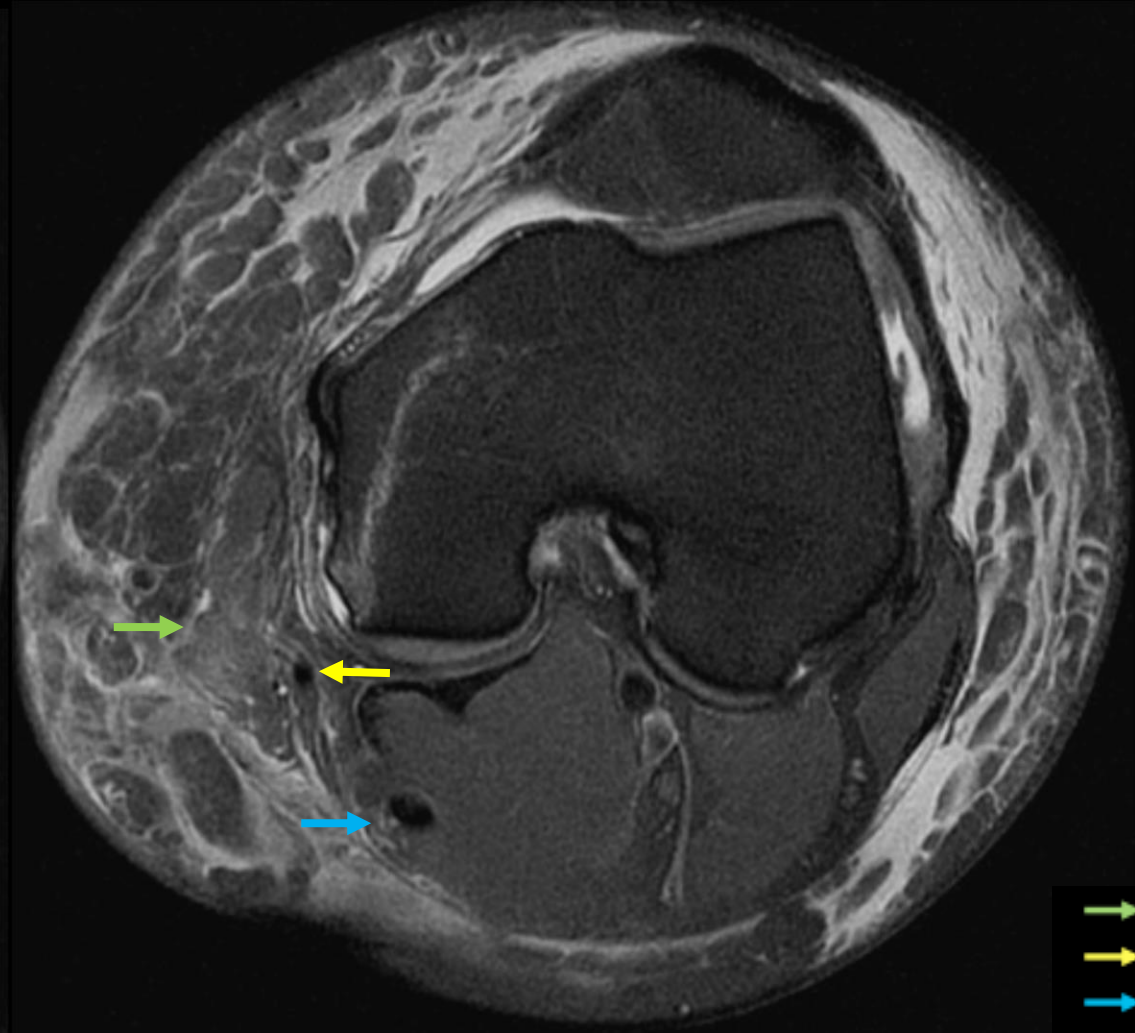
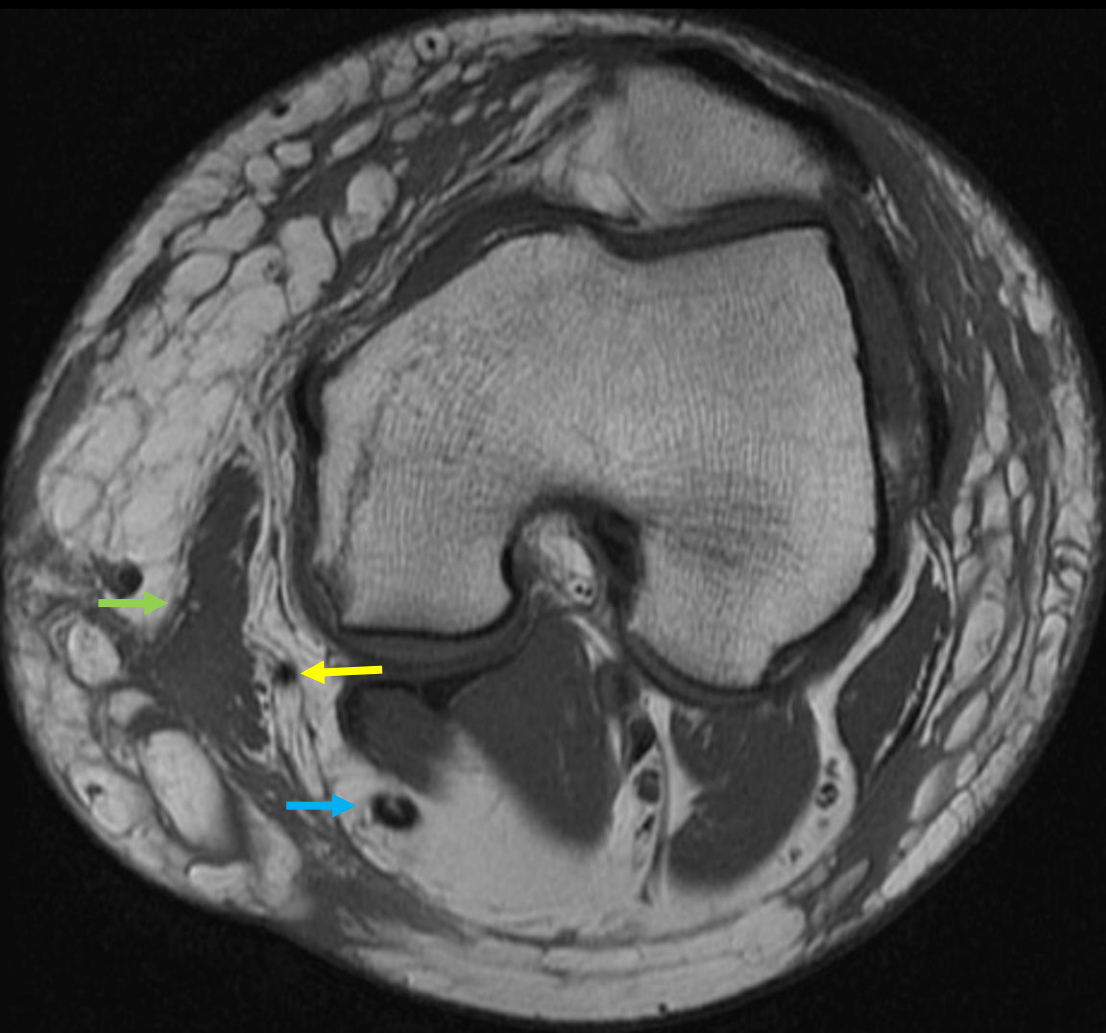
- Sartorius is most commonly injured (superficial and biarticular)
- Semitendinosus injuries are reported in athletes
- Pes anserinus is a dynamic valgus knee stabilizer
  - Multitendinous injury is usually associated with significant trauma to other valgus stabilizers



# Trauma: Sartorius injury

- Sartorius is superficial, putting it at risk for contusion

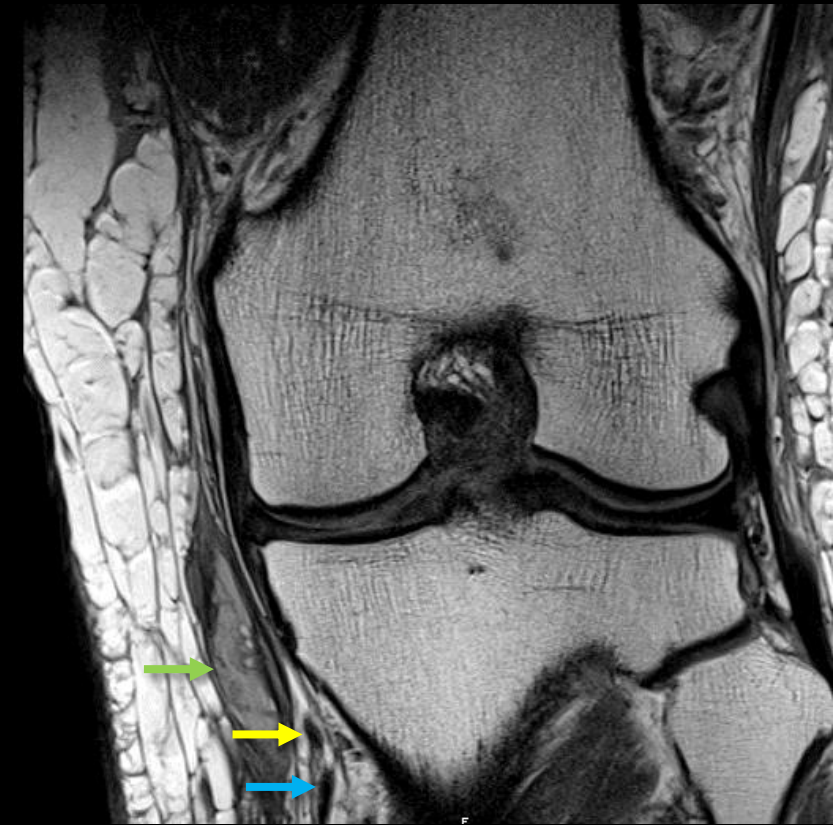
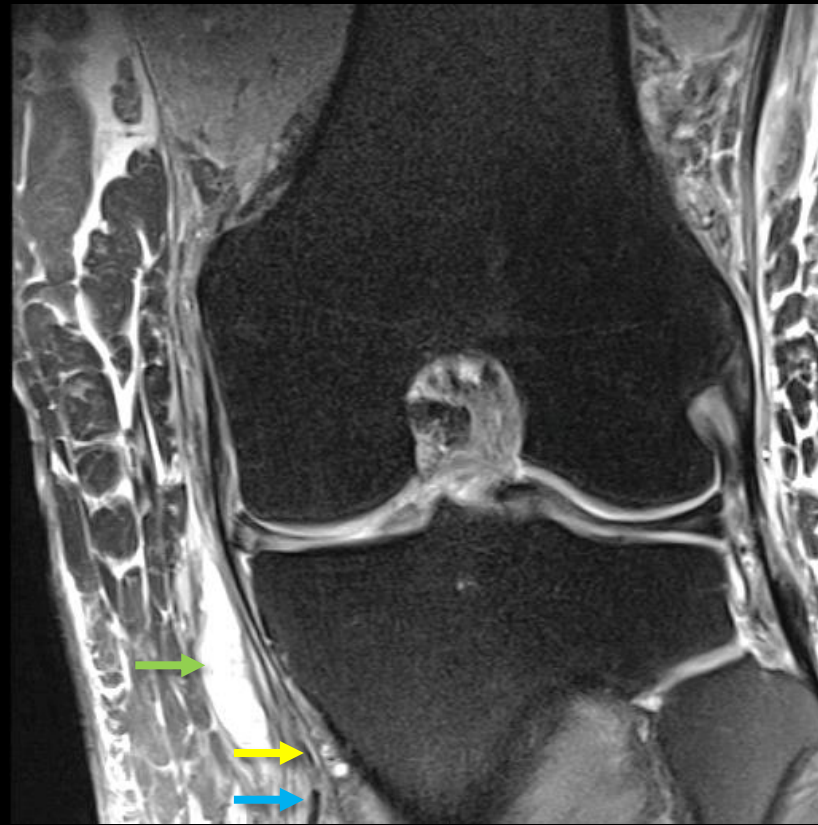
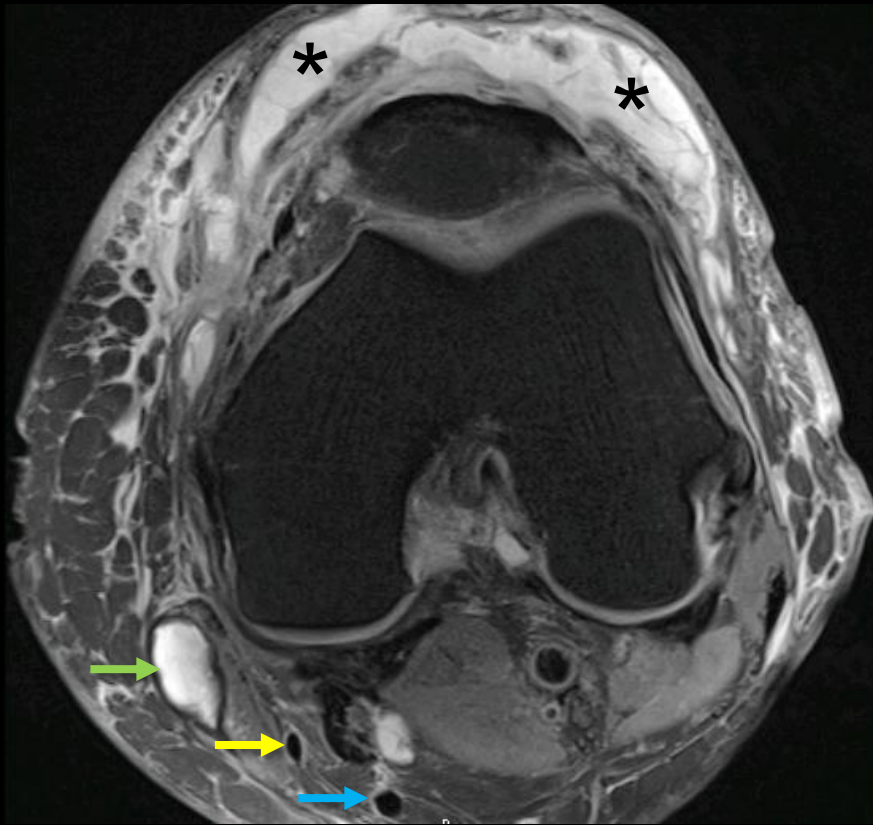
Knee pinned between cars



→ Sartorius  
→ Gracilis  
→ Semitendinosus

# Trauma: Sartorius injury

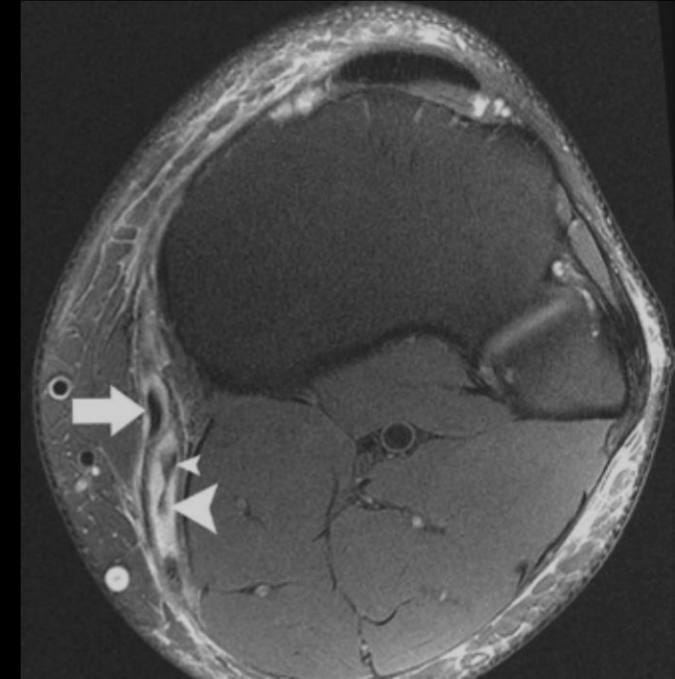
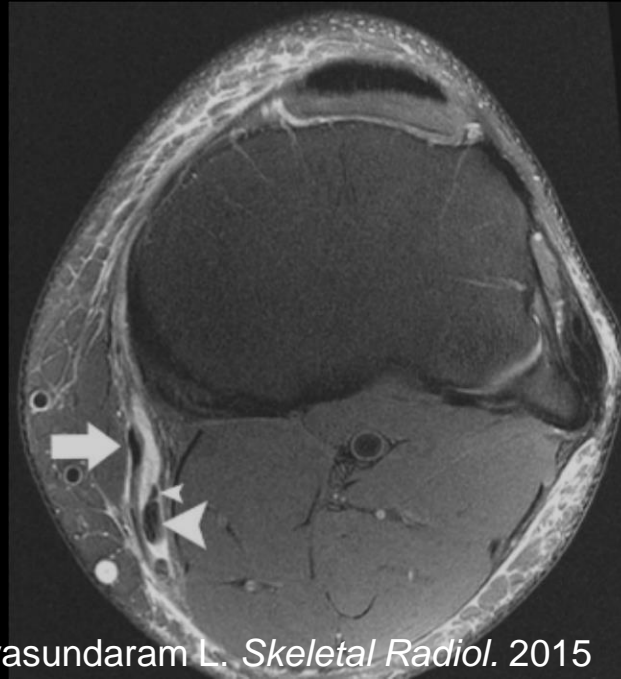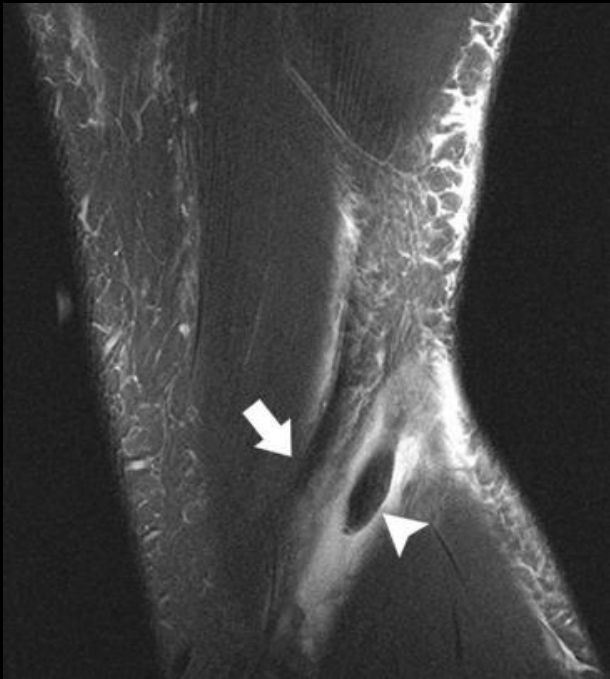
- Sartorius tear with intramuscular hematoma and degloving injury anterior to the patella (black asterisks)



- Sartorius
- Gracilis
- Semitendinosus

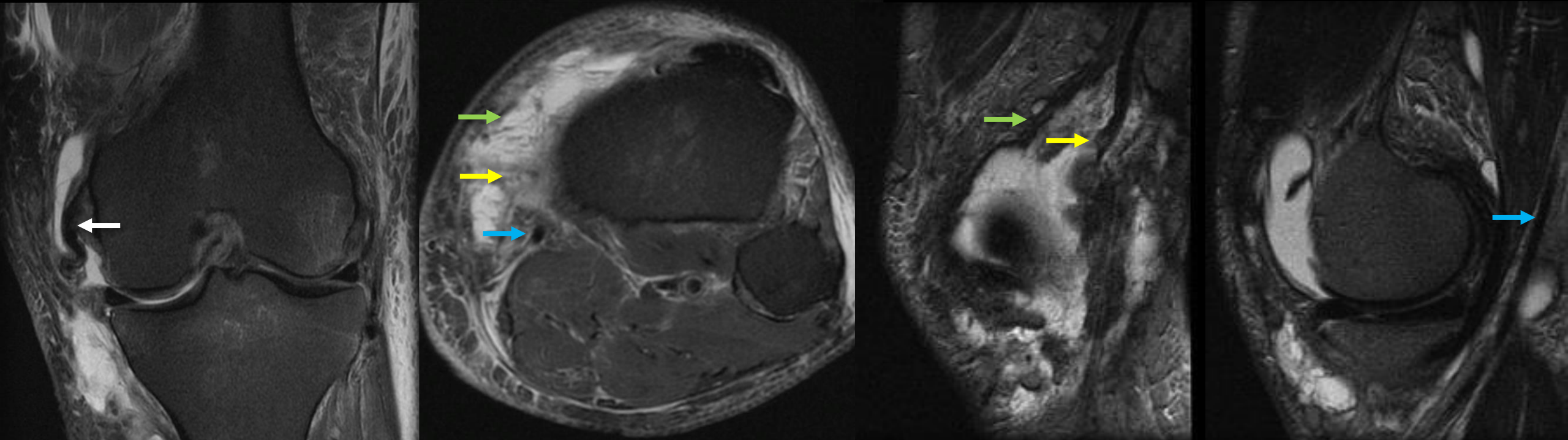
# Trauma: Semitendinosus injury

- Isolated injury reported in high level athletes
  - Lempainen L. *Br J Sports Med* 2007
    - 1 avulsion and 1 MTJ semitendinosus injury in 18 distal hamstring injuries
  - Cooper D and Conway J. *Am J Sports Med* 2010
    - 42% of 12 semitendinosus partial tears failed conservative treatment
  - Schilders E. *Knee* 2006
    - Tenotomy performed for partial tears in 4 patients with good outcomes



# Trauma: MCL, Sartorius, and Gracilis tears

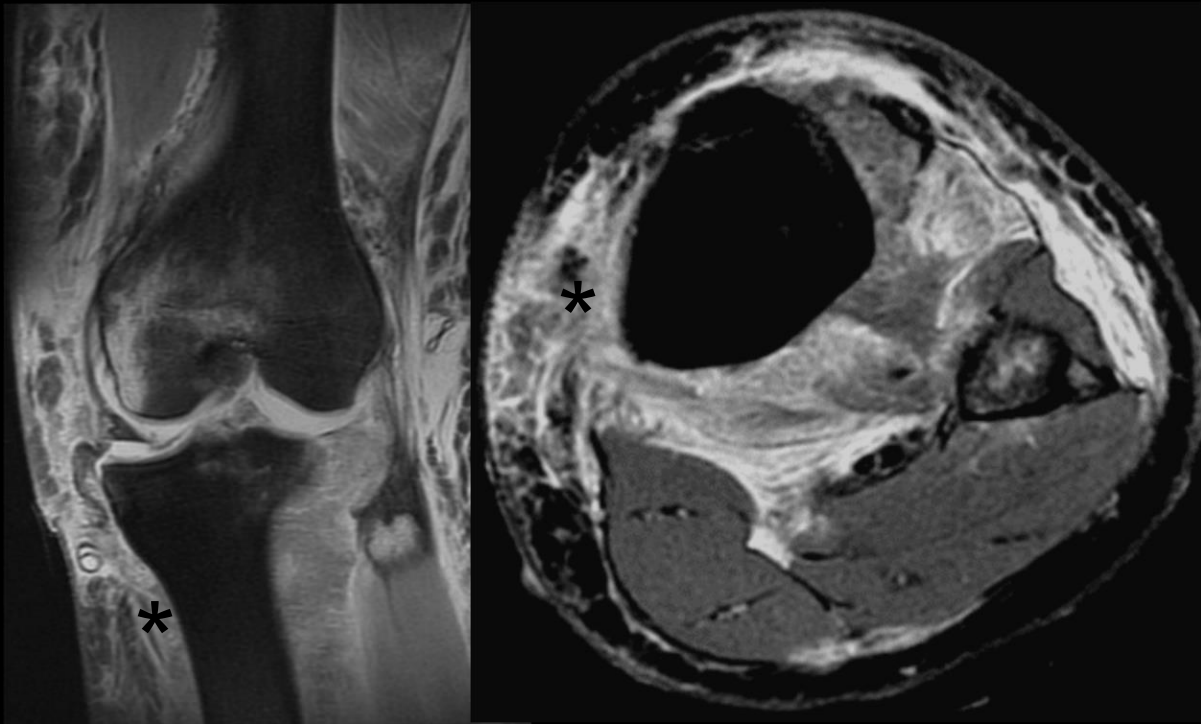
- Pes anserinus injury is often associated with significant injury to other major valgus stabilizers



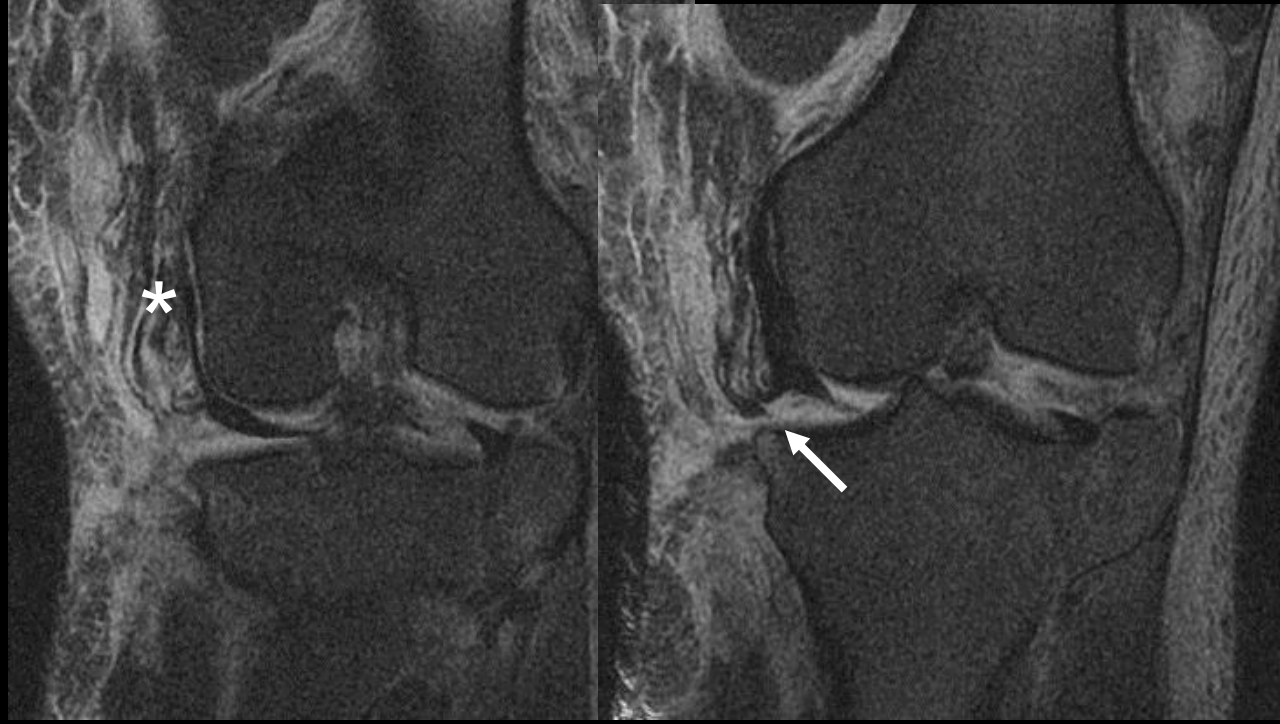- Sartorius
- Gracilis
- Semitendinosus

# Trauma: Pes anserinus avulsion

- Complete pes anserinus avulsion (asterisks) is uncommon, but can occur with substantial injury, such as these cases of knee dislocations
- Torn tendons can displace into the joint (white arrow).



Case A



Case B





# Medial Hamstring Autograft

- ACL reconstruction
  - Medial hamstrings as autograft
    - Tendon regeneration
    - Clinical implications of tendon regeneration
    - Cases of normal and abnormal tendons after harvest
    - Saphenous nerve

# ACL Reconstruction

- Goal is to regain joint stability and high level of function
- Reconstruction graft is a scaffold for synovial ingrowth, neovascularization and neoligamentisation
- Options
  - Bone-patellar tendon-bone
  - Hamstring (semitendinosus +/- gracilis)
  - Others including ITB, quadriceps, allograft

# ACL Reconstruction

- Bone-patellar tendon-bone

- Advantages

- Stronger?
- Similar to native ACL

- Medial hamstring

- Advantages

- Increased surface area for more vascular ingrowth
- Less morbidity

Larson R. *op tech in orth* 1996

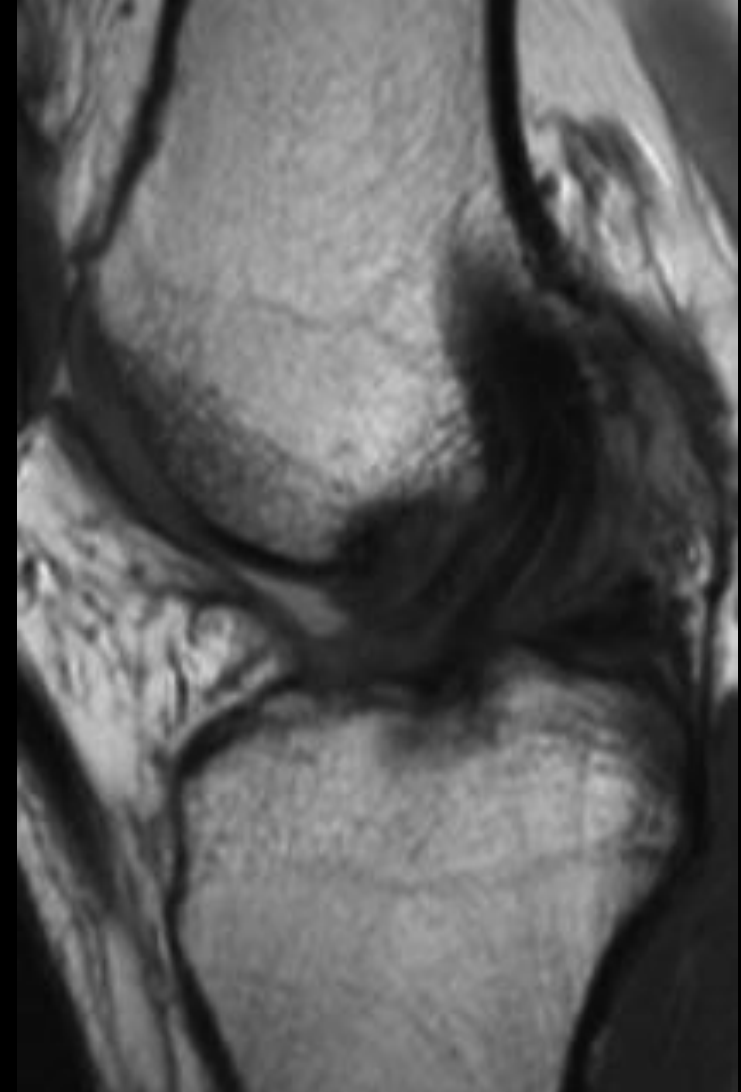
Graft	Tensile strength relative to normal ACL
Patellar Tendon (14 mm)	159% - 168%
Semitendinosus	70%
Gracilis	49%
SemiT & Grac doubled	~240%

Jansson KA *Skeletal Radiol* 2001

Signal increase	Joint		Proximal tibial bone tunnel	
	BTB	STG	BTB	STG
None	5	5	6	2
Mild	4	4	3	5
Moderate	1	1	1	3

# Medial hamstring ACL reconstruction

- Medial hamstring autograft
  - Often two tendons doubled
  - Individual strands can be visualized
  - High surface area may allow for increased vascular ingrowth versus a single strand autograft (patellar tendon)

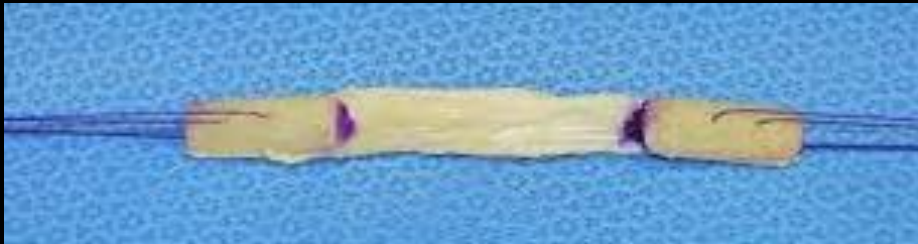


# Graft site complications

- Bone-patellar tendon-bone

- Complications

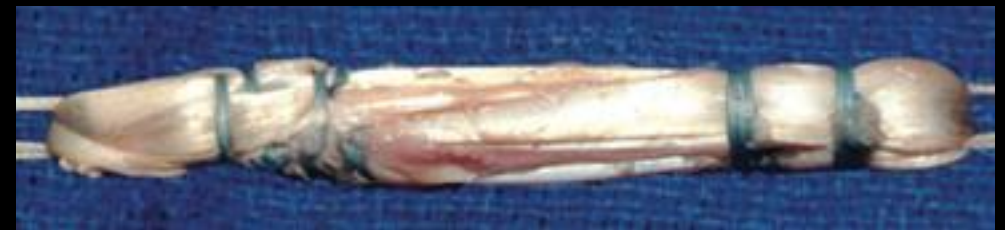- Anterior knee pain
- Extensor mechanism weakness
- Patellar fracture



- Medial hamstring

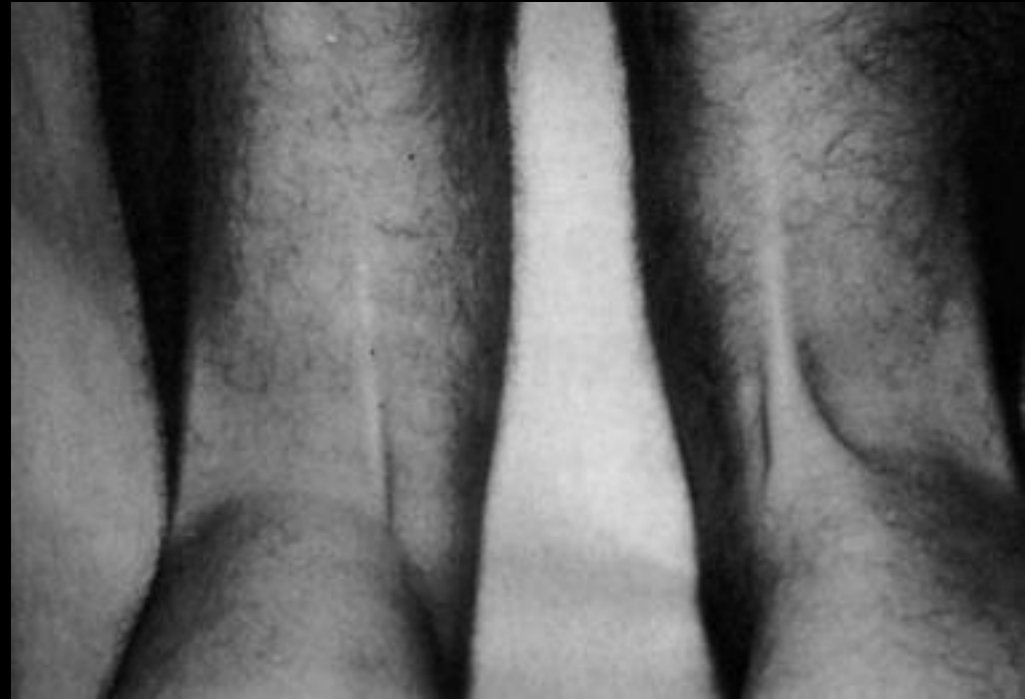- Complications

- Premature graft rupture during harvest (esp. semitendinosus)
- Temporary weakness
- Proximity of TCL and saphenous nerve put them at risk for injury during harvest



# Medial hamstring regeneration after harvest

- Medial hamstrings *function* after harvesting
  - Lipscomp AB. *Am J Sports Med* 1982
    - 51 patients ~2 years after harvest showed **normal hamstring strength** compared with normal knee
- Medial hamstring *regeneration*
  - Cross MJ. *Am J Sports Med* 1992
    - 225 patients clinically showed thick tissue in expected hamstring region, **4 patients underwent MRI showing neotendon**



# Medial hamstring regeneration after harvest

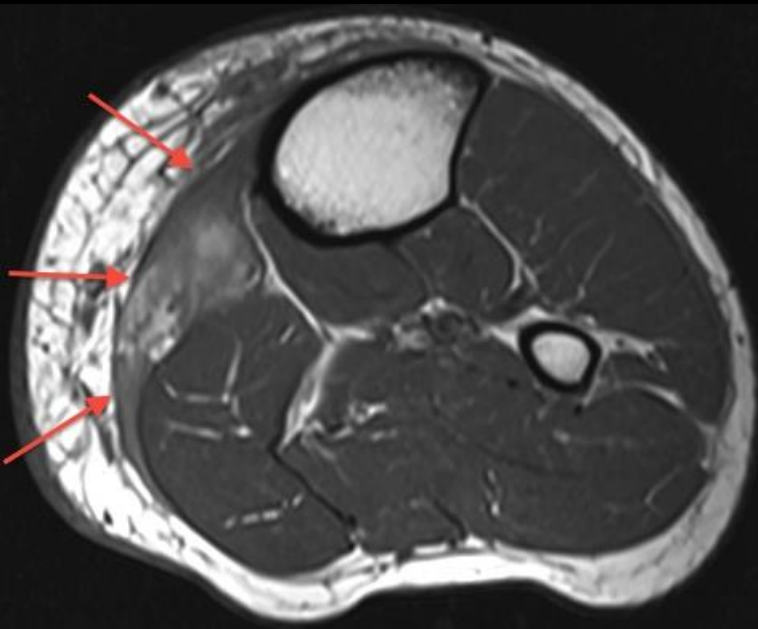
- Regeneration timeline

- Rispoli DM. *Arthroscopy* 2001: MRI findings in 21 patients

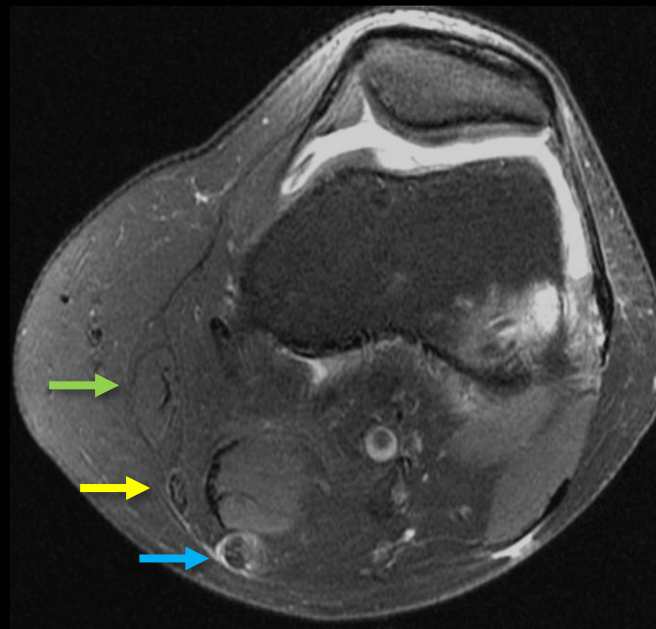
- 2 weeks: fluid at harvest site
    - 6 weeks: neotendon at level of superior patella
    - 3 months: neotendon at level of joint line
    - 12 months: neotendon near the tibial attachment
    - 32 months: normalization of neotendon signal

→ Sartorius  
→ Gracilis  
→ Semitendinosus

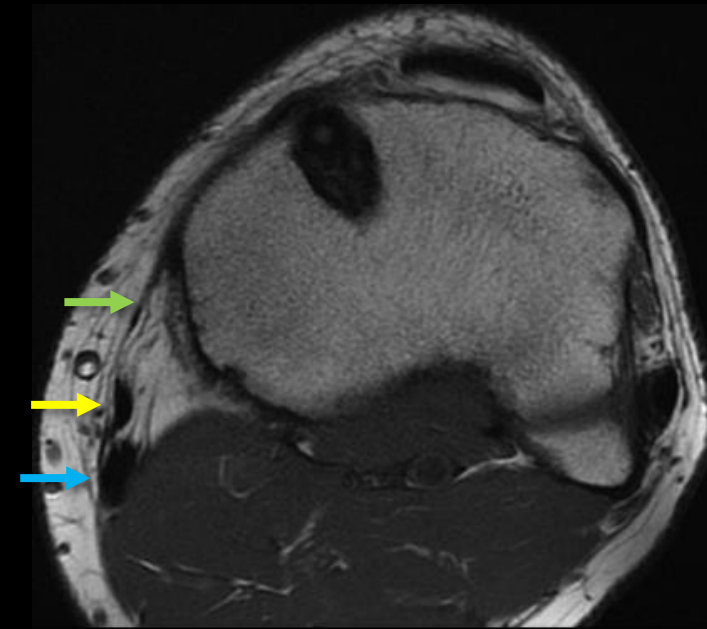
~1 week after harvest



~7 weeks after harvest



14 years after harvest





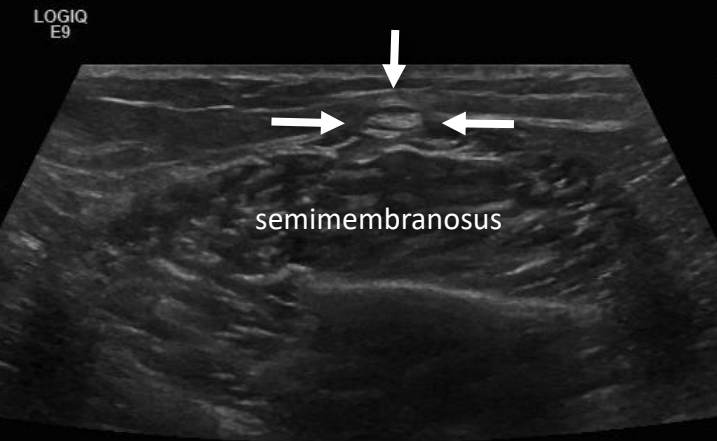
# Medial hamstring regeneration after harvest

- Tendon regeneration

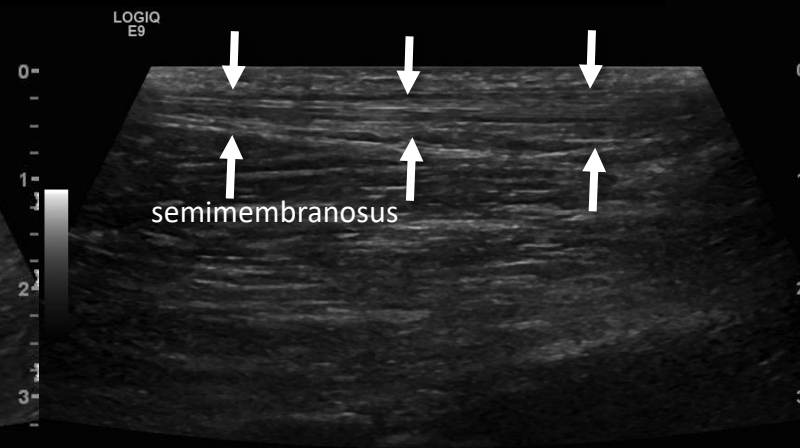
- Papandrea P. *Am J Sports Med* 2000: ultrasound findings in 40 patients at multiple time points up to 24 months
  - 2 weeks: fluid at harvest site
  - 1-6 months: uniform neotendon along harvest site without collagen fibers
  - 18&24 months: neotendon appeared similar to native tendon

Normal semitendinosus

Short axis



Long axis

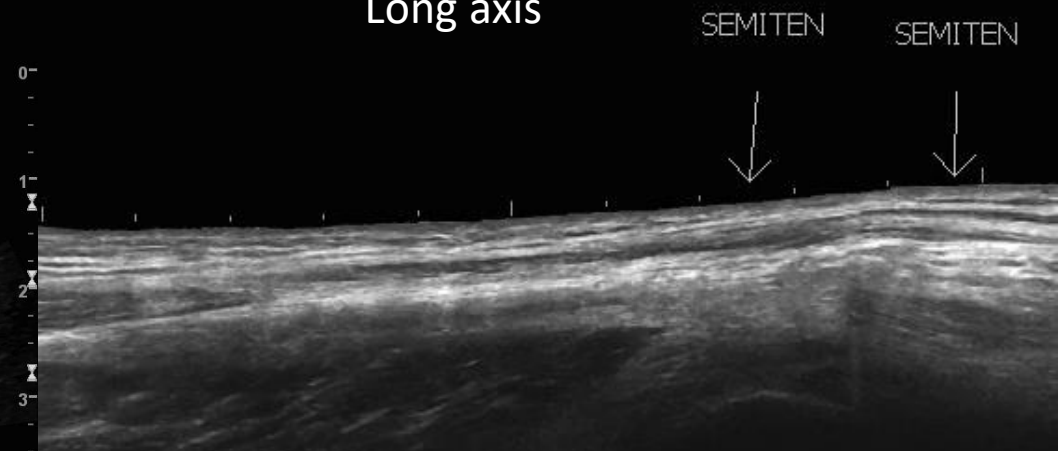


RT KNEE SEMIMEM SEMITEN

RT KNEE SEMIMEM SEMITEN

Neotendon 7 years after ACL reconstruction

Long axis

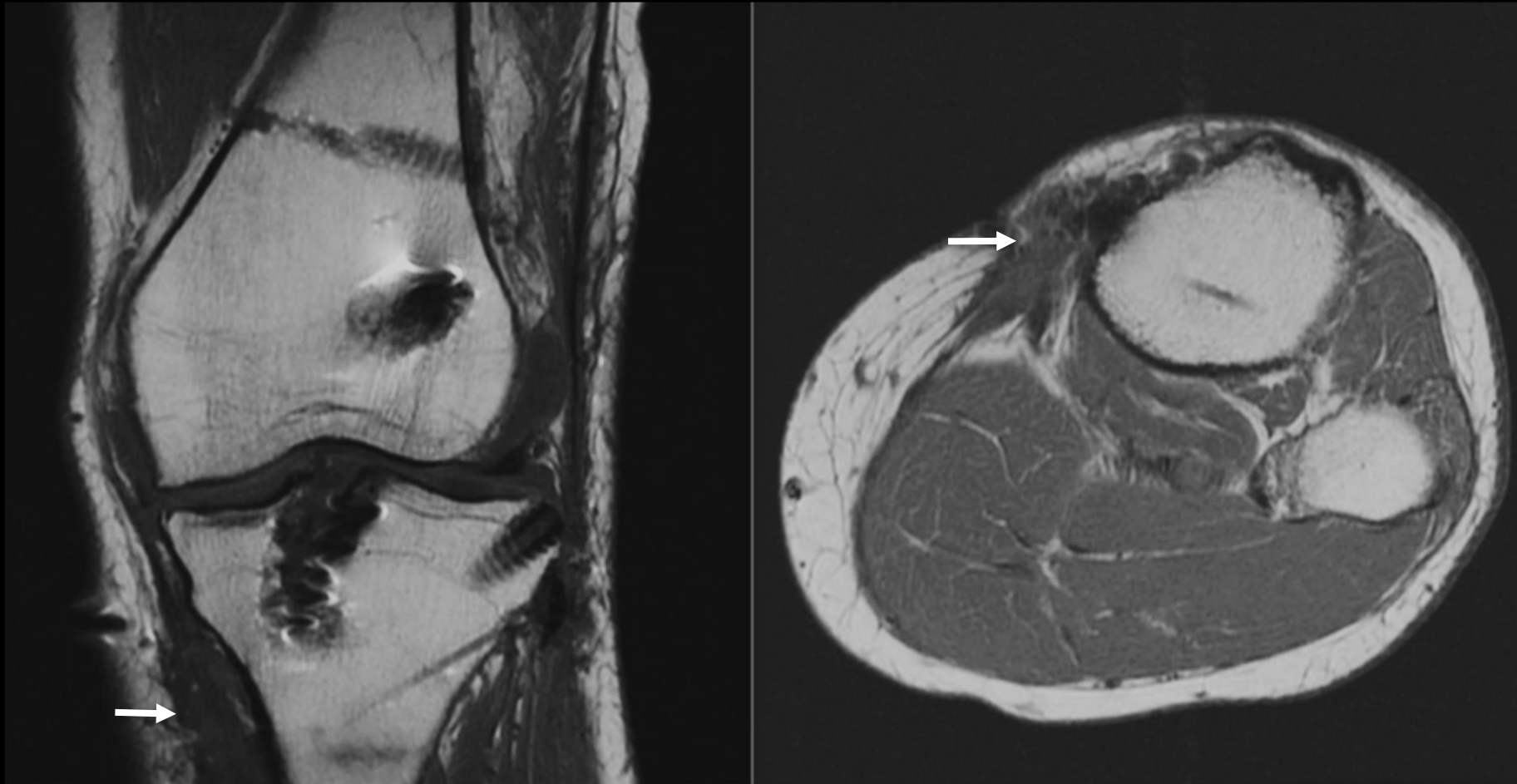

# Medial hamstring regeneration after harvest

- Neotendon histology
  - 6 months: predominantly fibrous tissue with few collagen bundles
  - 2 years: neotendon is similar to native tendon, but has focal scar, irregular collagen, increased capillaries and fibroblastic proliferation
- Clinical considerations
  - Weaker tendons, thus should probably not be used for re-harvest
  - Are the weaker tendons at increased risk for injury?

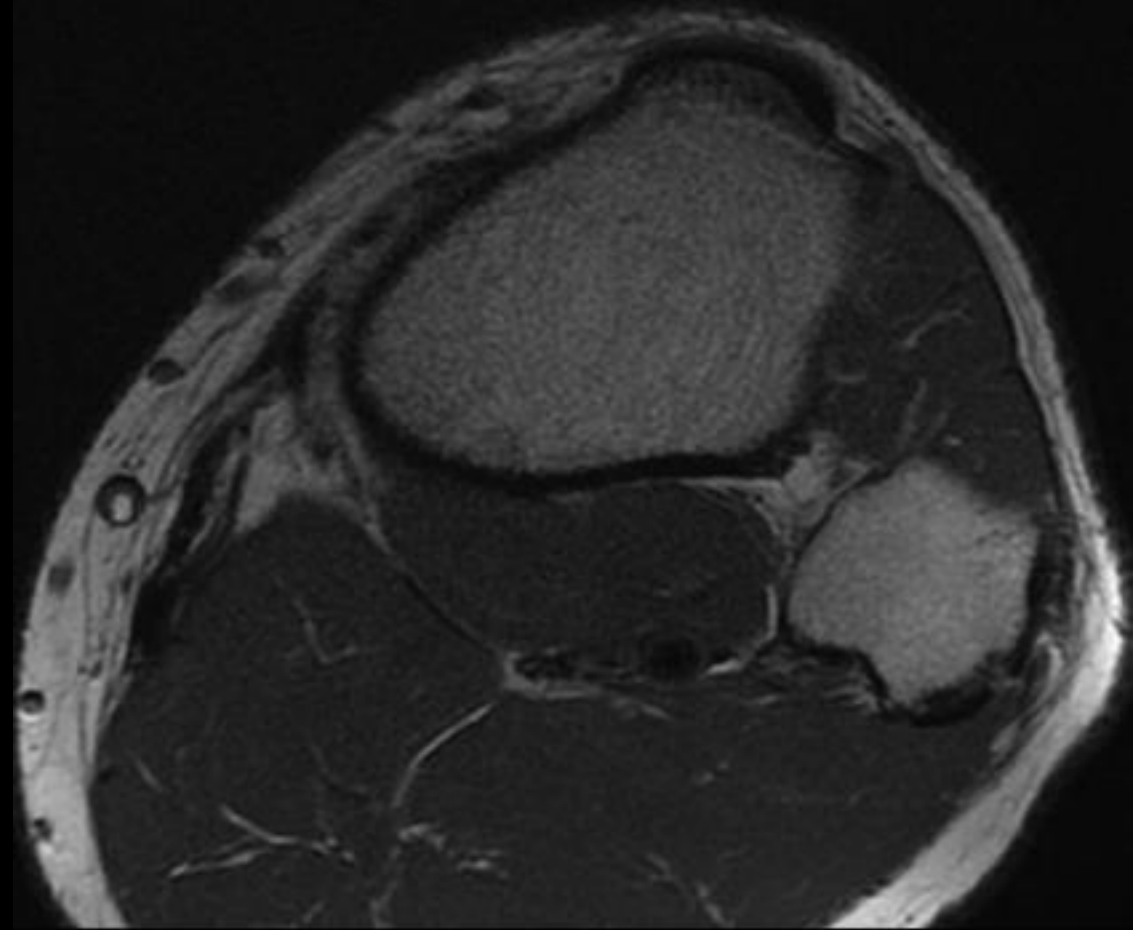
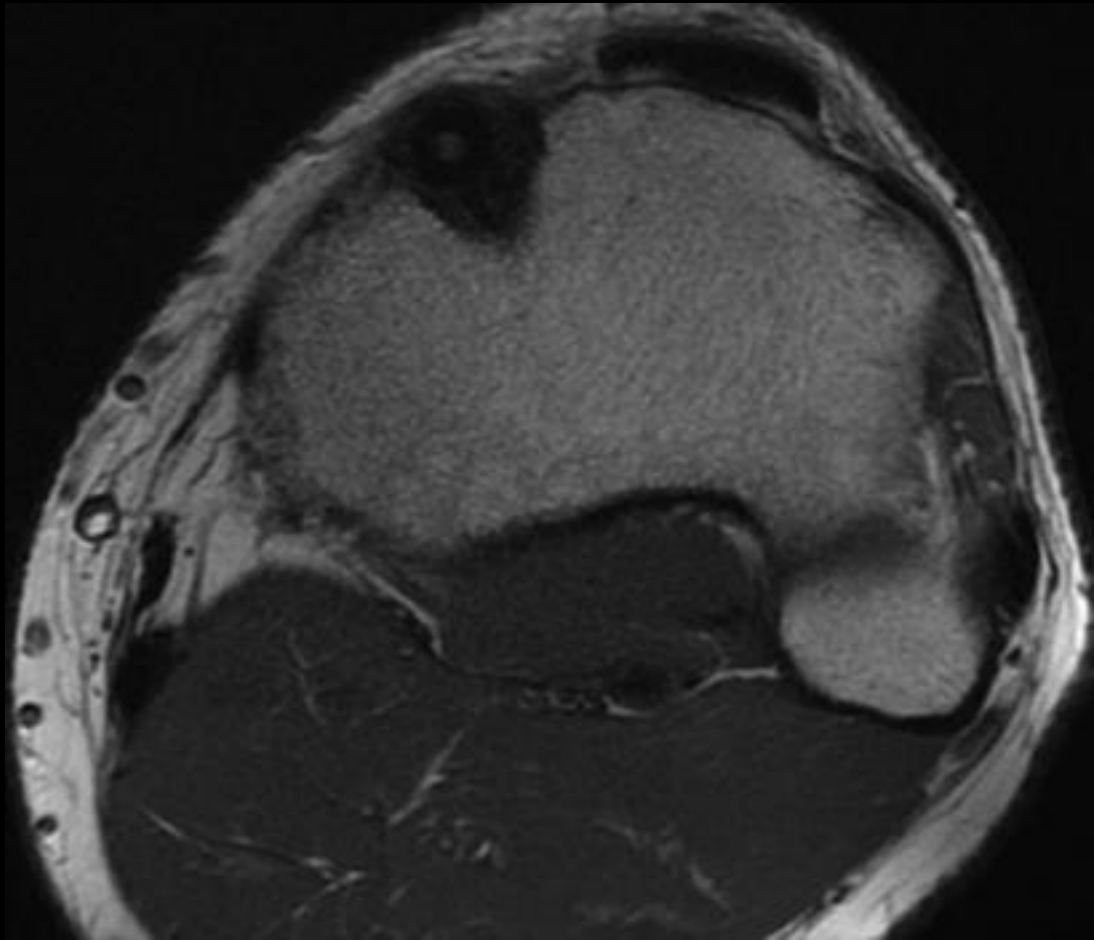
# Medial hamstring regeneration after harvest

- Scarring (white arrows) occurs at the pes anserinus harvest site-this is not where the neotendons insert



# Medial hamstring regeneration after harvest

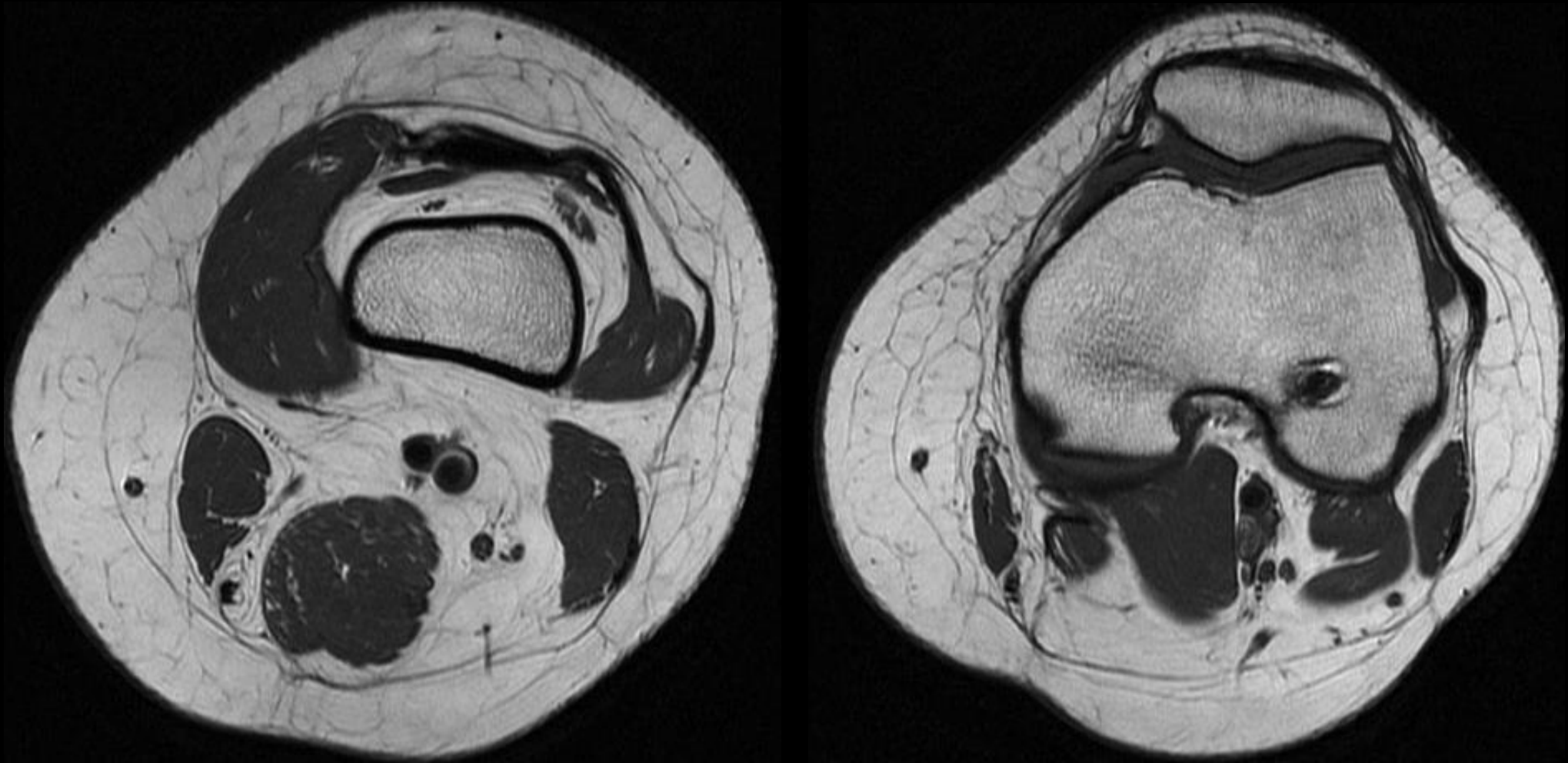
- Neotendons do not insert at native pes anserinus
  - Usually insert on popliteal fascia
  - Decreased ability to internally rotate tibia



# Medial hamstring regeneration after harvest

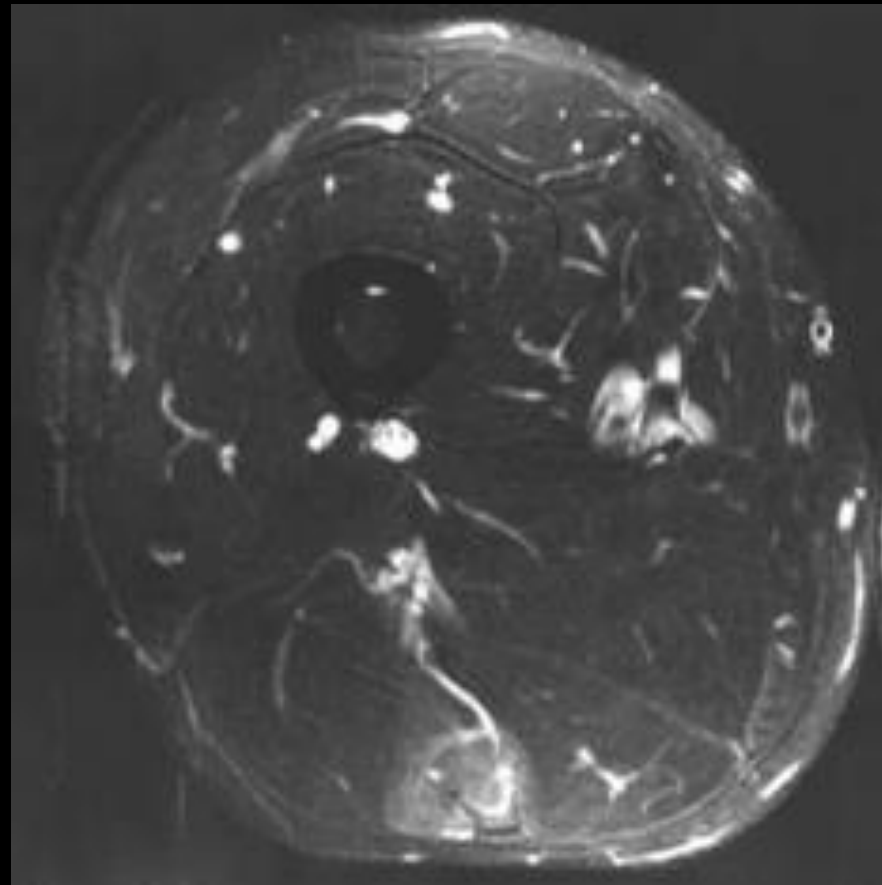
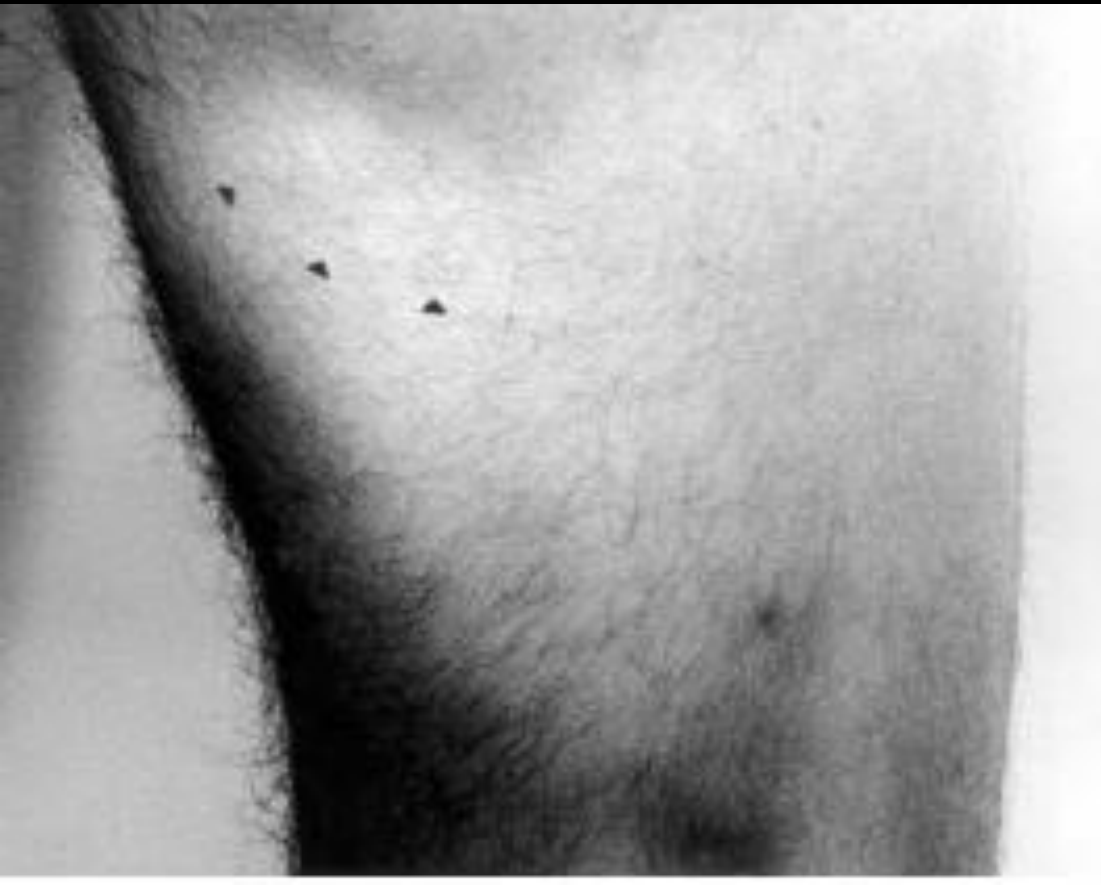- Occasionally tendons show limited or no regeneration

ACL reconstruction in 2003, MRI 2014



# Medial hamstring regeneration after harvest

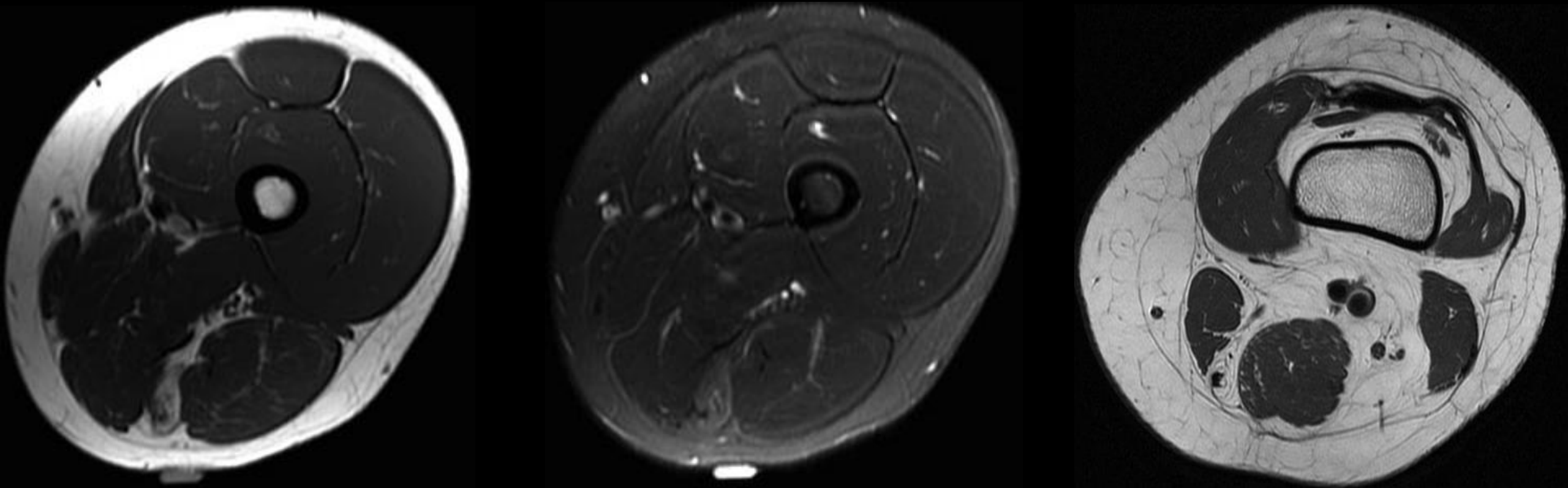
- Jarvinen T et al. Arthroscopy 2003
  - Case report of a harvested semitendinosus retracted causing a “popeye” deformity



# Medial hamstring regeneration after harvest

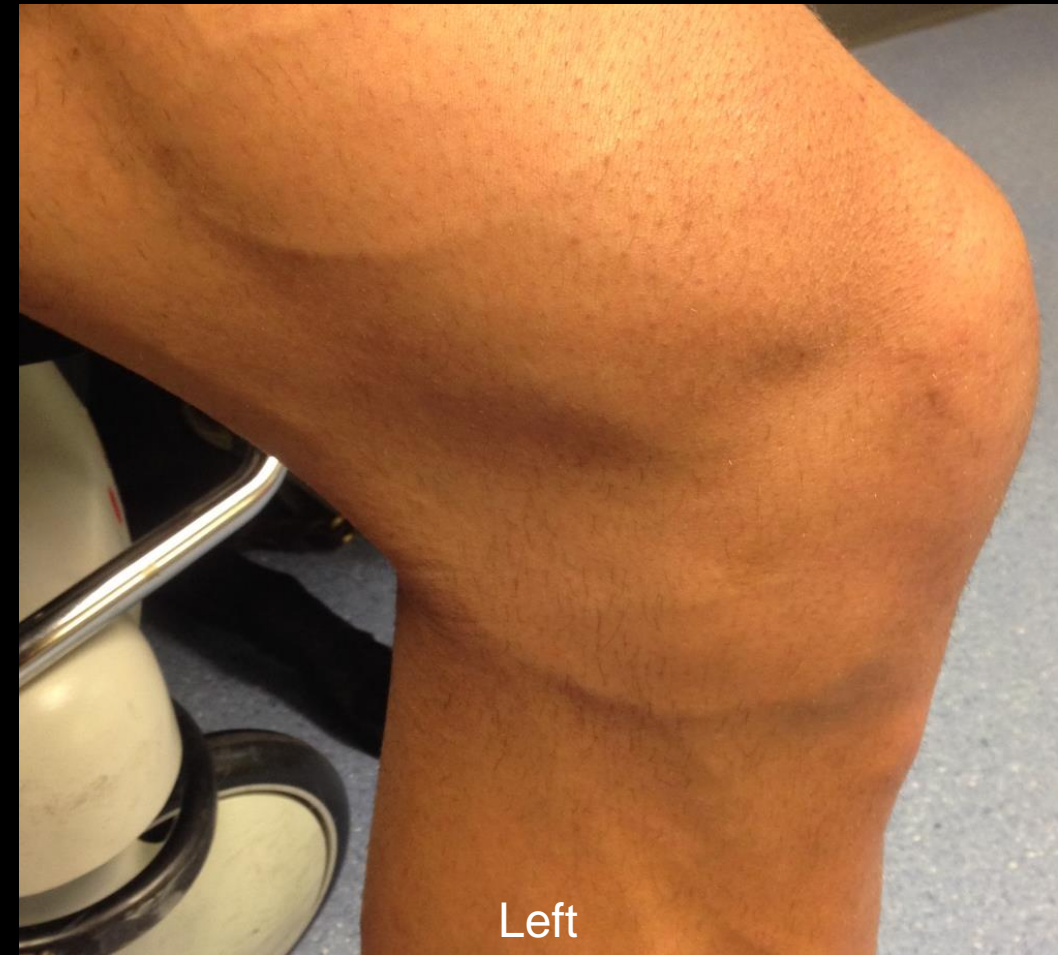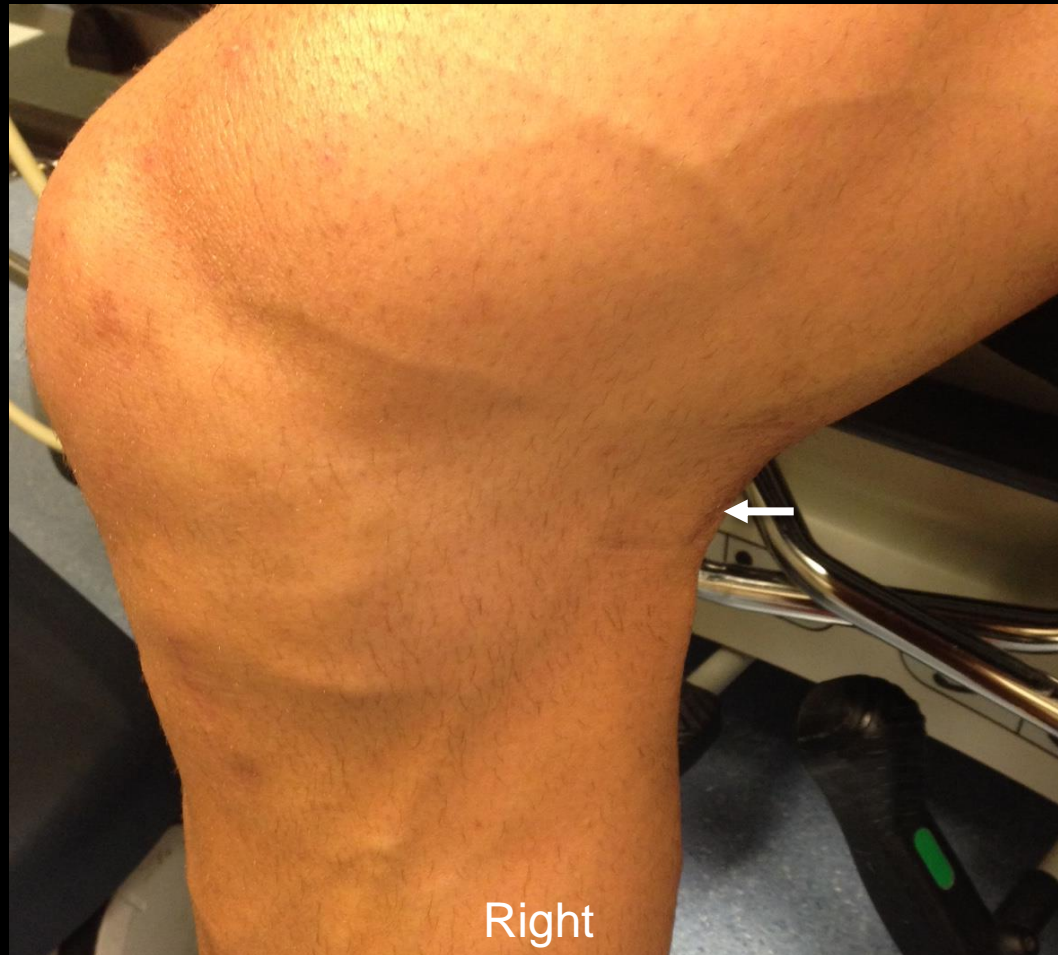- Semitendinosus muscle retraction and fatty atrophy without tendon regeneration after harvesting for ACL reconstruction

Medial hamstring autograft ACL reconstruction in 2003, MRI 2012 for a palpable lump while doing foam roll



# Neotendon injury after ACL reconstruction

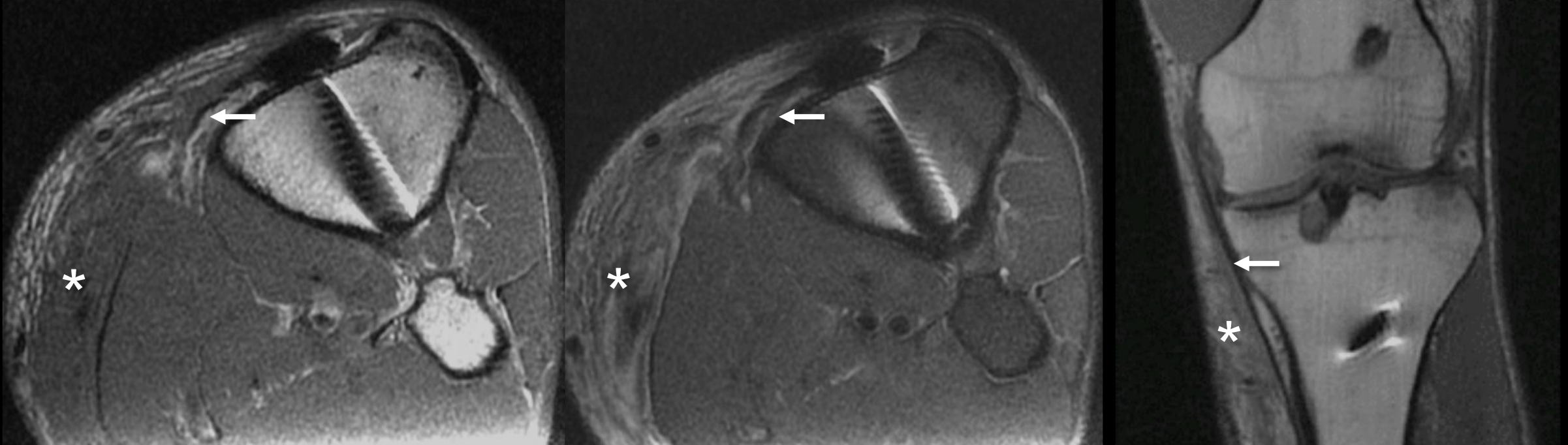
- Runner with prior ACL reconstruction and right posteromedial knee pain after 83 mile run. Note the loss of muscle and tendon definition (white arrows) of the right knee compared with the left.





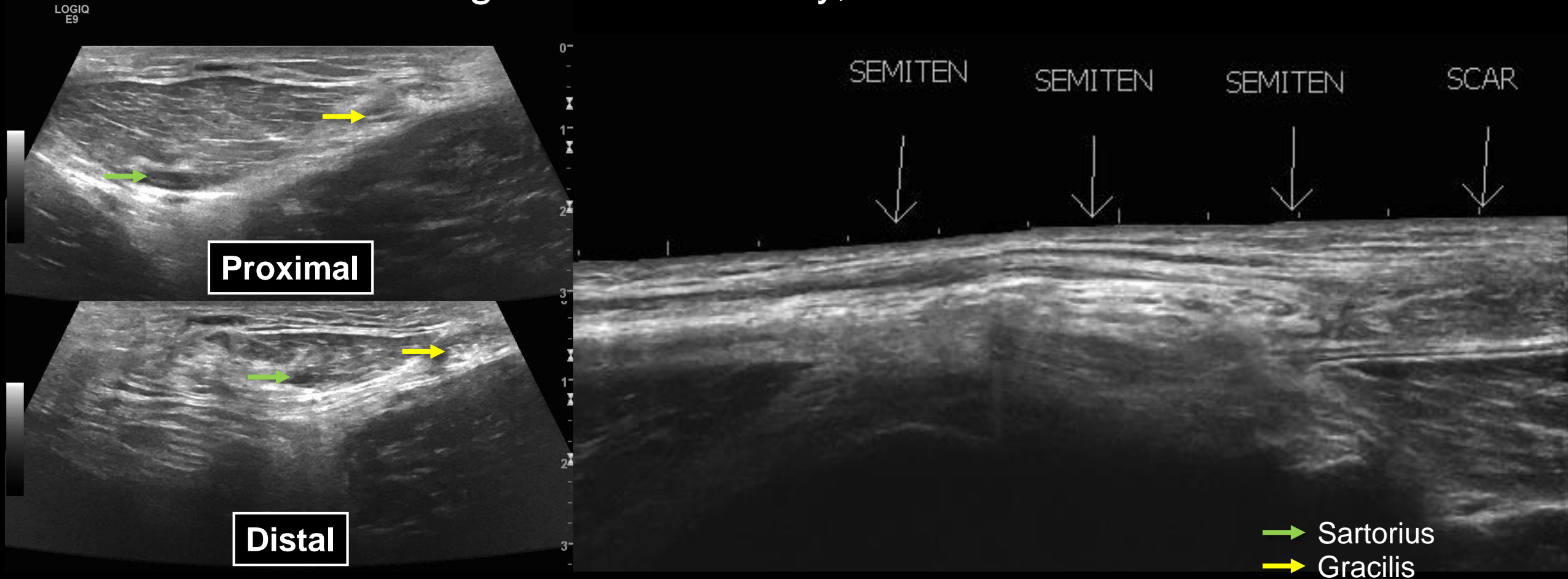
# Neotendon injury after ACL reconstruction

- Pes anserinus is not discernable (white asterisks), consistent with complete tendon tears overlying an intact tibial collateral ligament (white arrows), in this patient status post ACL reconstruction utilizing a hamstring autograft.



# Neotendon injury after ACL reconstruction

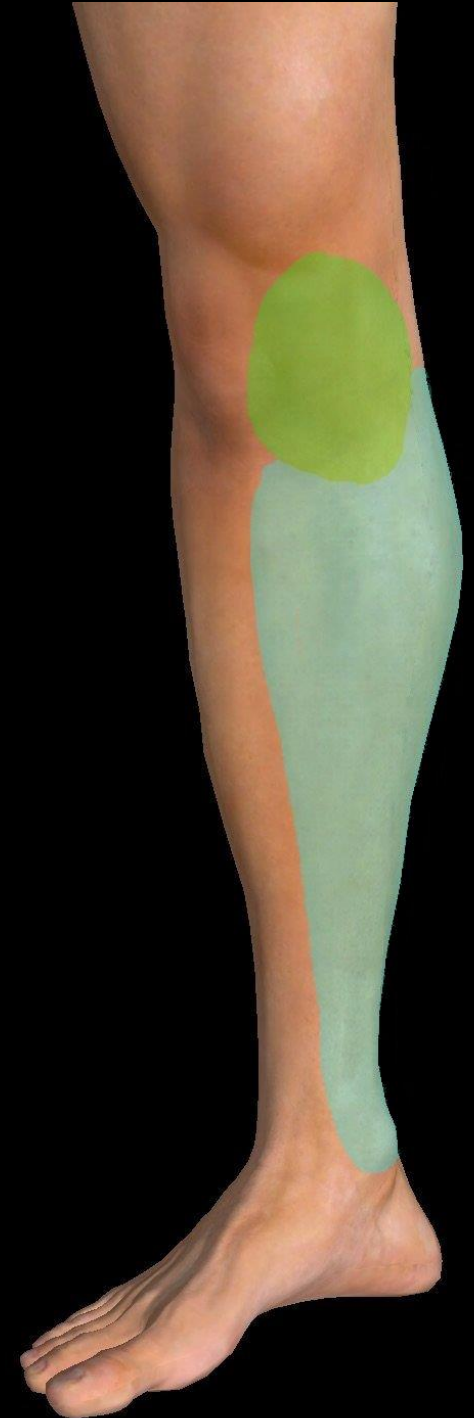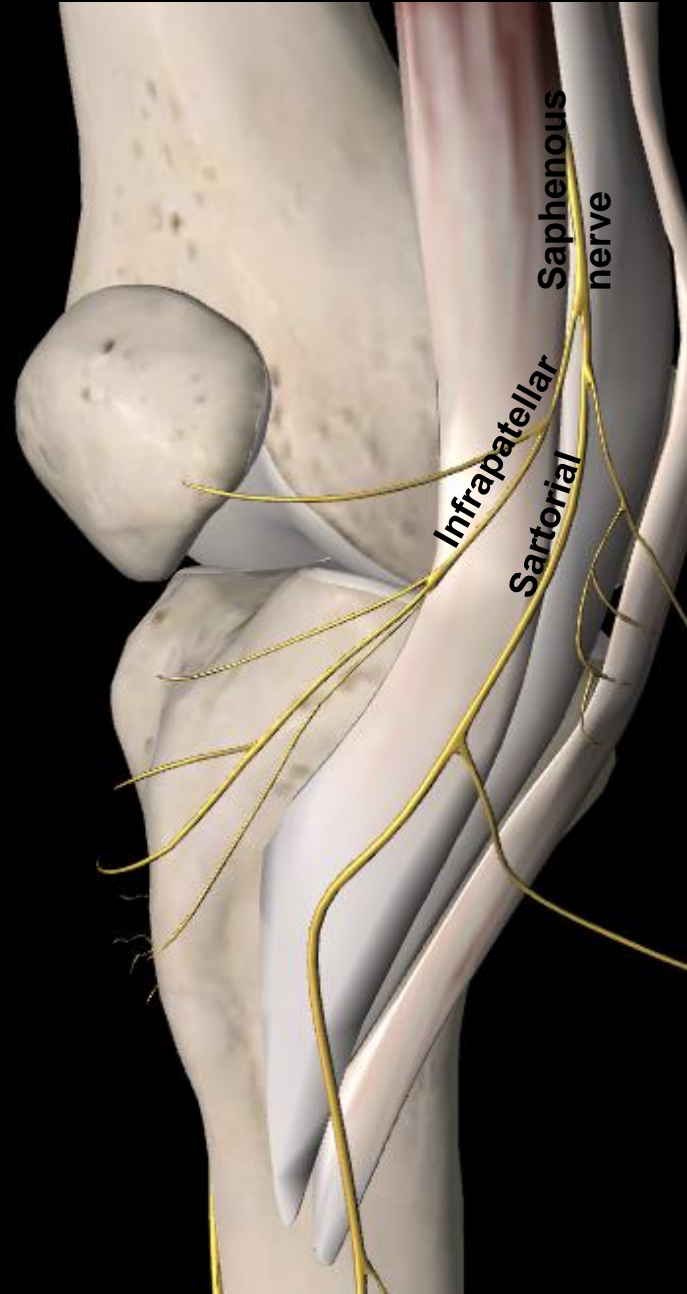
- Short axis (left-sided images) and long axis extended field-of-view (right-sided image) show sartorius, gracilis, and semitendinosus tendons becoming indistinct distally, consistent with tears.





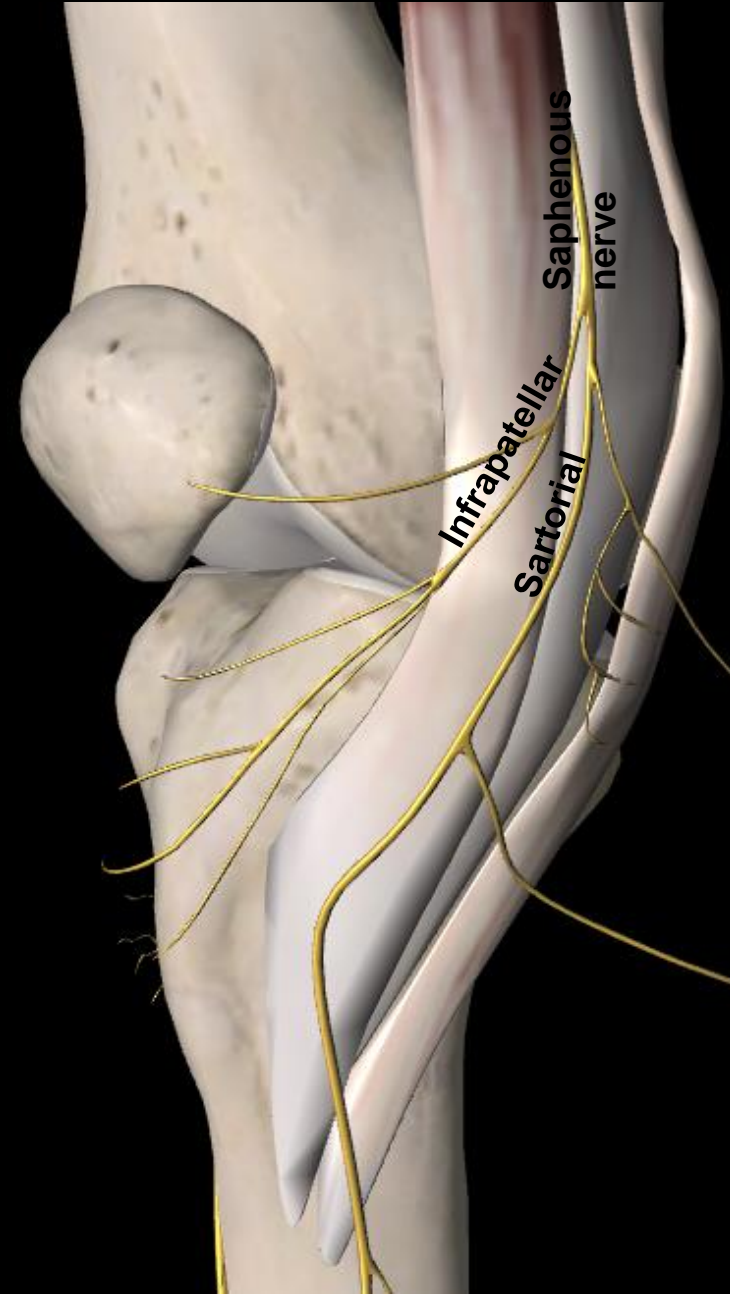
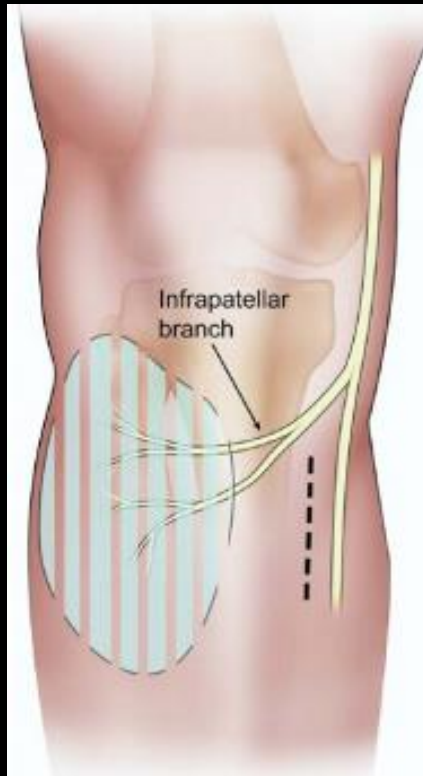
# Saphenous nerve

- Anatomy:
  - Arises from femoral nerve at femoral triangle lateral to vessels
  - Travels through adductor canal, crosses medial to vessels
  - Runs posterior to sartorius (60%)
  - Pierces crural fascia between sartorius and gracilis (43% extrafascial at knee) → subcutaneous following GSV
- Branches
  - Infrapatellar branch (innervation in green)
  - Sartorial branch (innervation in light blue)
- Function:
  - Pure sensory innervation to the medial lower leg



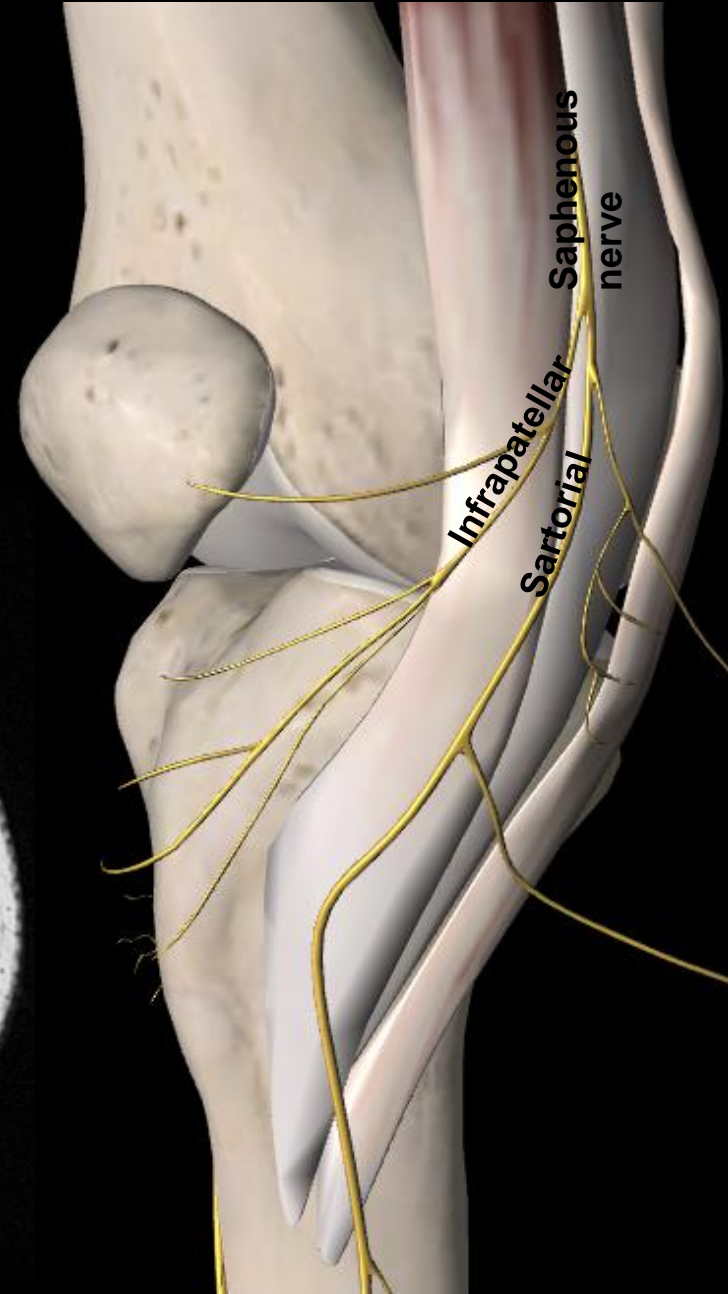
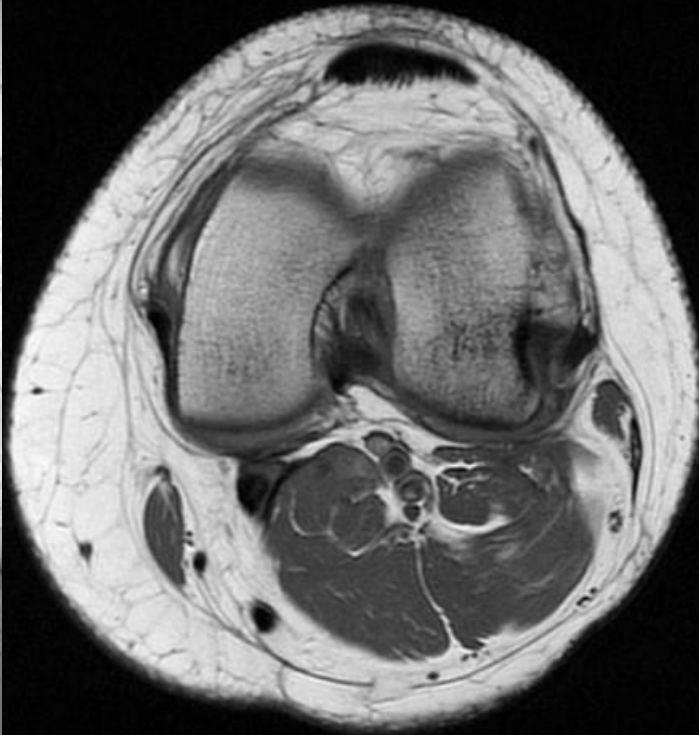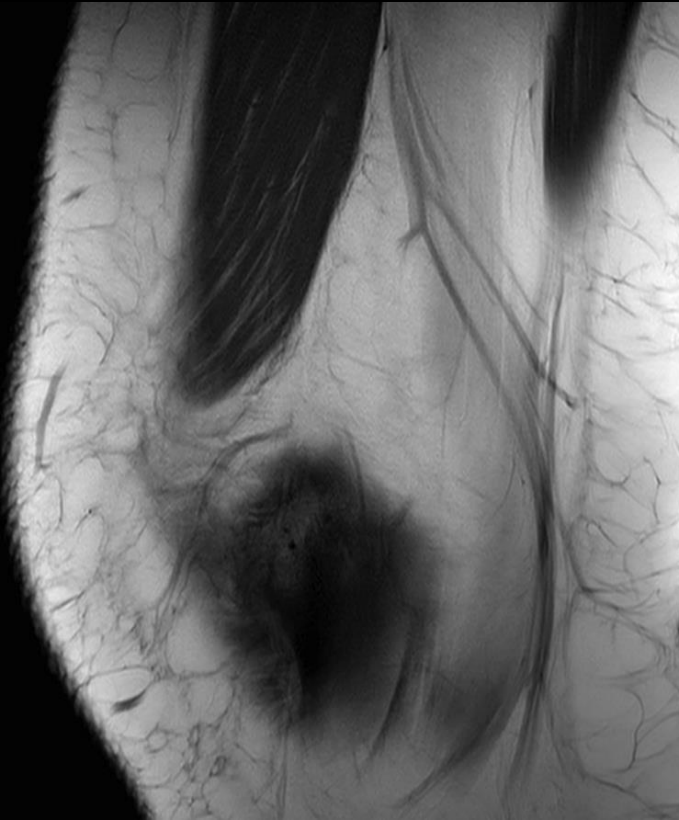# Saphenous nerve injury

- Infrapatellar branch injury during pes anserine access:
  - Incision at pes anserinus can injure IPBSN
  - Risk may be decreased with an oblique incision



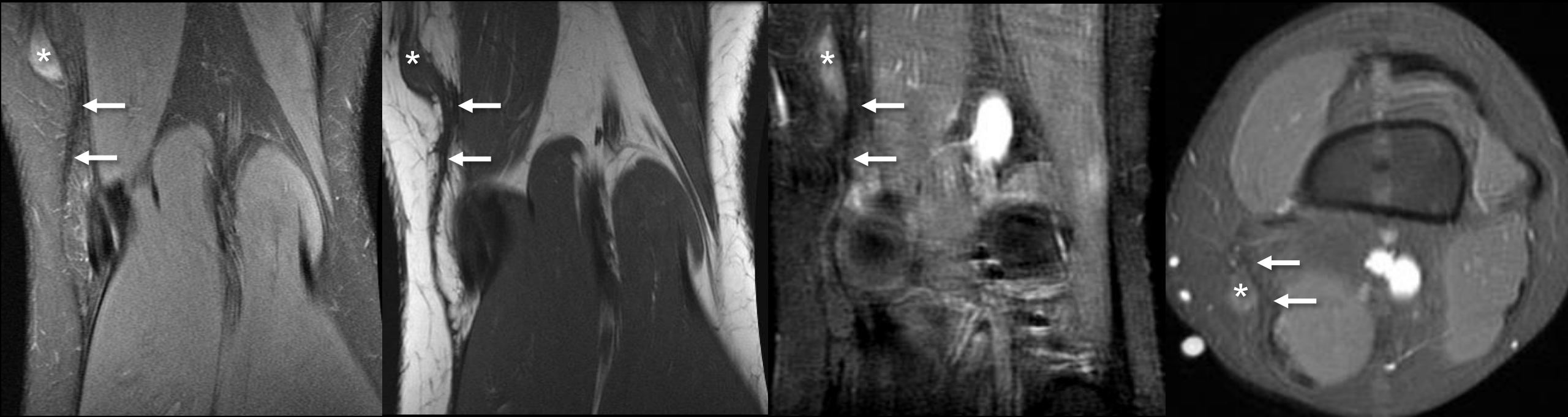
# Saphenous nerve injury

- Sartorial branch may be injured during gracilis tendon harvest:
  - Risk of injury decreased with extremity in “figure of 4” position



# Saphenous neuroma after hamstring harvest

- Saphenous neuroma (white asterisks) with nearby scarring related to a previous hamstring harvest site (white arrows) for ACL reconstruction. This neuroma was subsequently resected with resolution of symptoms.



# Take-home points

- Pes anserinus anatomy is variable but consists of the sartorius, gracilis, and semitendinosus tendons and inserts at the proximomedial tibia superficial to the TCL
- Keen anatomic understanding of the medial knee allows diagnosis of many fluid/cystic pathologies
- Acute injuries of the pes anserinus tendons are often associated with multiligamentous injury, although they can be injured in isolation
- Pes anserinus tendons are commonly harvested for ACL reconstruction, after which tendon regeneration occurs albeit with altered histology and biomechanics



# References

- 3D4Medical. (2017). Essential Anatomy (Version 5.0.6) [Mobile Application Software]. Retrieved from <https://itunes.apple.com>
- Bencardino JT, Rosenberg ZS, Brown RR, et al. Traumatic Musculotendinous Injuries of the Knee: Diagnosis with MR Imaging. *RadioGraphics*. 2000; 20:S103–S120.
- Bergfeld J. First, Second, and Third Degree Sprains. *Am J Sports Med*. 1979;7(3):207-209
- Byers P. et al. Periosteal ganglion. *JBJS* 1970;(52)2
- Carofino B, Fulkerson J. Medial hamstring tendon regeneration following harvest for anterior cruciate ligament reconstruction: fact, myth, and clinical implication. *Arthroscopy*. 2005 Oct;21(10):1257-65.
- Cooper D and Conway J. Semitendinosus ruptures in elite-level athletes. Low success rates of nonoperative treatment. *Am J Sports Med*. 2010;38(6):1174-1178
- Cross MJ et al. Regeneration of the semitendinosus and gracilis tendons following their transection for repair of the anterior cruciate ligament. *Am J Sports Med* 1992;20(2):221-3
- De Maeseneer M, Shahabpour M, Van Roy F, et al. MR Imaging of the Medial Collateral Ligament Bursa: Findings in Patients and Anatomic Data Derived from Cadavers. *AJR*. 2001;177:911–917.
- De Maeseneer M, Van Roy F, Lenchik L, et al. Three Layers of the Medial Capsular and Supporting Structures of the Knee: MR Imaging-Anatomic Correlation. *RadioGraphics*. 2000; S83-S89.
- Dunaway DJ, Steensen RN, Wiand W, et al. The sartorial branch of the saphenous nerve: its anatomy at the joint line of the knee. *Arthroscopy*. 2005 May;21(5):547-51.
- Forbes RJ, Celms CA, Janzen DL. Acute Pes Anserine Bursitis: MR Imaging. *Radiology*. 1995; 194:525-527.
- Hennigan SP, Schneck CD, Mesgarzadeh M, et al. The semimembranosus-tibial collateral ligament bursa. Anatomical study and magnetic resonance imaging. *J Bone Joint Surg Am*. 1994 Sep;76(9):1322-7.
- Indelicato PA. Non-operative treatment of complete tears of the medial collateral ligament of the knee. *J Bone Joint Surg Am*. 1983;65:323-329.
- Ivey M et al. Anatomic variations of the pes anserinus: a cadaver study. *Orthopedics*. 1993; 15(5)
- Jansson KA et al. MRI of anterior cruciate ligament repair with patellar and hamstring tendon autografts. *Skeletal Radiol* (2001) 30:8-14
- Larson ACL reconstruction with hamstring tendons. *op techniques in ortho*. 1996; 6(3):138-146
- Lee J-H, Kim K-J, Jeong Y-G, et al. Pes anserinus and anserine bursa: anatomical study. *Anatomy & Cell Biology*. 2014;47(2):127-131.
- Lee JK, Yao L. Tibial collateral ligament bursa: MR imaging. *Radiology*. 1991; 198: 855-857.

# References

- Lempainen L et al. Distal tears of the hamstring muscles: review of the literature and our results of surgical treatment. *Br J Sports Med* 2007;41:80-83
- Lipscomb AB et al. Evaluation of hamstring strength following use of semitendinosus and gracilis tendons to reconstruct the anterior cruciate ligament. *Am J Sports Med.* 1982;10(6):340-2.
- Lyu SR, Wu JJ. Snapping syndrome caused by the semitendinosus tendon. A case report. *J Bone Joint Surg.* 1989;71(2): 303-305
- Noyes FR et al. Biomechanical analysis of human ligament grafts used in knee-ligament repairs and reconstructions. *J Bone Joint Surg.* 1984;66(3):344-52
- Papageorgiou CD, Gil JE, Kanamori A, Fenwick JA, Woo SL, Fu FH. The biomechanical interdependence between the anterior cruciate ligament replacement graft and the medial meniscus. *Am J Sports Med.* 2001;29:226-231
- Papandrea P et al. Regeneration of the semitendinosus tendon harvested for anterior cruciate ligament reconstruction. Evaluation using ultrasonography. *Am J Sports Med.* 2000;28(4):556-61
- Peltier A, Lording T, Maubisson L, Ballis R, Neyret P, Lustig S. The role of the meniscotibial ligament in posteromedial rotational knee stability. *Knee Surg Sports Traumatol Arthrosc.* 2015;23: 2967-2973
- Rispoli DM et al. Magnetic resonance imaging at different time periods following hamstring harvest for anterior cruciate ligament reconstruction. *Arthroscopy.* 2001;17(1):2-8
- Rothstein CP, Laorr A, Helms CA, Tirman PF. Semimembranosus-tibial collateral ligament bursitis: MR imaging findings. *AJR.* 1996 Apr; 166 (4): 875-7.
- Sanders B, Rolf R, McClelland W, et al. Prevalence of saphenous nerve injury after autogenous hamstring harvest: an anatomic and clinical study of sartorial branch injury. *Arthroscopy.* 2007 Sep;23(9):956-63.
- Schilders E, et al. Partial rupture of the distal semitendinosus tendon treated by tenotomy—a previously undescribed entity. *Knee.* 2006;13(1):45–7.
- Simeone FJ, Huang AJ, Chang CY, et al. Posteromedial knee friction syndrome: an entity with medial knee pain and edema between the femoral condyle, sartorius and gracilis. *Skeletal Radiol.* 2015;44 (4): 557-63.
- Sivasundaram L, Matcuk G, White E et al. Partial semitendinosus tendon tear in a young athlete: a case report and review of the distal semitendinosus anatomy. *Skeletal Radiol.* (2015) 44:1051–1056.
- Warren LF, Marshall JL. The supporting structures and layers on the medial side of the knee: an anatomical analysis. *J Bone Joint Surg Am.* 1979 Jan;61(1):56-62.
- Wijdicks CA, et al. Structural properties of the primary medial knee ligaments. *Am J Sports Med.* 2010 Aug;38(8):1638-46
- Wittstein J, Wilson J, Moorman C. Complications Related to Hamstring Tendon Harvest. *Oper Tech Sports Med.* 14:15-19.

# Thank you

Edward Smitaman, M.D.

Brady K. Huang, M.D.

Mini N. Pathria, M.D.

Contact information:

Brian Curtis: [brcurtis123@gmail.com](mailto:brcurtis123@gmail.com)