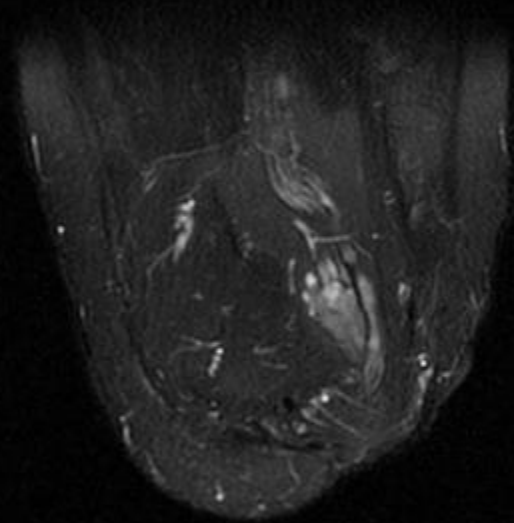
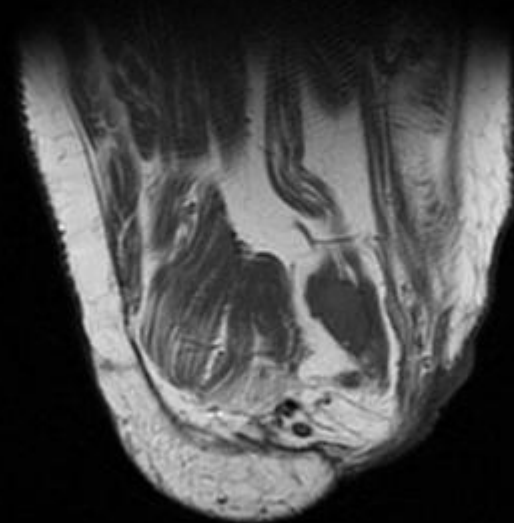
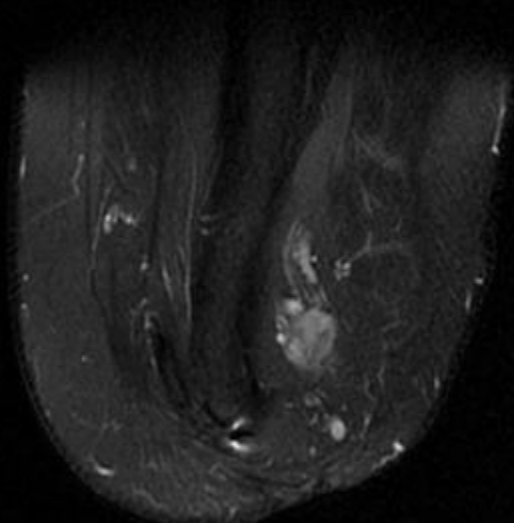
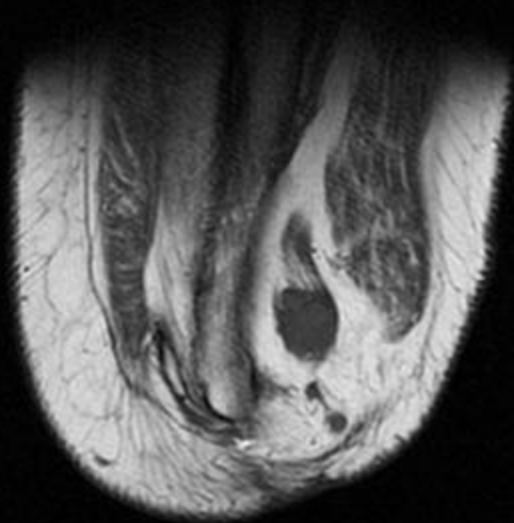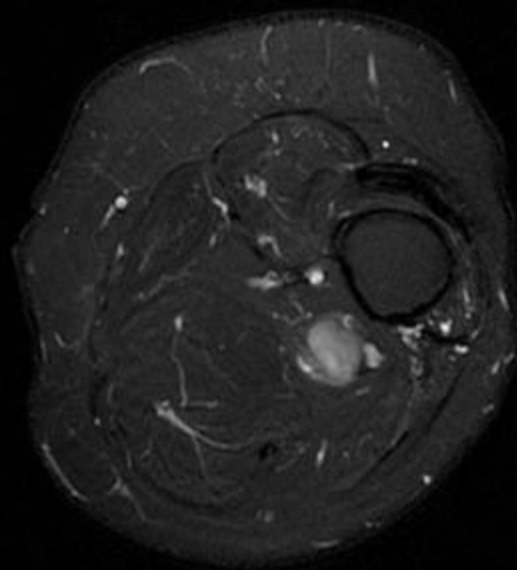
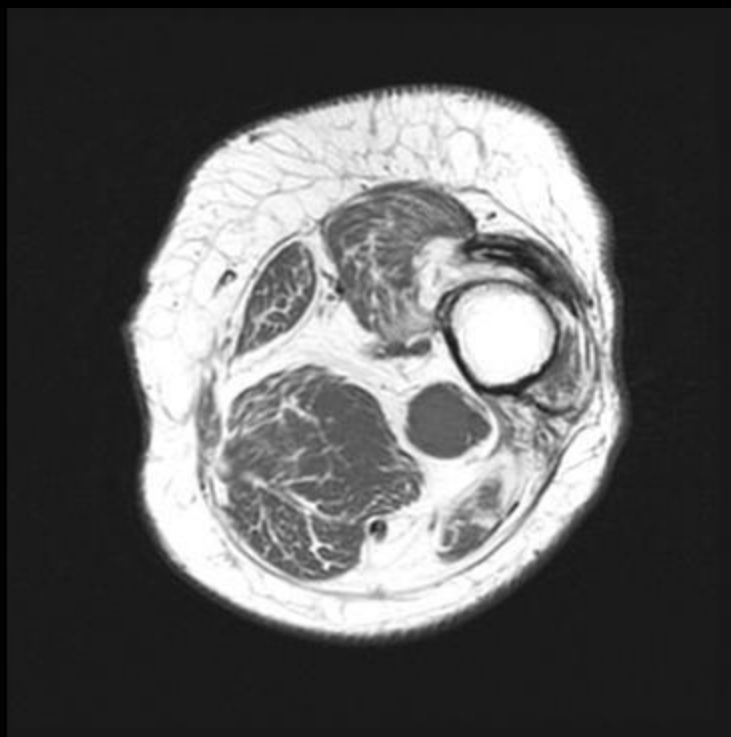




59 yo male with left aka after MVA
in 1993, complaining of a “lump”

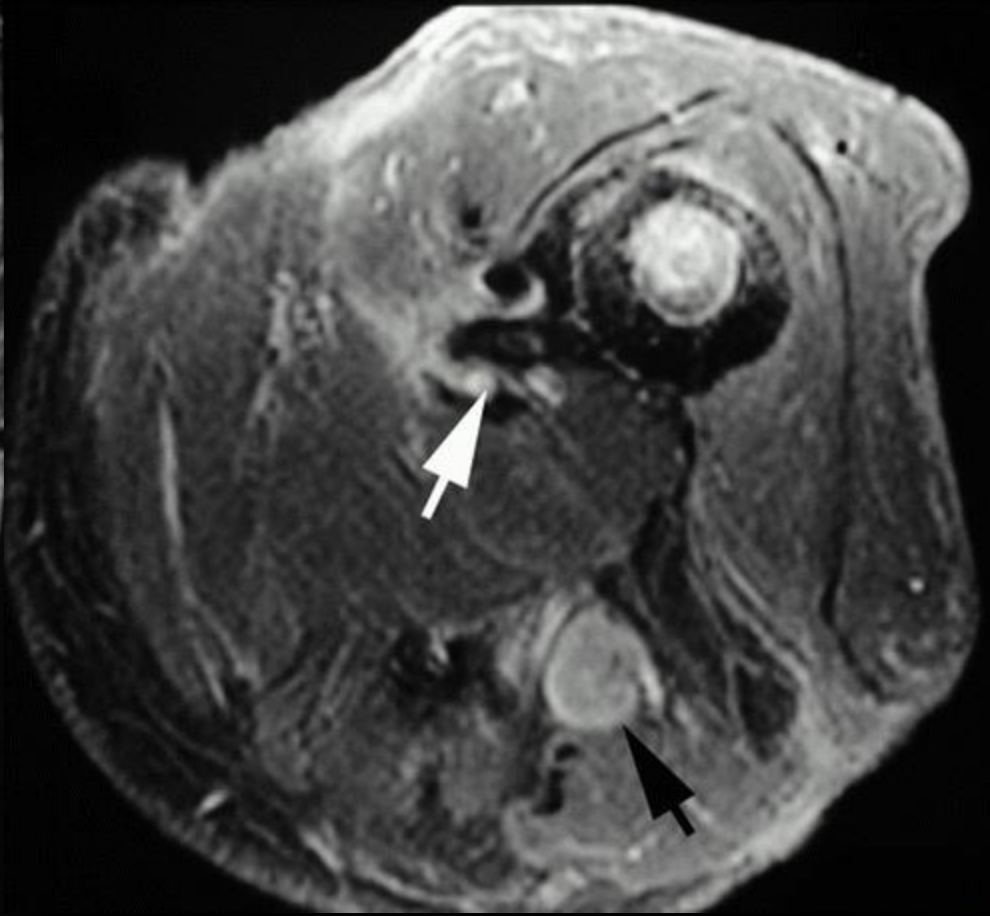
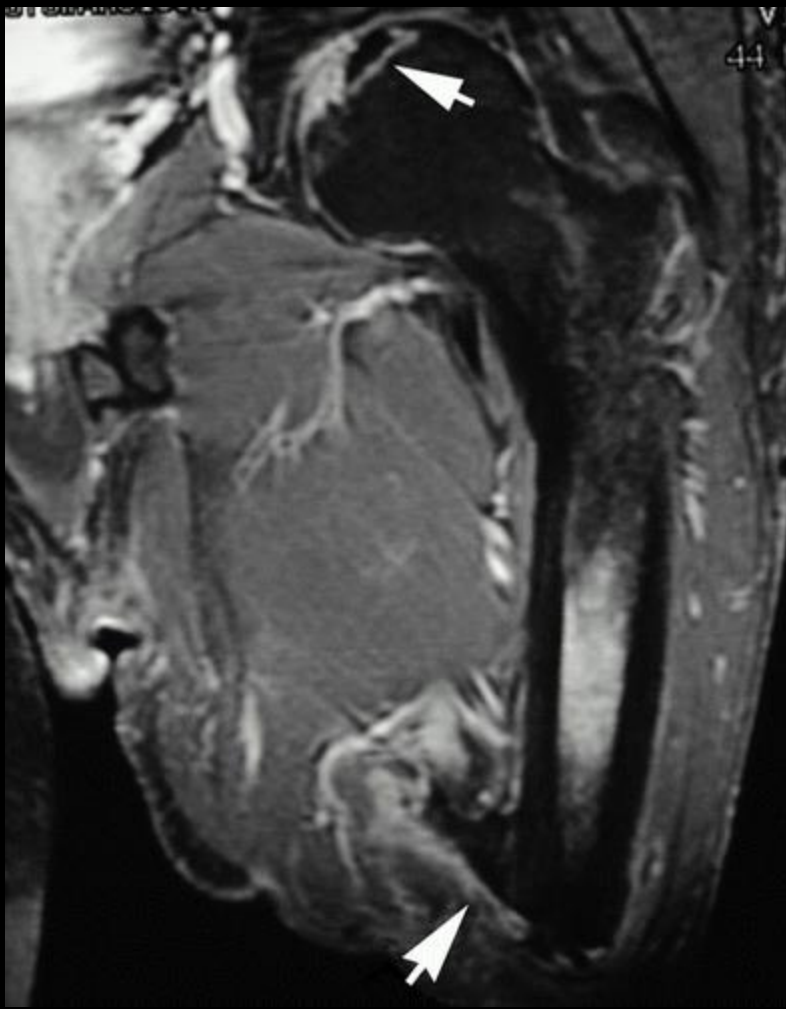
Ted Su





Causes of non-prosthesis induced stump pain

- Aggressive bone edge
- Heterotopic ossification
- Osteomyelitis
- Cancer/tumor recurrence
- Neuroma
 - Occurs at the end of a nerve and usually 1-12 months after amputation



Blum, et al. Radiographics

Stump neuroma

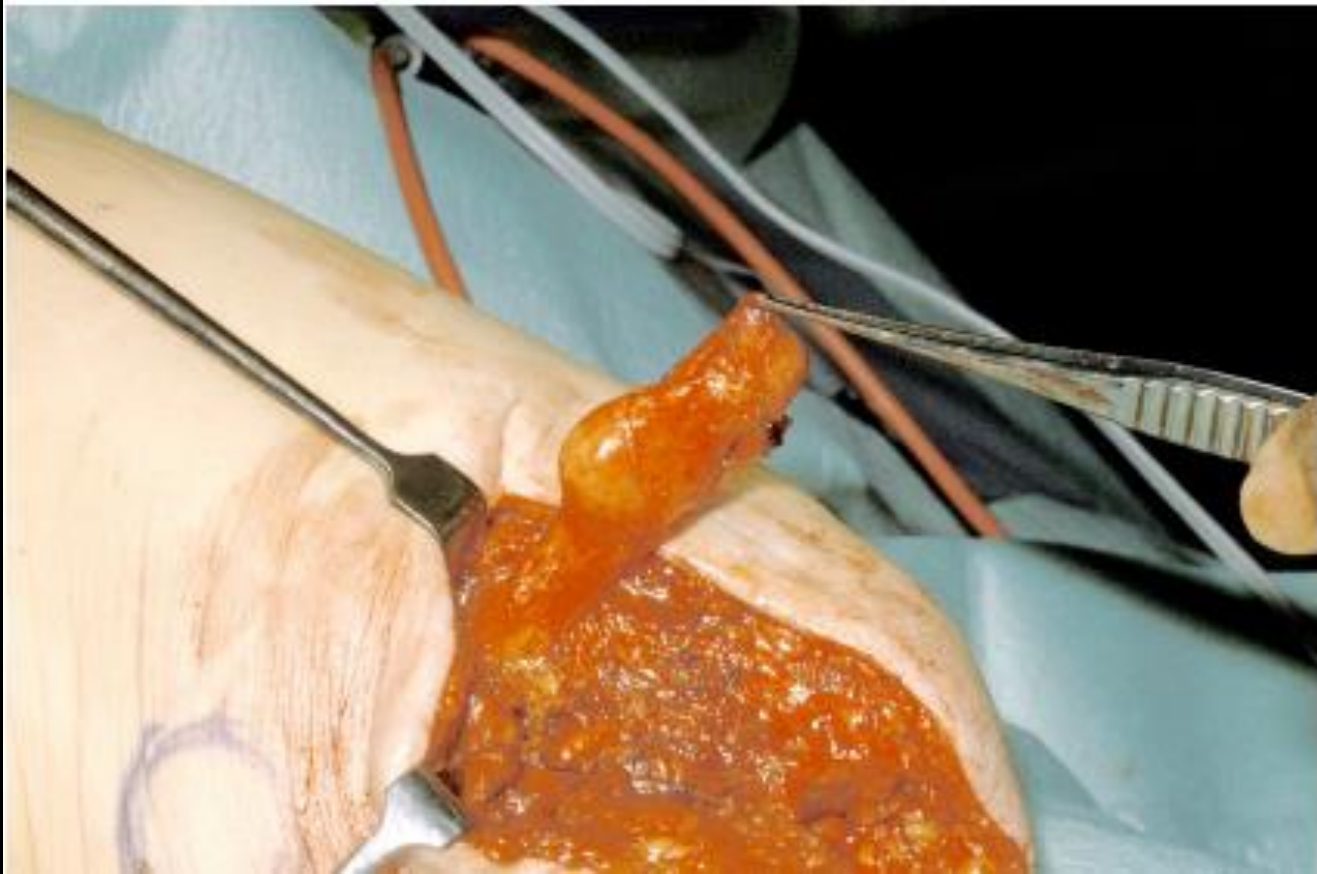- 2 types
- Spindle neuroma
 - Localized in the nerve away from the severed nerve ending
 - Response of peripheral nerve subject to microtrauma due to stretching or compression by localized scar tissue
- Terminal neuroma:
 - Originates at the end of severed nerve
 - Due to proliferation of axons in any direction w/out support of Schwann cells

Stump neuroma

- Pain may be difficult to distinguish from phantom pain
- Clinical findings: normal vs soft tissue mass
- Pain can occur from tapping (Tinel's)
- Pain relief with lidocaine can help confirm
- Usually 1.0-3.5 cm
- Sciatic neuromas easier to detect
- Low on T1, intermediate/high on T2
- Variable enhancement
- US: pseudocystic hypoechoic mass, irregular/poorly def. margins

Stump neuroma


- Prevention: surgeon should cut and pull the nerve to induce retraction (away from muscular-cutaneous scar)
- Conservative therapy useful in >50%
- Corticosteroids or nerve stimulation, or reshaping socket can relieve pain
- Resection may not help; can induce extension of scar area with potential of generating a new neuroma
- Alcohol sclerotherapy, induces neurolysis



M. Kitcat et al, Open Orthopedics Jrnl

References

1. Blum, A et al. Imaging of the Painful Lower Limb Stump. *Radiographics*, vol 20 suppl 1 Oct 2000
2. Kitcat, M et al. Sciatic Neuroma Presenting 40 Years After Above-Knee Amputation. *The Open Orthopedics Journal*, 3:125-27. 2009.
3. Kim, J et al. Sonographically Guided Alcohol Injection in Painful Stump Neuroma. *Ann Rehabilitation Medicine* 36(3):404-408. Jun 2012



"Still, let's do an x-ray just to be sure."