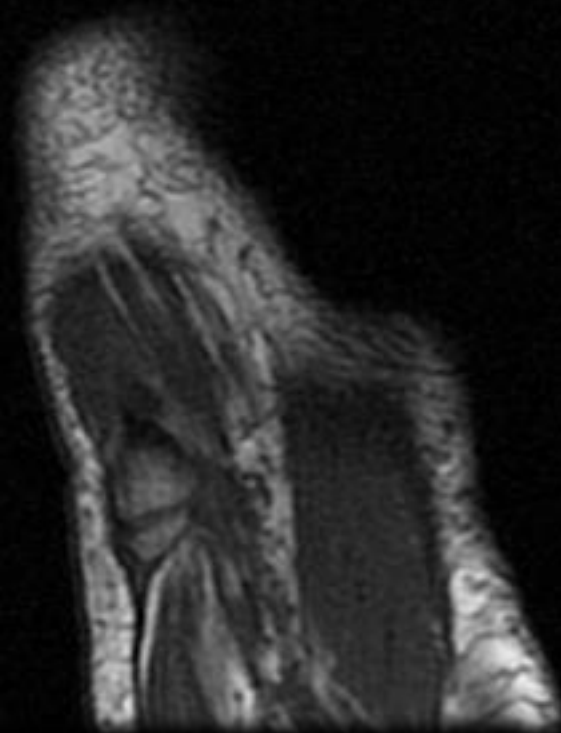
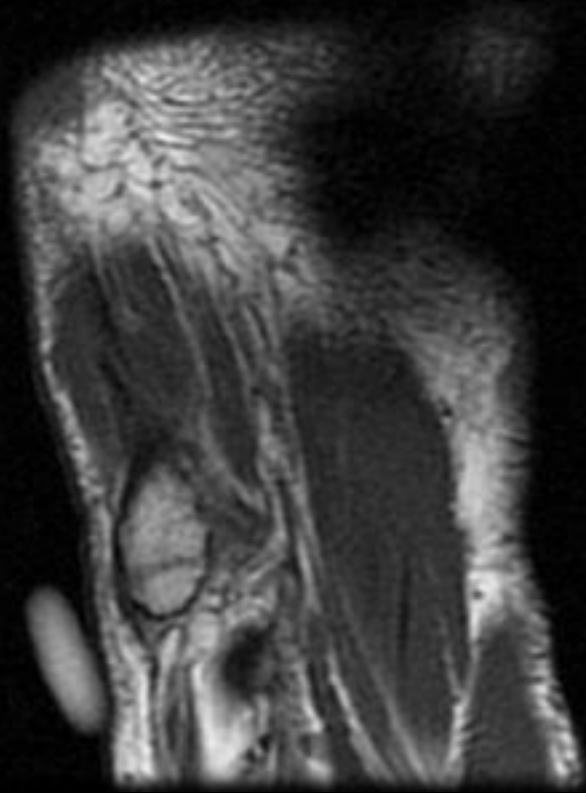
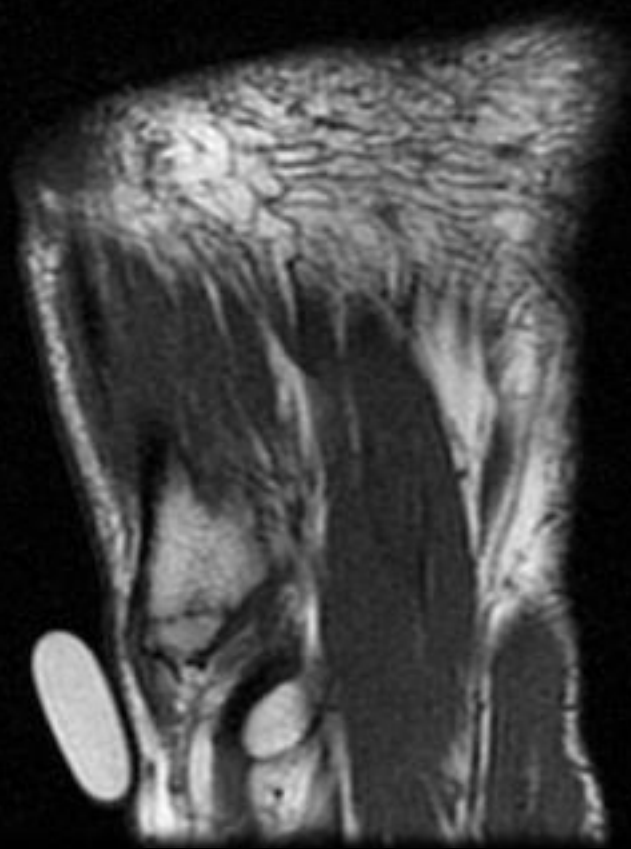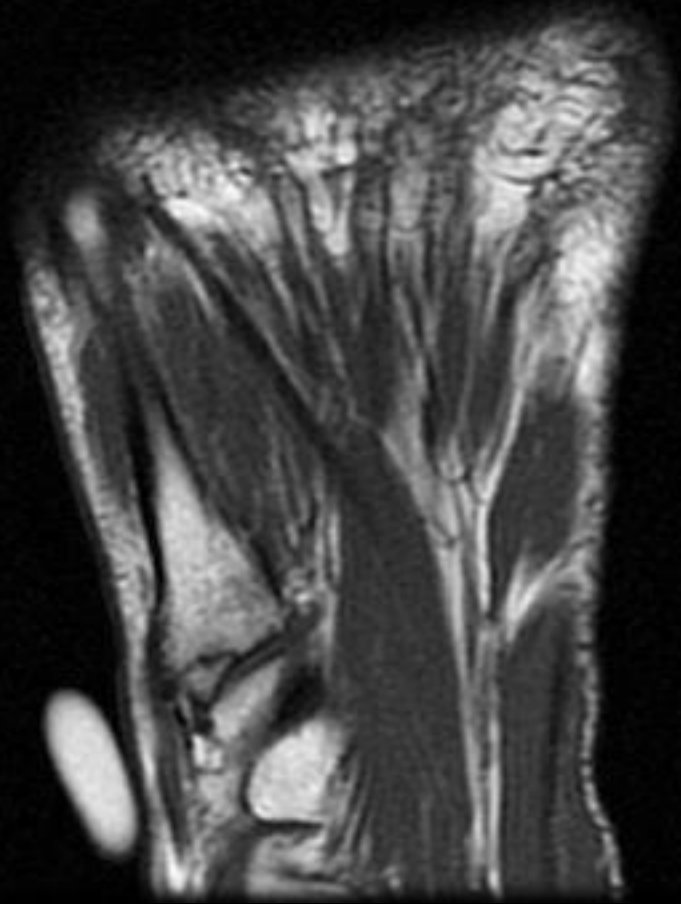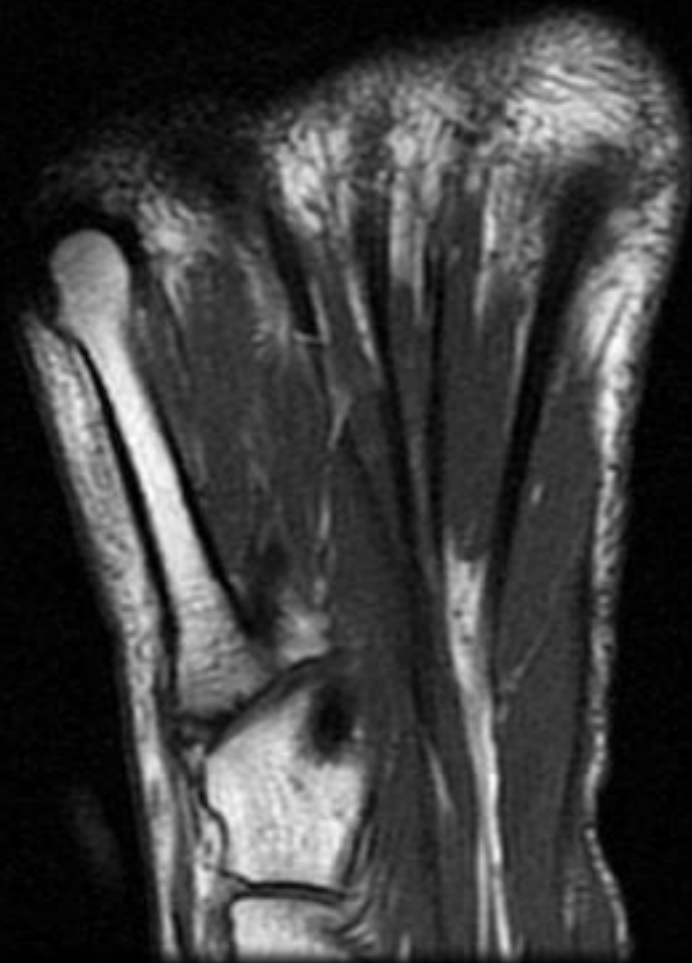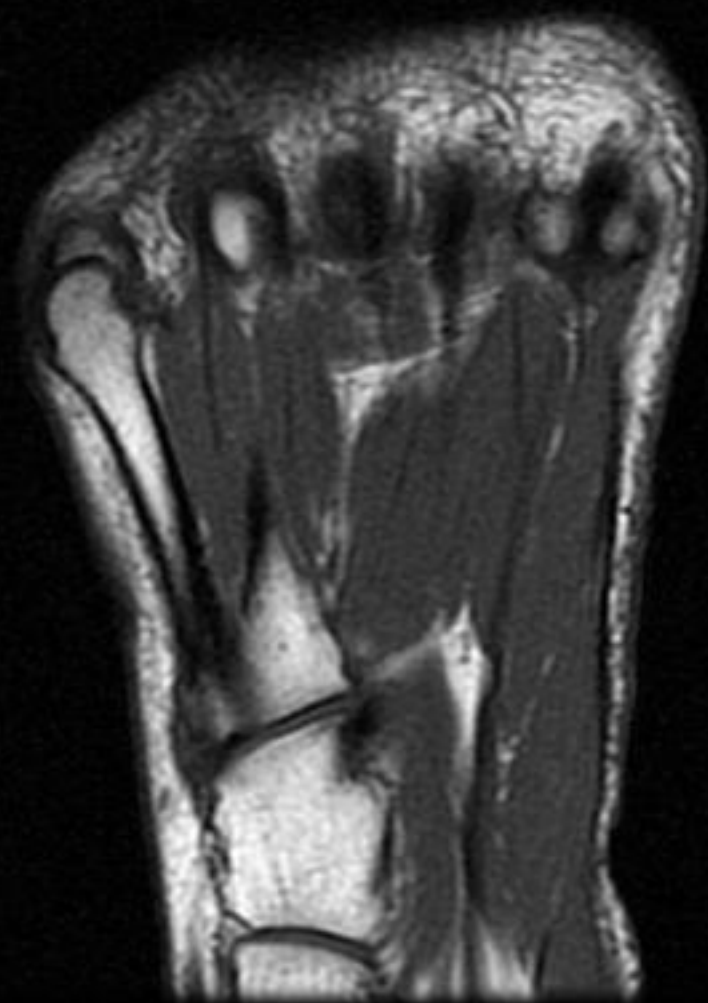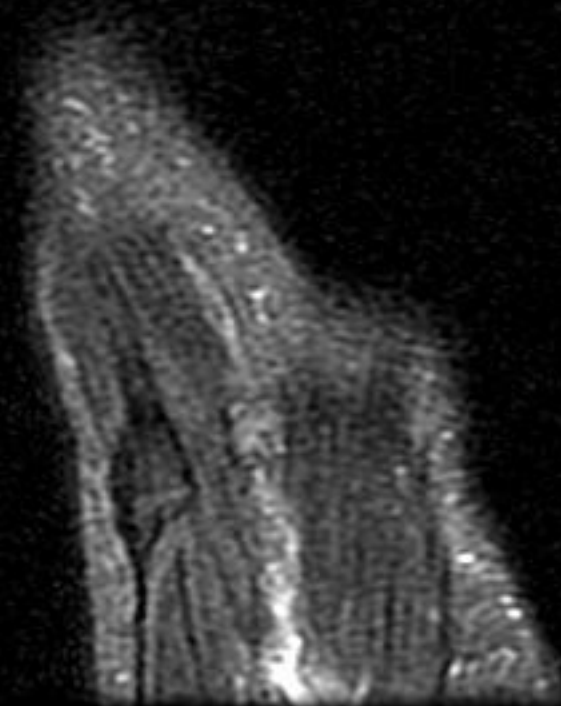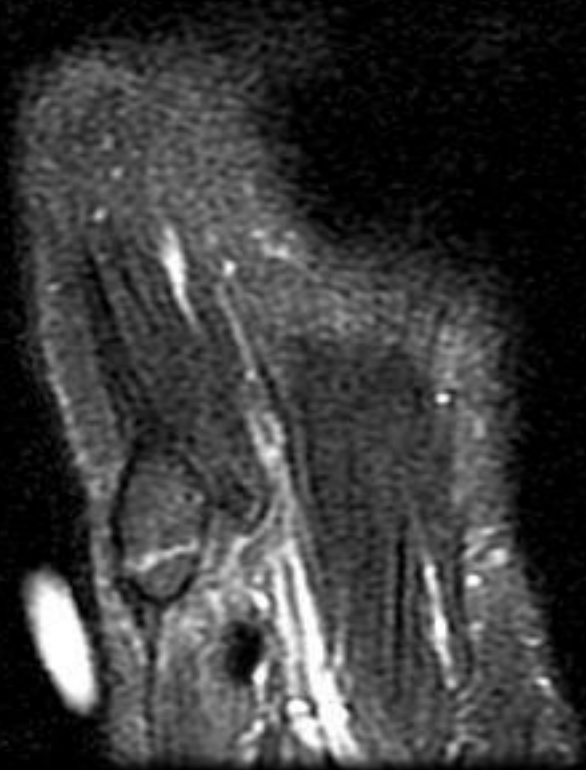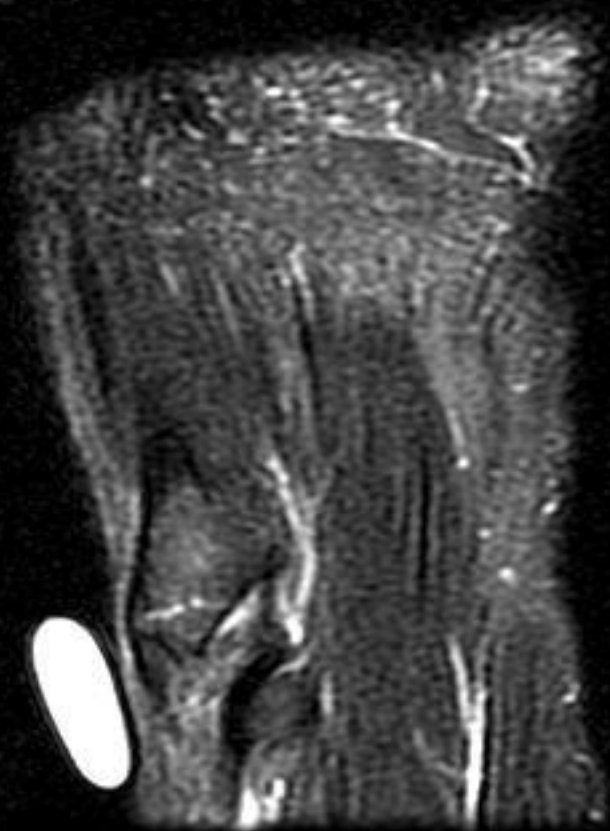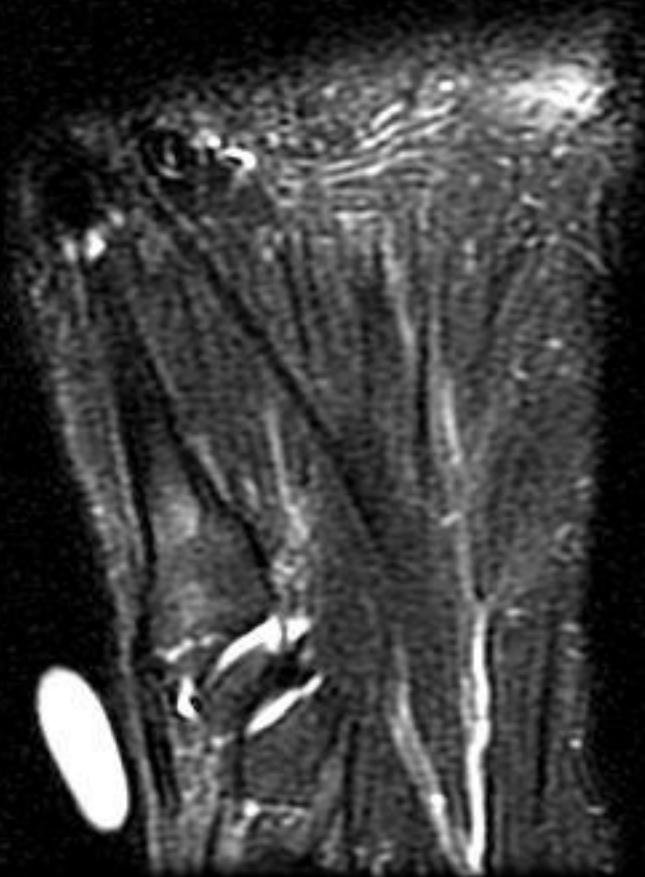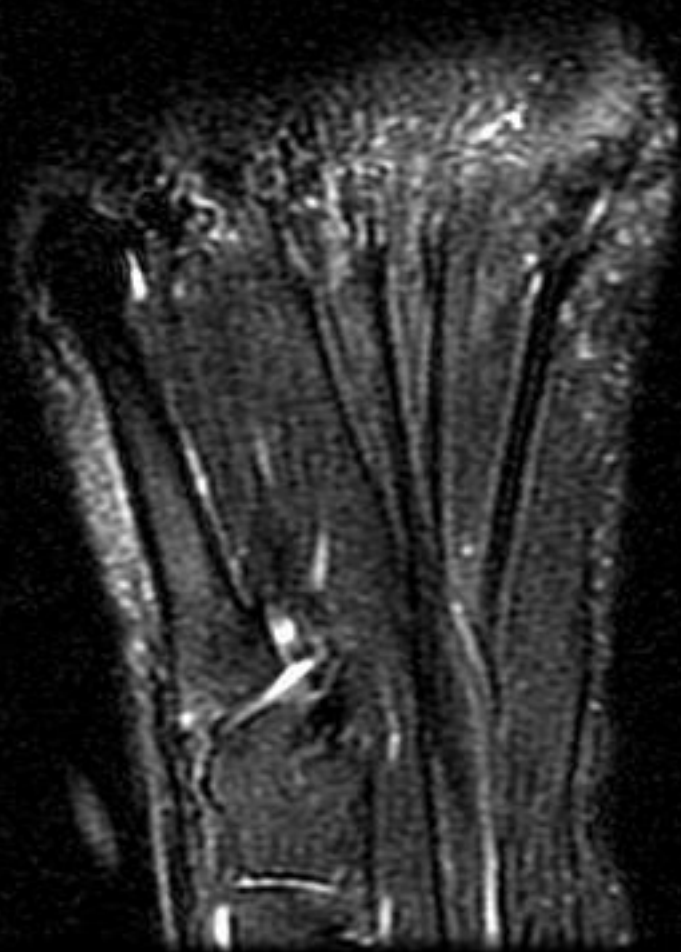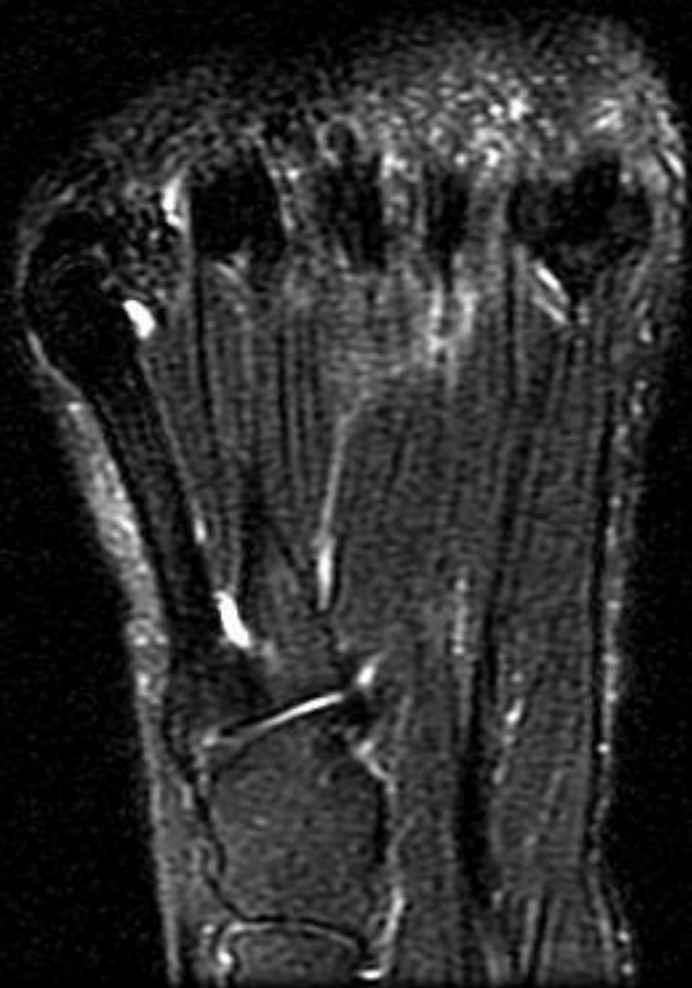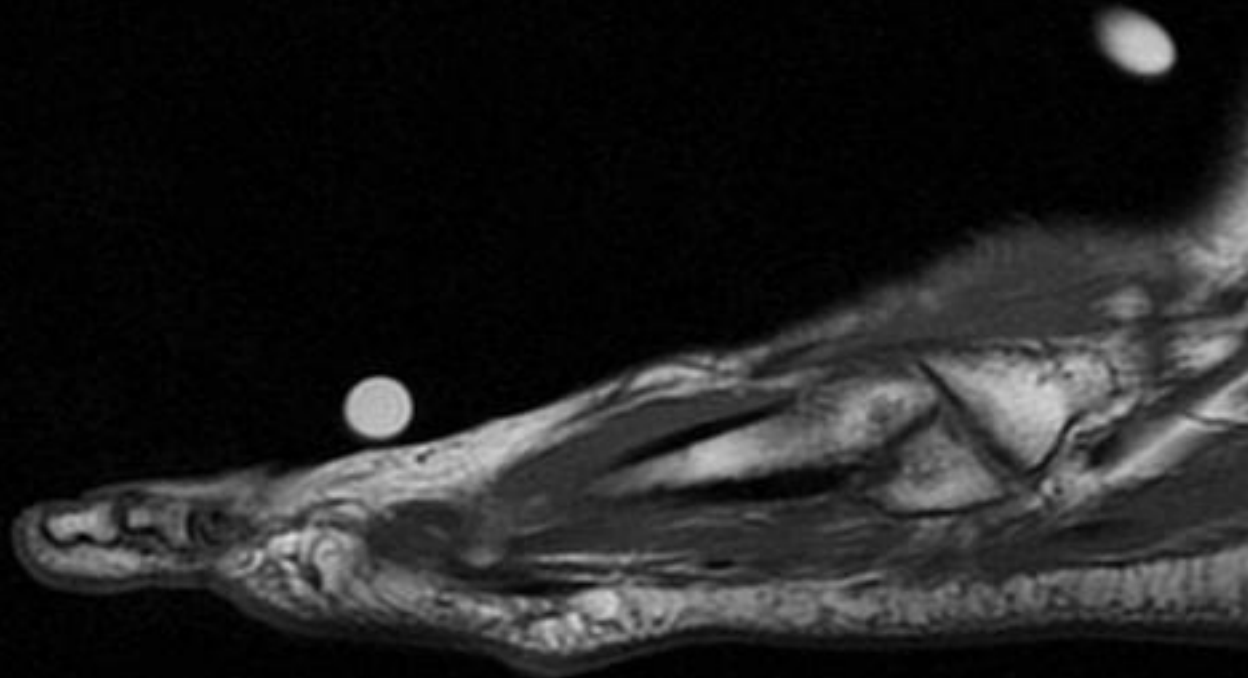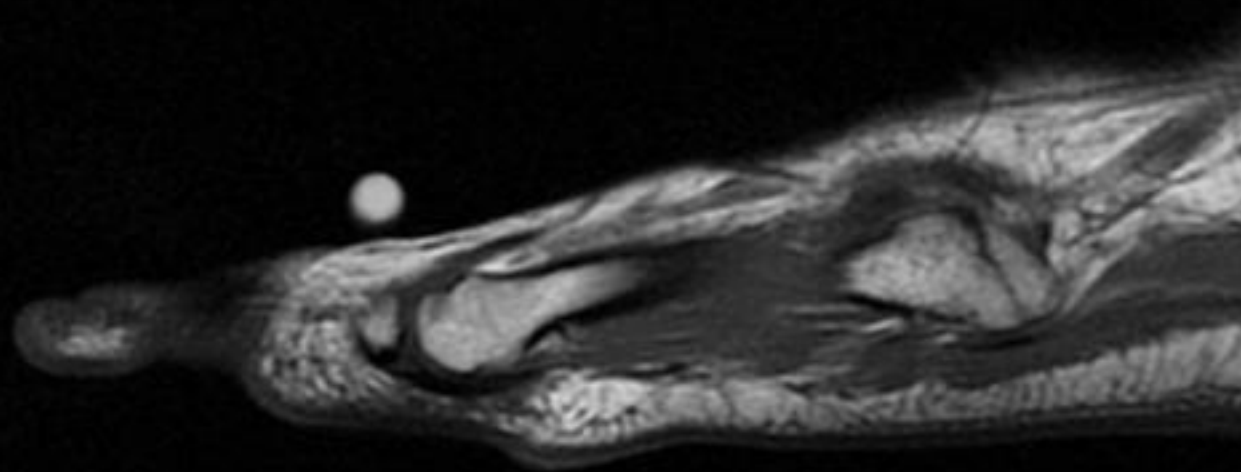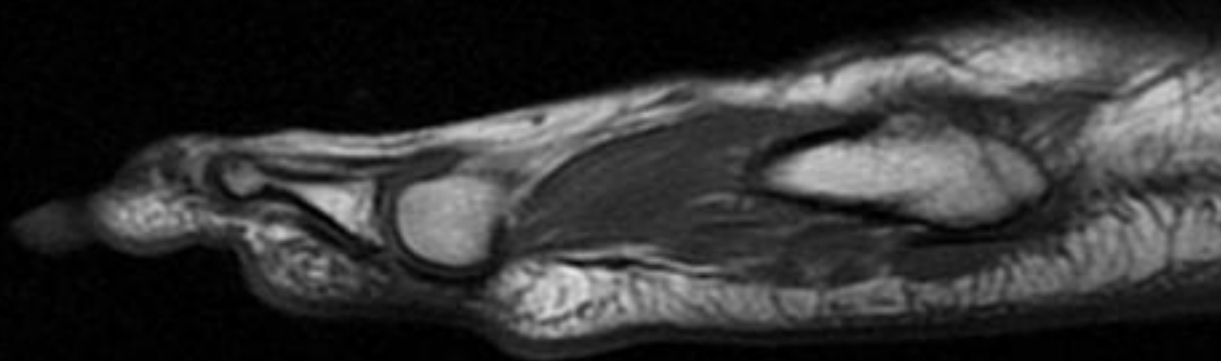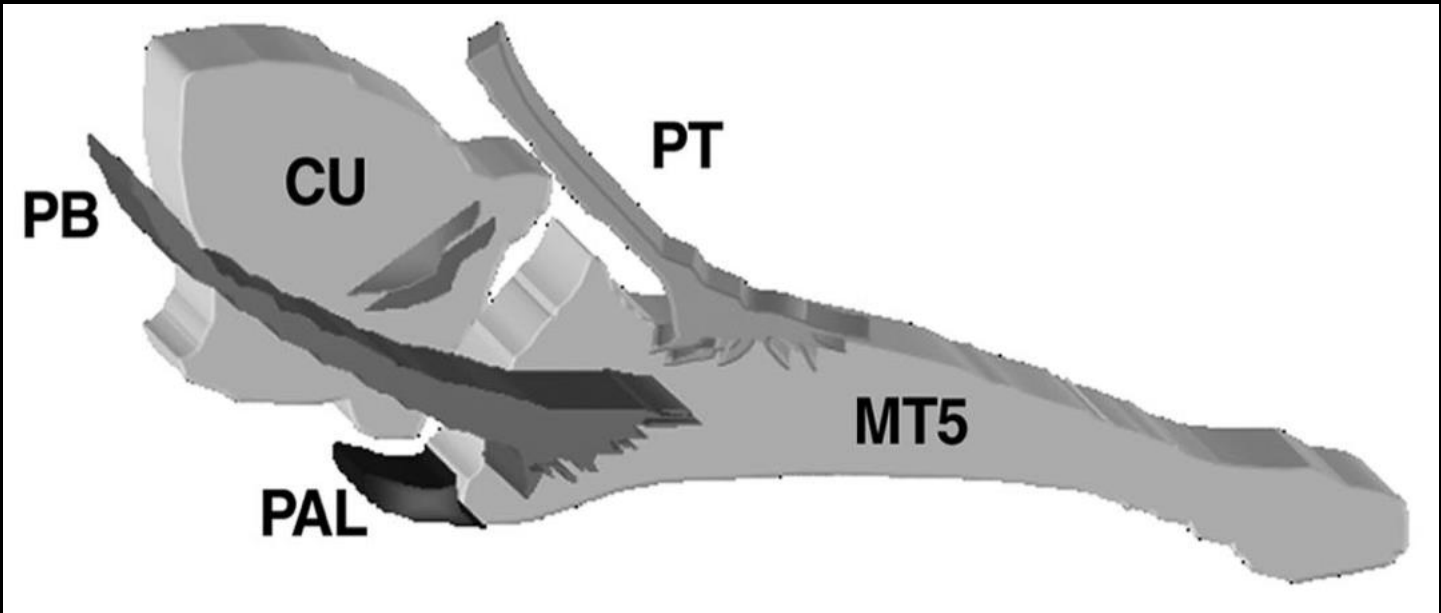
Finding:

- Nondisplaced subacute vs remote fracture of the base of the 5th MT at the attachment site of the lateral cord of the plantar aponeurosis.
- Adjacent thickening of the distal peroneus brevis tendon fibers near its metatarsal attachment.

Theodorou D.J., Theodorou S.J., Kakitsubata Y., Botte M.J., Resnick D.
Fractures of proximal portion of fifth metatarsal bone: anatomic and imaging evidence of a pathogenesis of avulsion of the plantar aponeurosis and the short peroneal muscle tendon. Radiology. 2003 Mar;226(3):857-65.


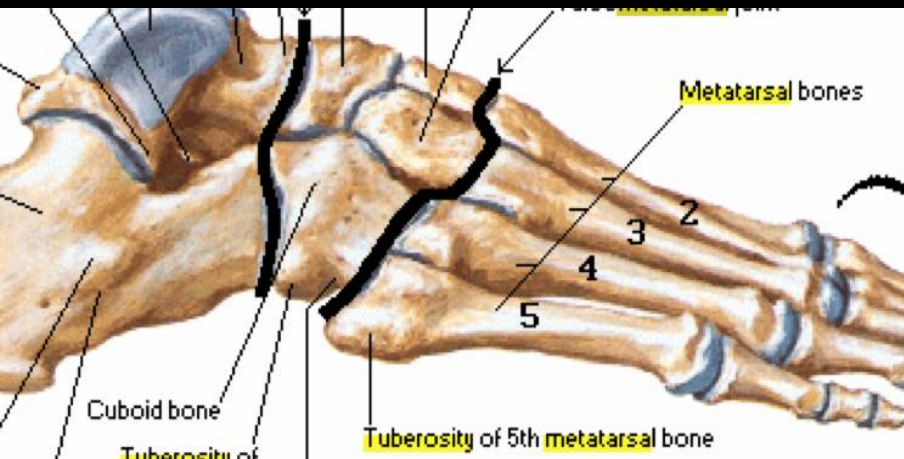
- Evaluated the normal anatomy of the supporting structures of the proximal portion of the 5th MT and investigated the pathogenesis of different fracture types in this region

- 2 cadaveric feet dissected for:
 - The lateral component of the plantar aponeurosis (PAL)
 - peroneus brevis = short peroneal muscle tendon (PB)
 - Peroneus tertius = third peroneal muscle (TPM)
- 4 cadaveric feet were sectioned
- 6 cadaveric feet were scanned (MR, CT)
- 2 specimens – simulated base of 5th MT Fx
- 13 patients with Fx of the proximal 5th MT – evaluated the radiographic, CT, and MR images



Three fracture zones:

- Three fracture types in the proximal portion of the fifth metatarsal bone:
 - Jones fracture (2) - delayed union or nonunion 2/2 poor blood supply
 - tuberosity avulsion fracture (1)
 - diaphyseal stress fracture (3)



Results:

- Broad insertion of the PAL into the plantar aspect of the proximal portion of the fifth metatarsal bone
- SPM tendon was consistently attached more distally and to the lateral side of the tuberosity, blending with the PAL fibers
- TPM tendon was inconsistently identified inserting anteriorly to the SPM tendon
- Frequent attachment of the PAL and the SPM tendon to the avulsed fragment was confirmed in clinical cases.

Summary:

- Not all 5th MT base Fx are Jones Fx
 - Jones Fx - at the junction of the diaphysis and the metaphysis, between the insertion of the TPM and SPM tendons
 - Tuberosity avulsion Fx (the most common) – role of PAL
 - Stress Fx (the least common) - within the proximal 1.5 cm of the fifth metatarsal diaphysis

References

1. Theodorou D.J., Theodorou S.J., Kakitsubata Y., Botte M.J., Resnick D. **Fractures of proximal portion of fifth metatarsal bone: anatomic and imaging evidence of a pathogenesis of avulsion of the plantar aponeurosis and the short peroneal muscle tendon.** Radiology. 2003 Mar;226(3):857-65.