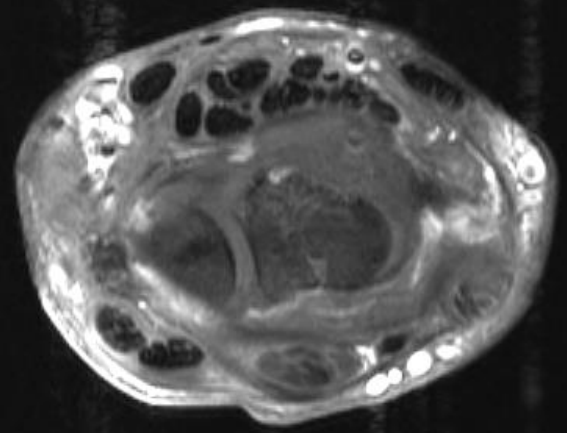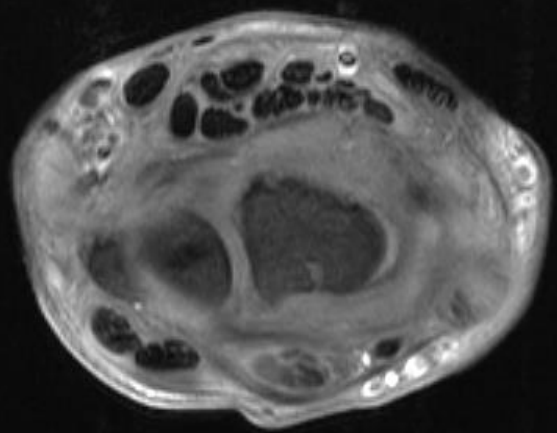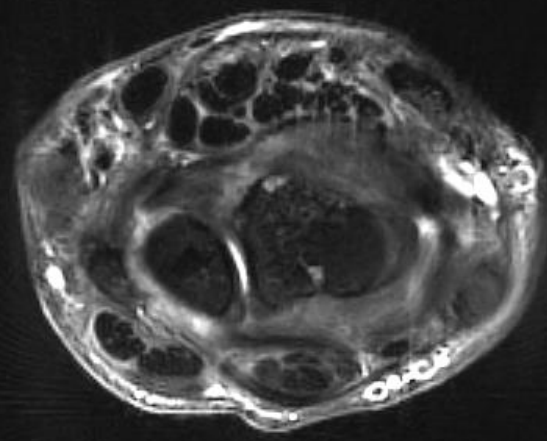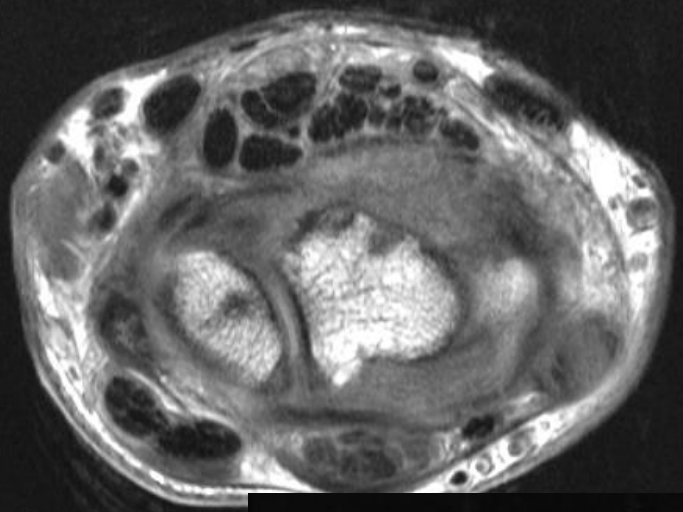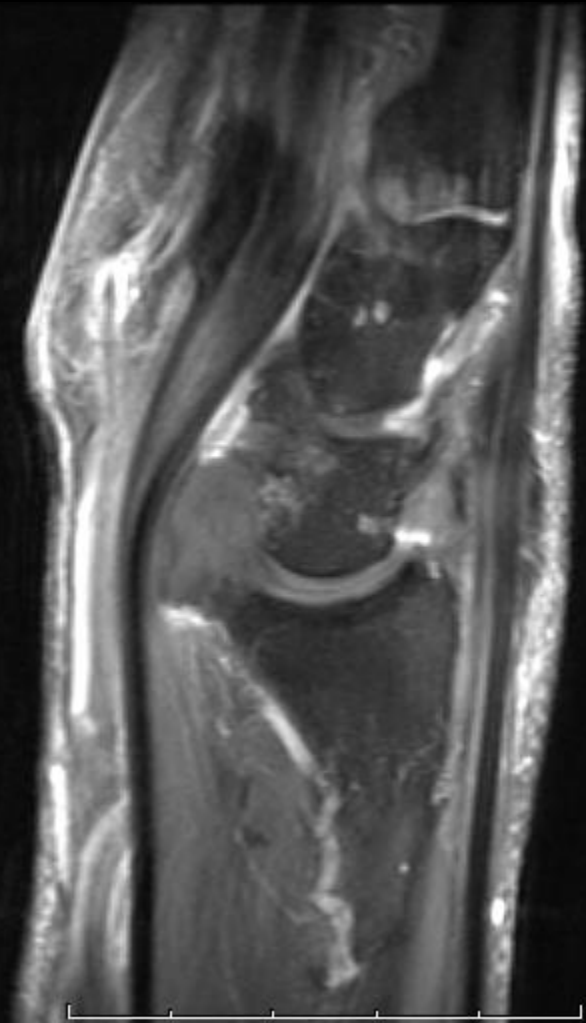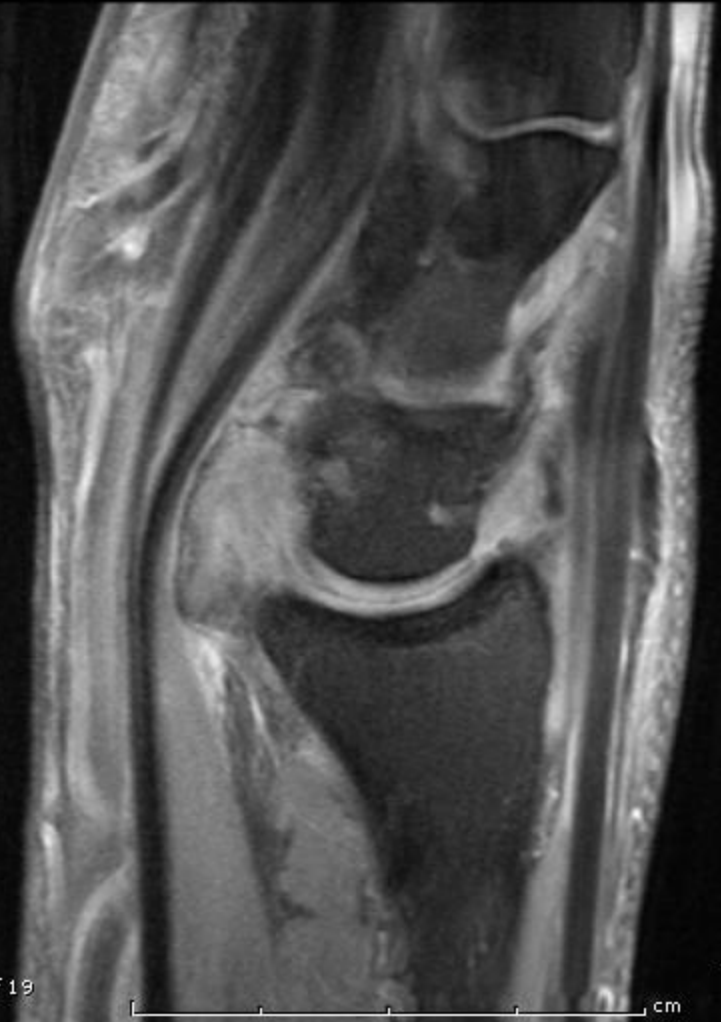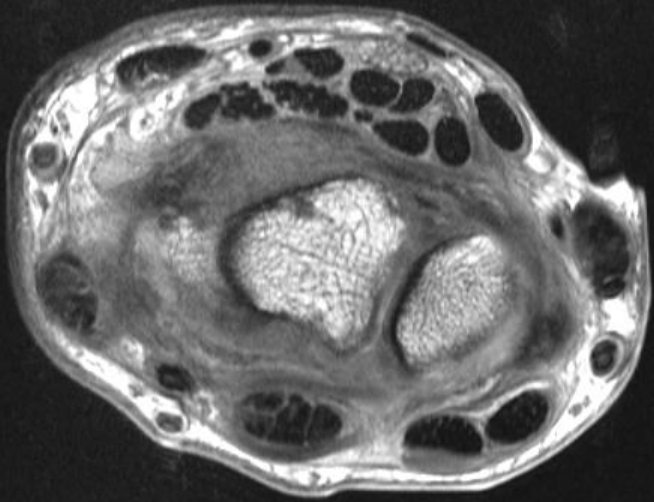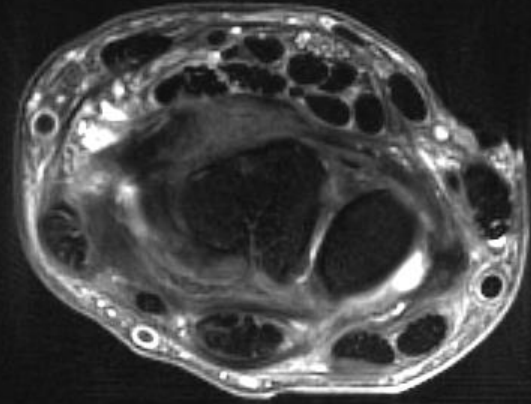
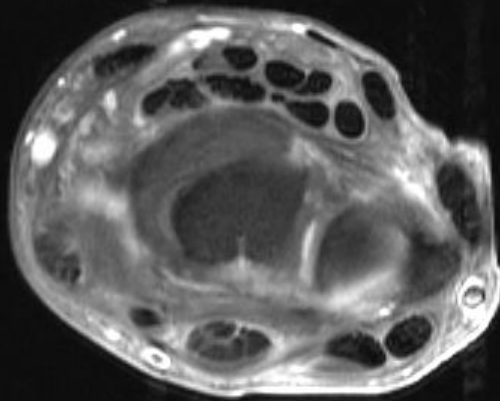


Page: 20 of 31



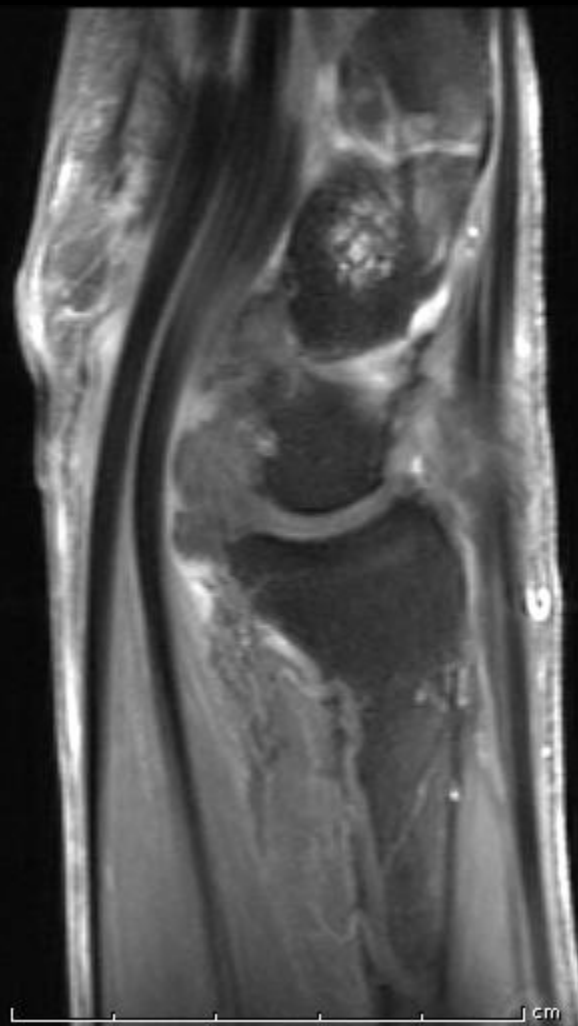
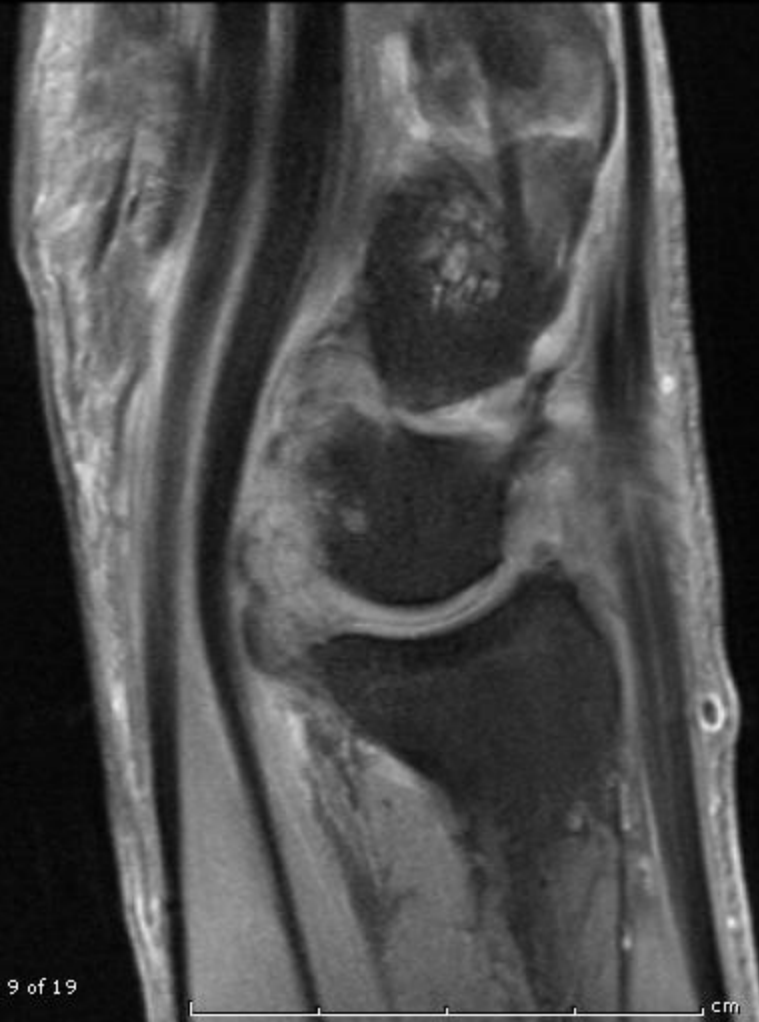
Compressed 7:1
IM: 20 SE: 4

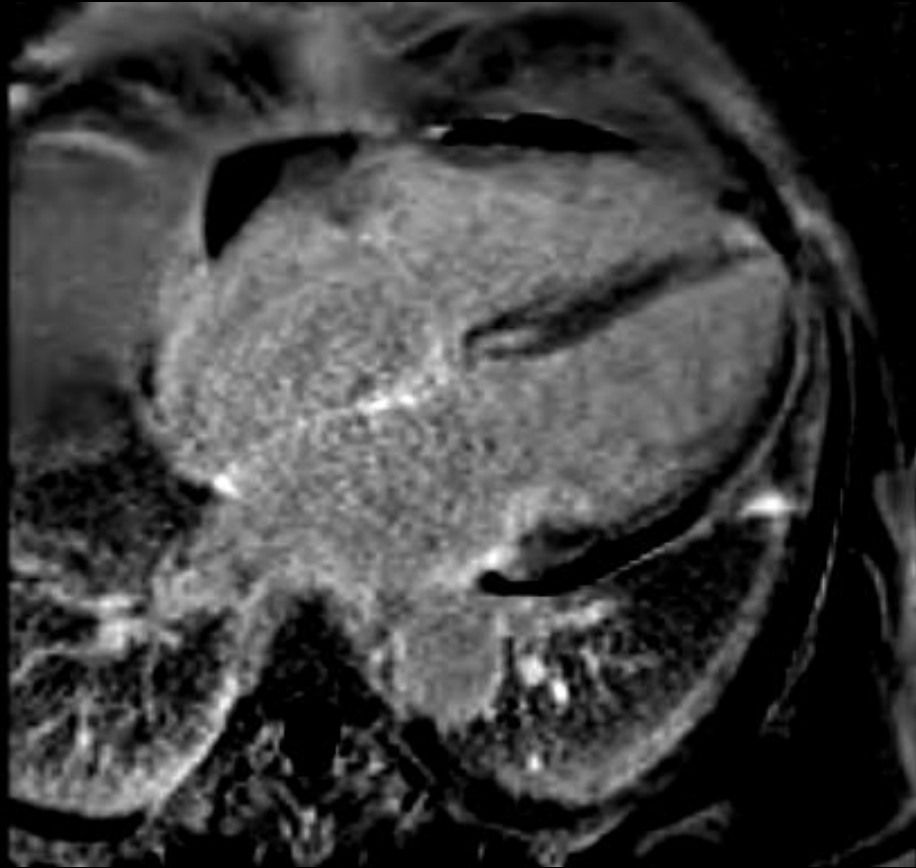


Page: 13 of 20

Compressed 7:1
IM: 13 SE: 10

RIGHT WRIST





Post contrast delayed enhancement four chamber view demonstrates patchy left ventricular myocardial enhancement, biatrial enlargement, and thickened endocardial with enhancement.

Amyloidosis